

# Patellofemoral Kinematics After Limited Resurfacing of the Trochlea

Matthew Provencher, MD  
Neil S. Ghodadra, MD  
Nikhil N. Verma, MD  
Brian J. Cole, MD, MBA  
Stephanie Zaire, BS  
Elizabeth Shewman, MS  
Bernard R. Bach, Jr, MD

**ABSTRACT:** Patellofemoral kinematics after a limited resurfacing of the trochlea was investigated. Patellofemoral contact pressure, area, and force were measured for intact state; after creation of a 20-mm full-thickness trochlear defect; and after trochlear resurfacing implant (Arthrosurface) in serial flexion positions (45°, 60°, 75°). In the defect state, edge loading and peak contact forces were highest at the periphery. The chondral defect increased peak contact force (13 to 18 N,  $P < .01$ ) and peak contact pressure (23 to 31 kg/cm<sup>2</sup>,  $P < .02$ ) compared with the intact state. Peak contact pressure and force were restored to 90% ( $P < .01$ ) and 88% ( $P < .01$ ). Implantation of the device restored contact area to 85% of the intact state. Limited resurfacing of the trochlea restores contact area, peak pressure, and peak force to the intact state. These findings highlight the potential clinical use of limited patellofemoral resurfacing in trochlear chondral defects.

[*J Knee Surg.* 2009;22:310-316.]

## INTRODUCTION

The treatment of patellofemoral arthritis remains a challenge due to its complex articulation, high pressures, and inherent difficulties in achieving a congruent resurfacing procedure. In particular, the treatment algorithm in young active patients with symptomatic patellofemoral chondrosis is multifaceted and has become a controver-

sial orthopedic topic. Identification of the optimal surgical treatment option involves various factors including patient age, physical loads, patient symptoms, response to conservative treatment, and defect size and location.<sup>13</sup> In young active individuals with focal chondral defects, mechanical fragmentation of the adjacent articular cartilage can lead to pain, locking, effusion, and synovitis within the knee joint.<sup>6,21,22,27</sup> Even with small trochlear defects, it has been shown that a 6-mm osteochondral defect in a goat model undergoes degenerative changes including collapse of surrounding subchondral bone and articular cartilage.<sup>21</sup>

Within the patellofemoral joint, studies have shown that successful treatment of focal trochlear lesions is limited secondary to high shear forces and contact pressure.<sup>29,30</sup> Garretson et al<sup>17</sup> reported, in a controlled laboratory study, that mean contact pressures within the patellofemoral joint during normal knee kinematics are highest at the central trochlea, which is a common finding in patients with symptomatic patellofemoral pain due to chondrosis. To date, many of the surgical treatments for patellofemoral arthritis have produced unsatisfactory results. Arthroscopic lavage and debridement provide temporizing effects without cartilage repair but do not retard progression of arthritis.<sup>4,18,20,21,24</sup> Traditional marrow stimulation techniques, including drilling, abrasion, and microfracture, have provided limited short-term relief when used for patellar or trochlear lesions.<sup>1,4,12,15</sup> Other grafting treatments, such as periosteal transplantation,<sup>11</sup> chondrocyte transplantation,<sup>9</sup> and autologous osteochondral grafting,<sup>8,19</sup> have allowed for limited short-term success with formation of some normal hyaline cartilage. However, these techniques are limited by the complex architecture of the patellofemoral joint which makes matching of donor and recipient sites difficult. Osteotomy has been used for unloading the patellofemoral joint and correcting instability or malalignment. However, clinical results are poor in patients with proximal, medial, or diffuse disease.<sup>16,32</sup> Knee arthroplasty for patients with isolated patellofemoral disease requires resurfacing of

*Dr Provencher is from the Division of Shoulder, Knee and Sports Surgery, Department of Orthopaedic Surgery, Naval Medical Center San Diego, San Diego, Calif; Dr Ghodadra and Ms Shewman are from Rush University Medical Center, and Drs Verma, Cole, and Bach are from Midwest Orthopedics at Rush, Chicago, Ill; and Ms Zaire is from George Washington University, Washington, DC.*

*Correspondence:* Matthew Provencher, MD, Division of Shoulder, Knee and Sports Surgery, Department of Orthopaedic Surgery, Naval Medical Center San Diego, 34800 Bob Wilson Dr, Ste 112, San Diego, CA 92134-1112.

potentially normal tibiofemoral surfaces and has inferior results, compared with joint replacement for more diffuse disease.<sup>31, 34</sup>

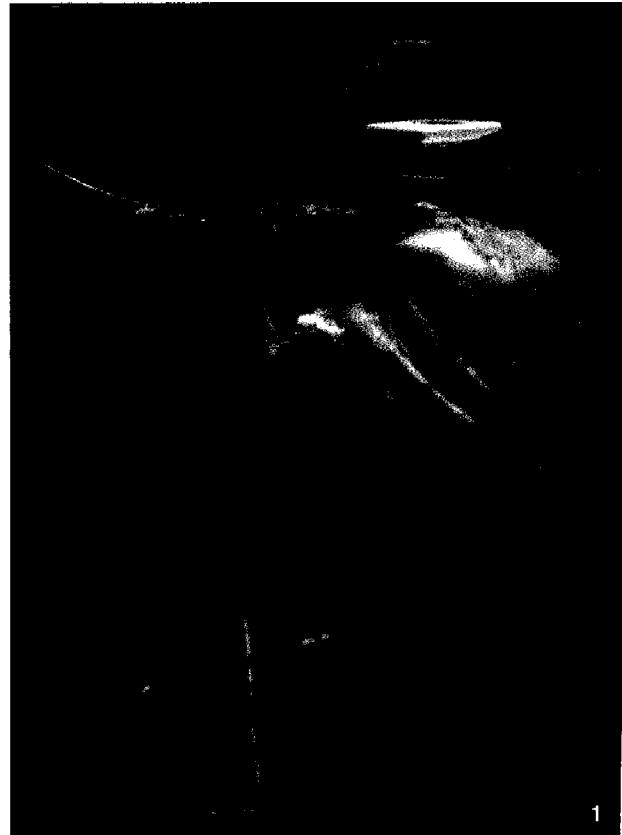
Patellofemoral arthroplasty potentially provides an alternative with clear advantages. Limited patellofemoral arthroplasty implants have been developed to preserve bone stock while reproducing the complex anatomy of the trochlear groove. The purpose of this study was to investigate patellofemoral kinematics after a limited resurfacing of the trochlea with an anatomic-specific implant to determine whether patellofemoral contact pressure characteristics could be normalized. Our hypothesis was that contact pressures following anatomic resurfacing will be normalized, compared with an untreated defect.

### MATERIALS AND METHODS

Eight fresh-frozen cadaveric knee specimens were evaluated in a custom patellofemoral testing apparatus that has been previously described.<sup>17</sup> Specimens were excluded if they contained any evidence of patellofemoral degenerative changes, a history of previous surgery, abnormal patellofemoral tracking or engagement, or any flexion or extension contractures (minimum flexion of 120°).

Each cadaveric knee was thawed overnight at room temperature, and the skin and subcutaneous tissues were completely removed. Tissues overlying the distal one-third of the femur were removed so that the knee could be clamped to the custom testing apparatus (Figure 1). Once clamped, a 5-cm lateral arthrotomy centered proximal to the patella was performed to gain access to the patellofemoral joint. The joint was inspected for any abnormality or evidence of degenerative disease.

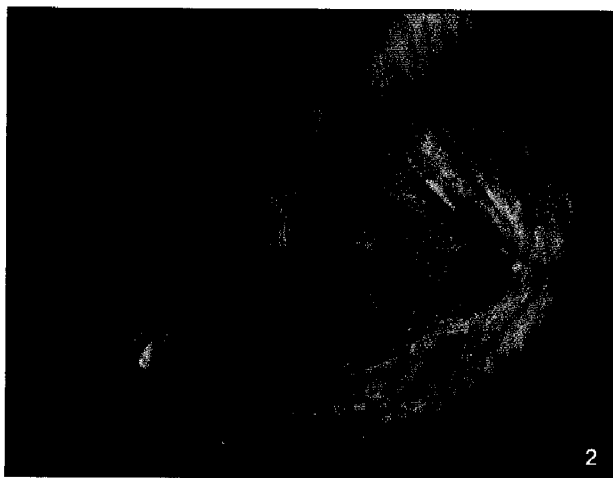
A real-time pressure sensor pad (K-scan 4000; Tekscan Inc, South Boston, Mass) with sensor dimensions of 28 mm×33 mm was centered superior to inferior over the lateral half of the trochlea. These sensors were engineered for the particular purpose of human joint studies in the knee and were 0.1-mm thick. The nonsensing edges of the sensor tape were trimmed, and cloth tape (3M, St. Paul, Minn) was used as reinforcement around the edges. The lateral sensor was centered over the lateral half of the trochlea and held in place with staples at the juxta-articular margin posteriorly and superiorly at both the medial and lateral condyles. The medial trochlea sensor pad was inserted through a small superior-medial arthrotomy 1 cm in length just posterior to the posterior edge of the vastus medialis and proximal to the patella to preserve the medial patellofemoral ligament. The sensor was affixed to the knee with juxta-articular staples in a similar fashion as the lateral pad. The pads were placed such that the sensor units were centered over the trochlea (measured superior to inferior and center point determined from superior aspect of the femoral notch to the superior



**Figure 1.** Cadaveric knee placed in custom patellofemoral testing apparatus, with sensors placed through lateral arthrotomy centered over the proximal patella.

articular margin of the trochlea). The pads were placed with apposition or slight overlap at the central trochlea while maintaining pad conformity and adherence to the trochlear surface (Figure 2).

The sensors were preconditioned and calibrated per the manufacturer's recommendations on a servo-hydraulic testing machine (Instron 8874; Instron, Norwood, Mass). First, the sensors were preconditioned 3 times, compressing them to a load 20% higher than expected maximum loads. Each sensor was then allowed to rest before undergoing a 2-point calibration (20% and 80% of expected loads). Individual sensor calibration values were calculated and input into data files prior to each test. Two Krackow stitches with #5 Ethibond sutures (Ethicon Inc, Somerville, NJ) were placed in the quadriceps tendon and attached with an S-shaped hook to a rope that ran over a pulley consistent with the quadriceps vector. The end of the rope was affixed to another hook, which allowed for loading and unloading of the patellar mechanism with weights. A model simulating non-weight bearing resisted extension of the knee was used as described by Skyhar et al.<sup>35</sup> Each knee specimen was loaded with a constant 89.1-N load, identical to the force used by Garretson et

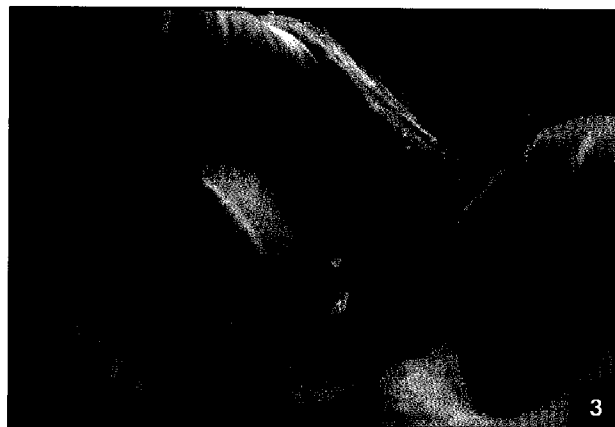

**Figure 2.** Setup of the sensor pads to the trochlear groove. One medial pad and one lateral pad were inserted through limited arthrotomies and stapled at the juxta-articular margins so they just apposed each other at the center point of the trochlea.

al<sup>17</sup> and similar to the 100 N force used by Simonian et al.<sup>33</sup> and Torzilli et al.<sup>37</sup> The testing sequence as outlined below was completed and then repeated at a higher load of 178.2 N, as described by Garretson et al.<sup>17</sup>

The patellofemoral contact area, peak contact pressure, and peak force were measured by the Tekscan device dynamically and statically at 45°, 60°, and 75° of knee flexion. These angles were chosen to represent the arc of motion, during which the patella maximally articulates with the trochlea. The flexion angles were measured with a calibrated goniometer, and each sensor pad measurement was taken with a 1-minute delay between subsequent measurements to allow for real-time sensor accommodation. The complete video can be viewed or analyzed on a frame by frame basis. Readings were taken for each specimen with 89.1 N and 178.2 N of force at 45°, 60°, and 75° of flexion. In our study, the first frame of each video was analyzed for total contact area, peak force, and peak contact pressure. Using a specialized tool, the program was able to electronically draw a polygon around central areas of pressure on each of the 2 sensor pads for a total of 2 polygons per video. Graphs of each value with respect to time were analyzed to ensure that the readings did not change during the 20 seconds of each video.

Three conditions were tested: intact specimen, after the creation of a 20-mm trochlear defect, and after limited trochlear resurfacing. After completion of the intact specimen loading cycle, the weights were removed and the Tekscan sensor pad was peeled back from the proximal stapled attachment (the distal staples were maintained to preserve the orientation of the sensor pads) to create a central trochlear defect. The location of the center of the trochlea was measured with a ruler and a circular symmetrical 20-mm defect was cre-



**Figure 3.** Trochlear chondral defect of 20 mm×20 mm created at center of trochlea.

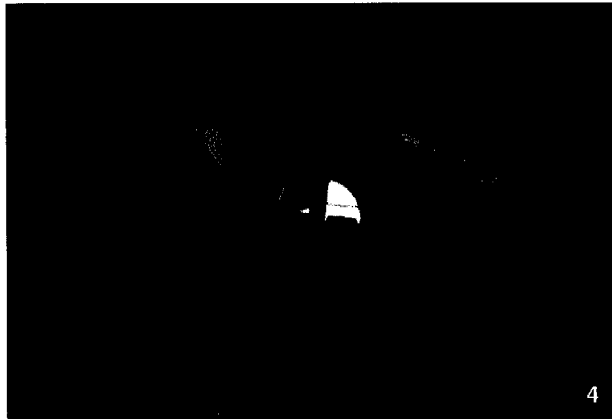ated with a curette down to the level of the subchondral bone (Figure 3). The defect was created to mimic grade 4 Outerbridge changes. The Tekscan sensors were then restapled to their proximal attachments. Care was taken to maintain the position and shape of the sensor and to prevent crinkling of the sensor pad. Tekscan measurements were then performed with serial and dynamic measurements at the varying flexion angles and loads as described above.

After completion of the defect data collection, the Tekscan sensors were peeled back as described above. The defect size from subchondral bone to articular surface was measured at the 12-o'clock, 3-o'clock, 6-o'clock, and 9-o'clock positions. The Arthrosurface patellar implant (HemiCap, Franklin, Mass) was then placed into the defect after it was reamed to the appropriate depth, measured, and then trialed. The implants are 20 mm in diameter and are available in 0.5-mm depth increments, which varies in both the medial-lateral and superior-inferior directions to allow for a customizable fit into the 20-mm defect. The final implant was chosen based on the best feel and appearance of a smooth and congruent transition between the intact trochlear chondral surface and the implant (Figure 4). In all cases, we attempted to place the implant flush with the articular margin, and if necessary, slightly recessed. No implant was placed proud to the surrounding articular margin. The Tekscan sensors were restapled into their exact previous position, and Tekscan measurements were performed at the aforementioned angles and weights.

## RESULTS

### *Contact Area at 45°, 60°, and 75° of Knee Flexion*

The contact areas recorded by the Tekscan sensors for the intact, defect, and limited trochlear resurfacing arthroplasty state under 20 lbs and 40 lbs of load are summarized in Figure 5. In the intact specimens, contact area was highest



**Figure 4.** Implantation of Arthrosurface patellofemoral arthroplasty device at site of trochlear defect. Care was taken to implant device of correct size and to leave the implant flush with the surrounding articular cartilage.

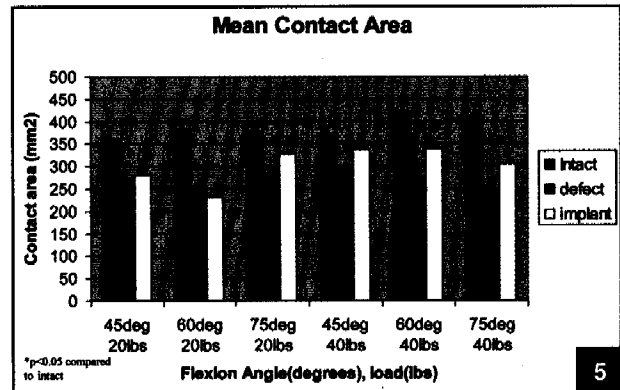
at 60° of flexion at 20 lbs and 40 lbs load. In the defect state, contact area decreased to a mean of 67% of the intact state at 60° of flexion. After implantation of the limited trochlear resurfacing device, there was a statistically significant ( $P < .04$ ) increase in contact area at all tested flexion angles, with 45° of knee flexion showing the highest normalization of area. With limited resurfacing arthroplasty, there was significant normalization of contact area to 81% of the intact state ( $P < .05$ ). With creation of the defect state, the contact area pattern on the Tekscan sensor changed from a uniform contact area to a concentration of contact and pressure along the rim of the defect (Figure 6). After placement of the implant, the contact area distribution was further seen to normalize to the uniform pattern of the intact state.

**Peak Contact Pressure**

In the evaluation of peak contact pressures in the intact patellofemoral joint, values trended toward an increase with increasing knee flexion (Figure 7). The mean peak pressures in intact specimens at 40 lbs of force were 22 kg/cm<sup>2</sup>, 21 kg/cm<sup>2</sup>, and 23 kg/cm<sup>2</sup> at 45°, 60°, and 75° flexion, respectively. After creation of the trochlear defect, mean peak pressures significantly ( $P < .04$ ) increased to 24 kg/cm<sup>2</sup> and 31 kg/cm<sup>2</sup> at 60° and 75° flexion, respectively. After implantation of the Arthrosurface trochlear resurfacing implant, mean peak pressure decreased to 20 kg/cm<sup>2</sup>, 18 kg/cm<sup>2</sup>, and 22 kg/cm<sup>2</sup> at 45°, 60°, and 75° knee flexion, respectively. There was no significant difference in peak pressure between intact and implant state for any knee angle at both 20 and 40 lbs of force.

**Peak Force**

At both 20 lbs and 40 lbs of force, there was no significant difference in peak force measurements of intact knees at 45°, 60°, and 75° of knee flexion (Figure 8). At




**Figure 5.** Graph of mean contact area (mm<sup>2</sup>) at 20 lbs and 40 lbs force for intact, defect, and implant specimens at 45°, 60°, and 75° flexion.

40 lbs of force, peak force values in knees in the trochlear defect state were significantly higher than intact specimens at 60° and 75° of flexion ( $P < .03$ ). At all knee flexion angles, peak force was noted to be highest at the periphery of the trochlear defect. With implantation of the limited trochlear resurfacing device, peak force normalized to 92% of intact specimens. At 45°, 60°, and 75° of knee flexion, there was no significant difference in peak force between the intact and implant state.

**DISCUSSION**

The principal findings of this study suggest that limited resurfacing of the trochlea restores contact pressure, contact area, and peak force to the intact state. These findings highlight the potential clinical use of limited patellofemoral resurfacing in trochlear chondral defects based on normalization of biomechanical properties. The peak pressure and force values are lower in the implant state than the defect state throughout all range of motion and weights, suggesting that the distributed force across the junction of the implant-articular cartilage interface decreases significantly with appropriate trochlear resurfacing. This study also demonstrated that peak contact pressures were greater with higher degrees of knee flexion. This finding is in agreement with a study by Frankel<sup>14</sup> in which he noted that with increased knee flexion, tension across the patella is converted to compression through the articular surface. Peak pressure was demonstrated to be highest at 75° flexion, which correlates to study findings by Garretson et al.<sup>17</sup>

The dynamic evaluation in this study provided interesting findings with regard to peak contact force and pressure after creation of a limited defect. In the defect state, peak pressures and force were significantly higher at the periphery of the trochlear defect leading to edge loading. This finding could have important clinical impli-



**Figure 6.** Example of the contact pressure map at 75° for the intact state (A), the defect state (B), after Arthrosurface implant (C).

cations of identifying the etiology of pain and increased wear in the patellofemoral joint. With proper implantation of the limited trochlear resurfacing device at the site of the trochlear defect, peak pressures and force is normalized leading to decreased edge loading. This normalization of contact area, pressure, and force may translate into decreased clinical symptoms and delayed progression of chondral disease.

To our knowledge, there are no reports in the literature on the long-term results of limited trochlear resurfacing for isolated trochlear defects. Dr. Miniaci has performed limited trochlear resurfacing in over 50% of patients indicated for patellofemoral arthroplasty and good outcomes at short-term follow-up (A. Miniaci, personal communication, March 2008). The reported success rates of patellofemoral arthroplasty devices have demonstrated considerable variability. One major factor affecting previous trochlear implant outcome is prosthetic design. Geometric flaws in trochlear design have led to a high tendency for patellofemoral complications including pain, snapping, and subluxation, and to a greater emphasis for a geometric trochlear implant design.<sup>5,10,30</sup> The deep constraining trochlear groove of first generation Richards I and II implants (Smith & Nephew, Memphis, Tenn) led to increased

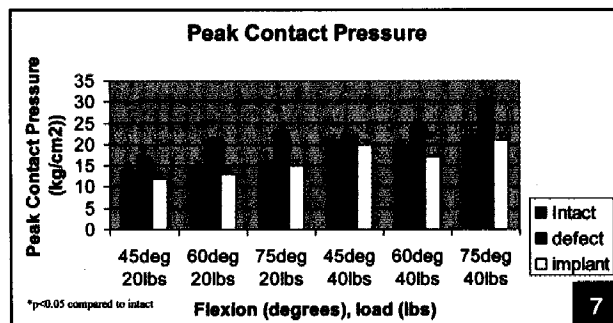
rates of patellar maltracking and catching of the patellar component on the trochlear edges. In an 11-year follow-up study by de Winter et al,<sup>10</sup> 7 of 26 Richards II patellofemoral arthroplasties required revision surgery for patellar maltracking and implant malalignment. Kooijman et al<sup>23</sup> reported an 86% success rate in a series of 45 patients with 18% of patients requiring secondary soft-tissue surgery for catching and maltracking symptoms.

In a series of 62 patients treated with the Lubinus patellofemoral arthroplasty, Tauro et al<sup>36</sup> showed 55% unsatisfactory results with 28% revision for maltracking and catching in the first 30° of flexion. The large radius of curvature and limited proximal extension of the Lubinus patellofemoral implant predispose to implant failure and unsatisfactory results.<sup>26</sup> Board et al<sup>7</sup> reported a 53% unsatisfactory rate in a series of 17 patellofemoral arthroplasties, with patellar clicking and subluxation in 18% of knees, extension block in 18% in knees, and progressive tibiofemoral arthrosis in 12% of knees. Other prosthetic designs have demonstrated similar variability in outcomes and implant survival.<sup>2,28</sup> Limited trochlear resurfacing circumvents these design issues while allowing for a more anatomic restoration of trochlear defects.

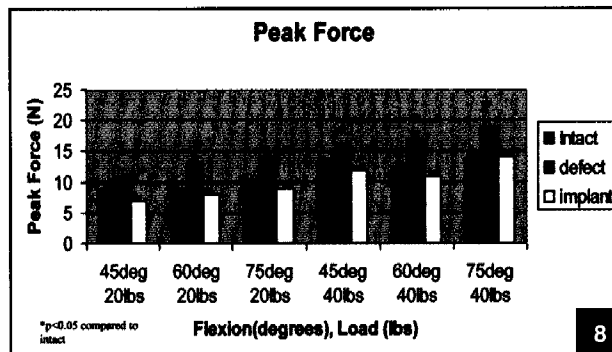
The critical elements of trochlear implant design include matching sagittal radius of curvature, proximal extension of the anterior flange, the medial-lateral distance of the implants, and the level of constraint.<sup>25</sup> The limited trochlear resurfacing device tested here does not encompass the entire trochlea but rather serves to anatomically restore the trochlear surface given a clinically symptomatic defect less than 20 mm. With its anatomic design, this device potentially circumvents previous sources of trochlear implant failure including nonanatomic sagittal radius of curvature, a large level of constraint, and proximal extension of the anterior flange.

#### **LIMITATIONS**

There are several limitations of this study due to both the Tekscan and the cadaveric model: the entire quadriceps was loaded rather than its individual components; the rela-



**Figure 7.** Graph of mean peak contact pressures (kg/cm<sup>2</sup>) at 20 lbs and 40 lbs force for intact, defect, and implant specimens at 45°, 60°, and 75° flexion.



**Figure 8.** Graph of mean peak force (Newtons) at 20 lbs and 40 lbs force for intact, defect, and implant specimens at 45°, 60°, and 75° flexion.

tive forces of the hamstrings were not taken into account; and knee motion occurred through passive motion rather than active forces.<sup>3,17</sup> Further, the nonweightbearing resisted extension model used in this study does not simulate active physiologic loading experienced in the knee.<sup>35</sup> The loads used in this study more closely approximate those applied in nonweightbearing exercise. However, due to the complex motion and interactions of the knee muscles, we do not believe that any cadaver model could successfully simulate the weightbearing model. Our model allows us to reproducibly load the quadriceps mechanism in line with the femur with variable weights. Regarding the Tekscan sensors, some limitations should be considered. Sensor pad stability and conformity were maintained with staples attaching the pads to the femur as suggested by Beck et al.<sup>3</sup> Although we were able to maintain good sensor pad stability and conformity, we could not avoid a small amount of crinkling in the sensors. Small amounts of data points were dropped during dynamic and static testing secondary to crinkling. Because the sensors had to be overlapped to record data from the central trochlea, recording error required interpretation and correction with each sampling. We also chose to make a central trochlea lesion for standardization between specimens, and this may not be what is truly encountered clinically.

Although the study supports initial normalization of contact area, pressure and force, it is unknown how these changes may affect further disease progression. Second, due to the limited size of the implant, an implant-cartilage interface exists. It should be noted that the stiffness of any metal implant is significantly higher than normal articular cartilage, and the effect of this abrupt change at the implant-cartilage interface is unknown.

**CONCLUSION**

Although several implants are available to treat patellofemoral chondrosis, there is no current available implant that restores articular surface congruity while main-

taining normal contact pressures throughout knee range of motion. The results of this study suggest that the limited trochlear resurfacing provides a unique and favorable alternative to prior implant designs by providing anatomic reapproximation of the patellofemoral surface and knee contact pressures. Although a challenging problem, limited resurfacing of the trochlea restores peak pressure, contact area, and peak force to the intact state. These findings highlight the potential clinical use of limited patellofemoral resurfacing in trochlear chondral defects based on normalization of biomechanical properties, although the effect on patient symptoms and subsequent disease progression remains unknown. Additional clinical studies are necessary to assess the long-term viability and outcomes of limited trochlear resurfacing implants.

**REFERENCES**

1. Akizuki S, Yasukawa Y, Takizawa T. Does arthroscopic abrasion arthroplasty promote cartilage regeneration in osteoarthritic knees with eburnation? A prospective study of high tibial osteotomy with abrasion arthroplasty versus high tibial osteotomy alone. *Arthroscopy*. 1997;13:9-17.
2. Argenson JN, Flecher X, Parratte S, Aubaniac JM. Patellofemoral arthroplasty: An update. *Clin Orthop*. 2005;440:50-53.
3. Beck PR, Thomas AL, Farr J, Lewis PB, Cole BJ. Trochlear contact pressures after anteromedialization of the tibial tubercle. *Am J Sports Med*. 2005;33:1710-1715.
4. Bert JM, Maschka K. The arthroscopic treatment of unicompartamental gonarthrosis: A five-year follow-up study of abrasion arthroplasty plus arthroscopic debridement and arthroscopic debridement alone. *Arthroscopy*. 1989;5:25-32.
5. Blazina ME, Fox JM, Del Pizzo W, Broukhim B, Ivey FM. Patellofemoral replacement. *Clin Orthop*. 1979;(144):98-102.
6. Blevins FT, Steadman JR, Rodrigo JJ, Silliman J. Treatment of articular cartilage defects in athletes: An analysis of functional outcome and lesion appearance. *Orthopedics*. 1998;21:761-768.
7. Board TN, Mahmood A, Ryan WG, Banks AJ. The Lubinus patellofemoral arthroplasty: A series of 17 cases. *Arch*

- Orthop Trauma Surg.* 2004;124:285-287.
8. Bobic V. Arthroscopic osteochondral autograft transplantation in anterior cruciate ligament reconstruction: A preliminary clinical study. *Knee Surg Sports Traumatol Arthrosc.* 1996;3:262-264.
  9. Brittberg M, Lindahl A, Nilsson A, Ohlsson C, Isaksson O, Peterson L. Treatment of deep cartilage defects in the knee with autologous chondrocyte transplantation. *N Engl J Med.* 1994;331:889-895.
  10. de Winter WE, Feith R, van Loon CJ. The Richards type II patellofemoral arthroplasty: 26 cases followed for 1-20 years. *Acta Orthop Scand.* 2001;72:487-490.
  11. Dzioba RB. The classification and treatment of acute articular cartilage lesions. *Arthroscopy.* 1988;4:72-80.
  12. Ficat RP, Ficat C, Gedeon P, Toussaint JB. Spongialization: A new treatment for diseased patellae. *Clin Orthop.* 1979;(144):74-83.
  13. Fox JA, Cole BJ. Management of articular cartilage lesions. In: Garrick JG, ed. *Orthopedic Knowledge Update: Sports Medicine.* Vol 3. Rosemont, IL: American Academy of Orthopedic Surgeons; 2004:223-232.
  14. Frankel VH. Biomechanics of the knee. *Orthop Clin North Am.* 1971;2:175-190.
  15. Friedman MJ, Berasi CC, Fox JM, Del Pizzo W, Snyder SJ, Ferkel RD. Preliminary results with abrasion arthroplasty in the osteoarthritic knee. *Clin Orthop.* 1984;(182):200-205.
  16. Fulkerson JP. Alternatives to patellofemoral arthroplasty. *Clin Orthop.* 2005;(436):76-80.
  17. Garretson RB III, Katolik LI, Verma N, Beck PR, Bach BR, Cole BJ. Contact pressure at osteochondral donor sites in the patellofemoral joint. *Am J Sports Med.* 2004;32:967-974.
  18. Gibson JN, White MD, Chapman VM, Strachan RK. Arthroscopic lavage and debridement for osteoarthritis of the knee. *J Bone Joint Surg Br.* 1992;74:534-537.
  19. Hangody L, Kish G, Karpai Z, Udvarhelyi I, Szigeti I, Bely M. Mosaicplasty for the treatment of articular cartilage defects: Application in clinical practice. *Orthopedics.* 1998;21:751-756.
  20. Hubbard MJ. Articular debridement versus washout for degeneration of the medial femoral condyle. A five-year study. *J Bone Joint Surg Br.* 1996;78:217-219.
  21. Jackson DW, Lalor PA, Aberman HM, Simon TM. Spontaneous repair of full-thickness defects of articular cartilage in a goat model. A preliminary study. *J Bone Joint Surg Am.* 2001;83:53-64.
  22. Johnson-Nurse C, Dandy DJ. Fracture-separation of articular cartilage in the adult knee. *J Bone Joint Surg Br.* 1985;67:42-43.
  23. Kooijman HJ, Driessen AP, van Horn JR. Long-term results of patellofemoral arthroplasty. A report of 56 arthroplasties with 17 years of follow-up. *J Bone Joint Surg Br.* 2003;85:836-840.
  24. Livesley PJ, Doherty M, Needoff M, Moulton A. Arthroscopic lavage of osteoarthritic knees. *J Bone Joint Surg Br.* 1991;73:922-926.
  25. Lonner JH. Patellofemoral arthroplasty. *J Am Acad Orthop Surg.* 2007;15:495-506.
  26. Lonner JH. Patellofemoral arthroplasty: Pros, cons, and design considerations. *Clin Orthop.* 2004;(428):158-165.
  27. Matthewson MH, Dandy DJ. Osteochondral fractures of the lateral femoral condyle: A result of indirect violence to the knee. *J Bone Joint Surg Br.* 1978;60:199-202.
  28. Merchant AC. Early results with a total patellofemoral joint replacement arthroplasty prosthesis. *J Arthroplasty.* 2004;19:829-836.
  29. Minas T. Autologous chondrocyte implantation for focal chondral defects of the knee. *Clin Orthop.* 2001;(391)(suppl):S349-S361.
  30. Minas T, Chiu R. Autologous chondrocyte implantation. *Am J Knee Surg.* 2000;13:41-50.
  31. Mont MA, Haas S, Mullick T, Hungerford DS. Total knee arthroplasty for patellofemoral arthritis. *J Bone Joint Surg Am.* 2002;84:1977-1981.
  32. Pidoriario AJ, Weinstein RN, Buuck DA, Fulkerson JP. Correlation of patellar articular lesions with results from anteromedial tibial tubercle transfer. *Am J Sports Med.* 1997;25:533-537.
  33. Simonian PT, Sussmann PS, Wickiewicz TL, Paletta GA, Warren RF. Contact pressures at osteochondral donor sites in the knee. *Am J Sports Med.* 1998;26:491-494.
  34. Sisto DJ, Sarin VK. Custom patellofemoral arthroplasty of the knee. *J Bone Joint Surg Am.* 2006;88:1475-1480.
  35. Skyhar MJ, Warren RF, Ortiz GJ, Schwartz E, Otis JC. The effects of sectioning of the posterior cruciate ligament and the posterolateral complex on the articular contact pressures within the knee. *J Bone Joint Surg Am.* 1993;75:694-699.
  36. Tauro B, Ackroyd CE, Newman JH, Shah NA. The Lubinus patellofemoral arthroplasty. A five- to ten-year prospective study. *J Bone Joint Surg Br.* 2001;83:696-701.
  37. Torzilli PA, Deng X, Warren RF. The effect of joint-compressive load and quadriceps muscle force on knee motion in the intact and anterior cruciate ligament-sectioned knee. *Am J Sports Med.* 1994;22:105-112.