

# Endoscopic Single-Incision Anterior Cruciate Ligament Reconstruction Using Patellar Tendon Autograft

## *Surgical Technique*

Gregory T. Hardin, MD  
Bernard R. Bach, Jr, MD  
Charles A. Bush-Joseph, MD  
Jack Farr, MD

### INTRODUCTION

Anterior cruciate ligament (ACL) reconstruction has undergone numerous advances over the past two decades. In the early 1970s, Jones<sup>21</sup> popularized open arthrotomy reconstruction using the central one third of the patellar ligament. The 1980s witnessed arthroscopic-assisted techniques that obviated the use of an arthrotomy.<sup>3,19,37</sup> Endoscopic ACL reconstruction using a single anterior incision is an attractive technique modification that is currently being investigated as a potential advance over arthroscopic-assisted techniques.<sup>31,33,35</sup>

Single-incision endoscopic ACL reconstruction has the advantages of arthroscopic-assisted ACL reconstruction and offers several advantages over mini-arthrotomy techniques.\* These include improved visualization for graft placement and isometry, exposure provided by fluid distention thus avoiding cartilage desiccation, possibly less thigh girth atrophy, avoidance of an arthrotomy-induced loss of proprioception, improved cosmesis, decreased postoperative pain, and simpler wound care. Reduced postoperative morbidity will allow the future single-incision technique to be performed routinely on an outpatient basis. This may help reduce costs and improve health-care use.

Despite the many advantages associated with endoscopic ACL reconstruction, it is a technically demanding procedure with many potential pitfalls.<sup>27</sup>

This article describes the surgical technique and pitfalls of single-incision endoscopic ACL reconstruction using patellar tendon autograft.

\*2, 3, 5, 8-11, 14, 15, 18-20, 24, 28-43.

This article originally appeared in *The American Journal of Knee Surgery*. 1992;5:144-155.

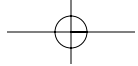
### SURGICAL TECHNIQUE

#### *Diagnostic Arthroscopy*

Surgery is performed under general or regional anesthesia. An examination under anesthesia of the affected and unaffected knees is performed and the Lachman, pivot shift, and anterior drawer test results are noted. A tourniquet is placed high on the thigh. A leg holder or lateral thigh post must allow flexion of the knee past 120° to allow for femoral tunnel placement.

When the diagnostic arthroscopy portion is performed first, a routine superomedial cannula pump or gravity inflow can be used. The anterolateral portal should be placed slightly more medial than for routine arthroscopy to allow improved visualization of the over-the-top position, and should be selected with a spinal needle to allow optimal placement of instruments. An outflow is not necessary as there is generally plenty of fluid egress from the various portals and via suction used for motorized shavers and burrs. This can be important because decreased fluid distention helps minimize the blood oozing from the cancellous bone following notchplasty. Diagnostic arthroscopy is performed in a standard fashion.

The patellar tendon can be harvested prior to performing the diagnostic arthroscopy if the surgeon is convinced there will not be any articular cartilage pathology that would preclude the preoperative plan of ACL reconstruction. This results in less fluid extravasation into the subcutaneous tissue. One or two of the arthroscopy portals can then be placed directly through the capsule of the retracted anterior approach rather than through separate skin incisions. Once the graft is harvested, the patellar tendon defect is not immediately closed to allow fat pad protrusion, improving intercondylar notch visualization.



### ***Intercondylar Notch Preparation***

The intercondylar notch is assessed for notch architecture, stenosis, and intercondylar osteophytes. Remnant ACL tissue is debrided with a motorized shaver to allow exposure of the intercondylar eminence (Figure 1). On the femoral side, soft tissue is debrided completely back to the over-the-top region to allow accurate assessment of this landmark; much of this tissue may be reflected with an arthroscopic osteotome. The over-the-top position must be clearly visualized and may be confirmed with an arthroscopic probe.

The notchplasty is performed with superior and lateral expansion to improve visualization posteriorly and to prevent subsequent graft impingement in full extension (Figure 2). Several instruments can be used to perform this part of the procedure including shavers, burrs, curettes, and osteotomes. This allows for the removal of approximately 4 mm of bone at the notch entrance. Minimal bone is debrided at the femoral anatomic attachment site near the over-the-top region.<sup>27,32</sup> One must avoid misinterpreting a vertical ridge that occurs approximately two thirds of the way posteriorly as the isometric femoral attachment site.

The notchplasty should be large enough to view the intercondylar wall via the anterolateral portal. The size and shape of the notchplasty will be fine-tuned after the femoral drill hole has been made for impingement, but should approximate a "normal" arched notch.<sup>1,17,22</sup>

### ***Graft Harvesting***

An 8-cm longitudinal skin incision is made extending from just medial to the midline of the inferior pole of the patella distally to 2 cm below and medial to the tibial tubercle (Figure 3). Length can be minimized by appropriate undermining and sequential retraction proximally and distally during graft harvest. The graft may be procured with the tourniquet deflated.

We routinely expose the medial and lateral edges of the tendon and measure and record its width, leaving 20 mm of tendon distally. A scalpel is used to outline the middle third of the patellar tendon including 25-mm bone blocks at each end. An oscillating saw directed 45° to the sagittal plane is used in preference to an osteotome to create a triangular profile tibial bone plug and a trapezoidal profile patellar bone plug.

Grafts are lifted from their bone beds with a curved osteotome. The residual fat pad and synovial tissue are directed free from the patellar tendon graft. The bone blocks at each end are prepared removing sharp edges and contouring them to fit through a 10-mm sizing tube. Three 0.062-mm drill holes are made in the shorter bone plug in a transverse orientation parallel to the cortical edge. This allows placement of no. 1 braided polyester sutures through each hole using a suture passer (Acuflex Microsurgical Inc, Mansfield, Mass).

The tendon-osseous interface is demarcated with a sterile marking pen on the cancellous side (Figure 4). During placement of the longer bone-plug in the femoral tunnel, accurate assessment of complete graft seating to the bone-tendon tunnel junction is confirmed by observing this mark. Excess bone from the bone-plug trimmings can be used for grafting of the patellar bone defect at surgical closure.<sup>7</sup>

After preparation, the graft should be placed in a moist sponge in a basin, and all operative personnel should be informed so that it is not inadvertently passed off the back table. Do not immerse the graft in saline as it will become markedly edematous.

### ***Tibial Tunnel***

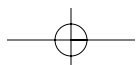
The medial proximal tibial metaphysis is exposed, taking care to avoid injury to the remaining medial third of the patellar tendon, superficial medial collateral ligament, or pes anserine tendon. The extra-articular entry site for the tibial drill is slightly more proximal (30 mm below the joint line) than traditional arthroscopic-assisted ACL reconstruction (Figure 5). This places the tibial tunnel slightly more horizontal than in previously described techniques.<sup>3</sup>

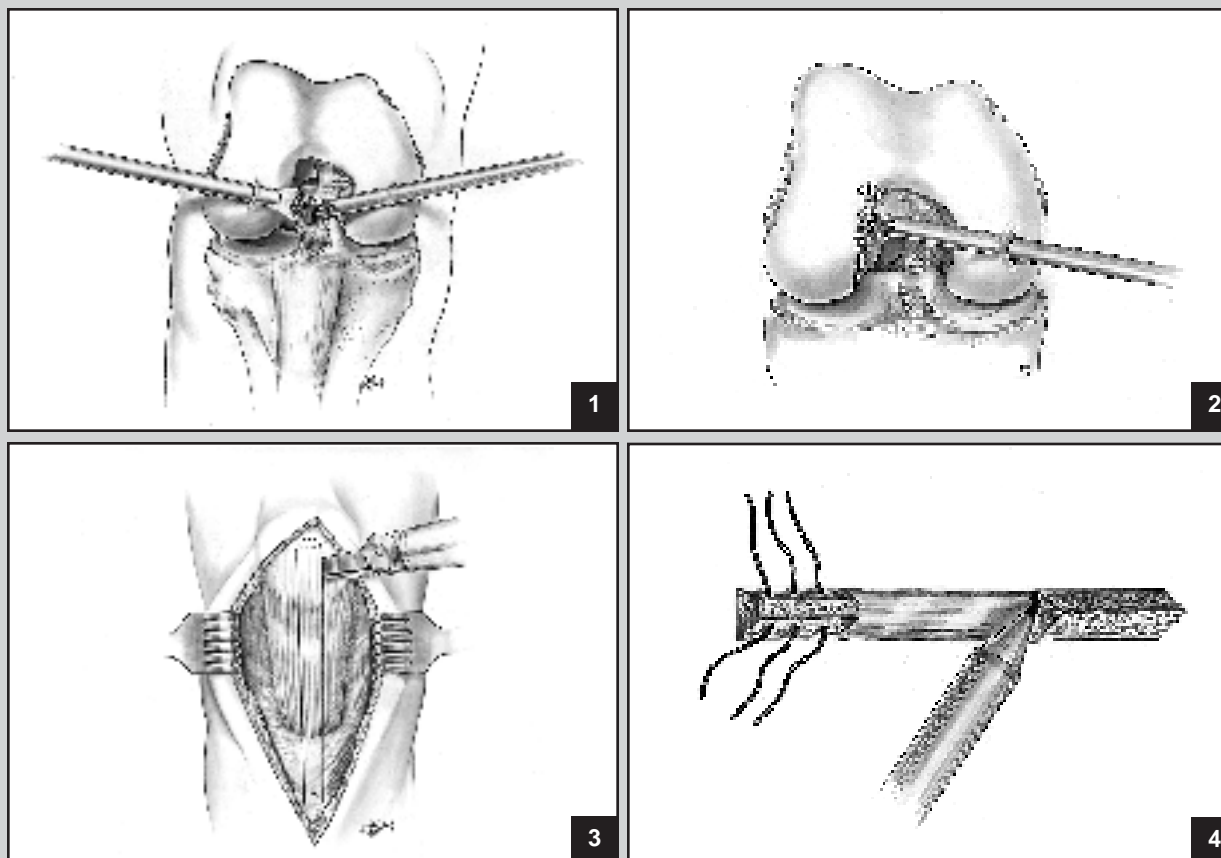
The arthroscope is placed in the anterolateral portal viewing anteromedially toward the tibial eminence. A tibial drill guide is placed either through the anteromedial portal or through the midpatellar rent and seated 5 mm lateral to the medial tibial spine slightly more posterior than the classic Clancy tibial position.<sup>22,25,27,32</sup> The tibial guide wire tip is placed midway in the sagittal plane (10-12 mm) between the posterior cruciate ligament (PCL) and the posterior edge of the anterior horn of the medial meniscus so that it is posterior to the anterior intercondylar outlet with the knee in extension.<sup>6</sup>

The tibial guide pin is overdrilled with an 11-mm cannulated reamer for the tibial tunnel (1 mm larger than the graft size) to allow greater ease of positioning the subsequent calibrated free guide pin for the femoral site. Following reaming, the intra-articular entrance is smoothed to prevent graft abrasion posteriorly and posterolaterally with a motorized shaver and an arthroscopic rasp (Figures 6 and 7). After occluding the tunnel distally with a plug (Concept Inc, Largo, Fla), the shaver is placed through the anteromedial portal to smooth the tunnel entrance and debride tissues that may contribute to fibroproliferative scar nodules.

### ***Isometry***

The femoral attachment site is identified with a sharp-tipped calibrated guide wire or pilot pin placed retrograde through the tibial tunnel. This is placed at the intersection of the lateral wall and the roof approximately 6-7 mm anterior to the over-the-top position at the 11:15 o'clock

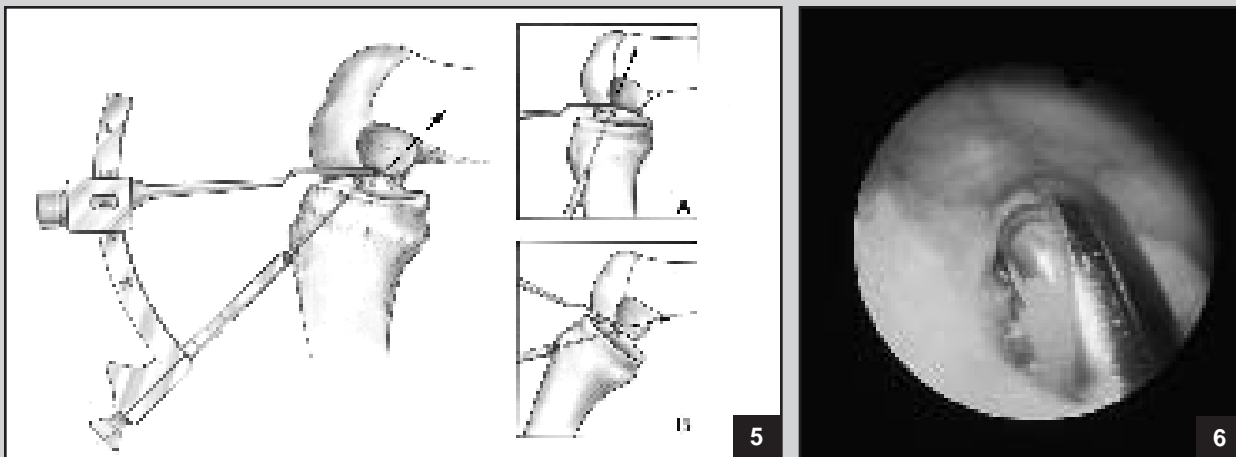




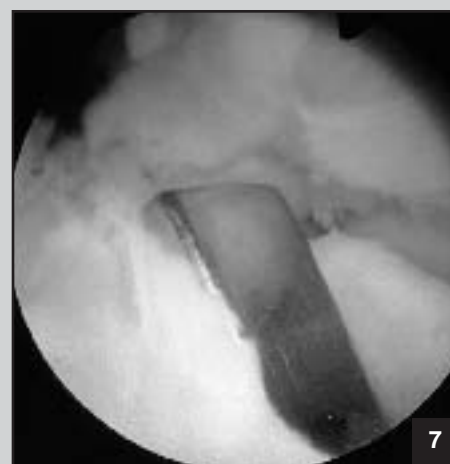
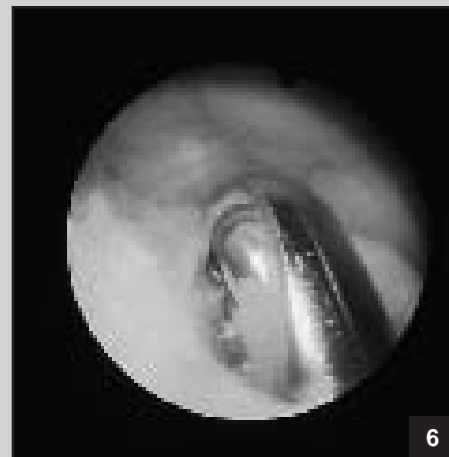**Figure 1.** Intra-articular debridement of remnant ACL tissue is performed with the arthroscope placed in the inferolateral portal. Attention is directed to debriding tissue on the insertion site as well as along the intercondylar wall. **Figure 2.** Notchplasty is performed with a 5- to 6-mm round motorized abrader to expand the wall to minimize graft abrasion postoperatively and to allow arthroscopic visualization of the “over-the-top” region. **Figure 3.** The middle third of the patellar tendon is harvested. A construct length of 90-100 mm usually is obtained. The patellar bone plug should be fashioned in a trapezoidal profile to minimize the depth of the cut on the patella. On the tibial tubercle site, the profile cut is triangular in shape. The patellar tendon may be harvested prior to arthroscopic placement if one has documented a pivot shift phenomenon and if one is convinced that there is not sufficient articular injury to preclude ACL reconstruction. **Figure 4.** The tendo-osseous junction is marked with a sterile marking pen to provide visual demarcation of this interval. This helps the surgeon judge the depth of graft placement on the femoral side. The shorter bone plug is prepared for placement on the tibial side to minimize the chance of construct tunnel mismatch. Three 0.062 K-wire drill holes are placed parallel and immediately deep to the cortical surface of the graft. A suture passer will facilitate passage of no. 1 braided polyester sutures.

position on the right knee or at the 12:45 o'clock position on the left knee. A mark can be made with a small curved curette or small motorized round burr. The Isotac (Acufex Microsurgical Inc) is preassembled with a nonabsorbable suture, passed retrograde through the tibial tunnel (with its associated cannulated screwdriver) and is secured into the hole previously created by the Kirschner wire. Care must be taken to completely seat the Isotac to a level flush with the intercondylar notch to allow accurate isometry assessment.<sup>13</sup> If the eyelet of the Isotac is left prominent, it will reflect an isometric reading at the eyelet rather than at the drill hole.

The Isotac suture is passed through the tibial centering plug. The strain gauge (Graf-Clancy; Acufex Microsurgical Inc) is secured and seated into the tibial metaphyseal hole making certain that the knee is not translated anteriorly.<sup>12</sup> The knee is extended from 90° to 0° noting the displacement on the strain gauge. If the displacement exceeds 2-3 mm, the joint should be inspected arthroscopically, and the selected femoral site should be reevaluated and assessed for soft-tissue or bony impingement, which may contribute to an abnormal measurement. Sutures should not impinge on the tibial tunnel. Also, because tibial rotation can increase anterior tibial



**Figure 5.** The tibial entrance site on the flare of the medial tibial metaphysis is slightly more proximal and horizontal than our previous technique description. The tibial pin intra-articular entrance site should be midway between the posterior edge of the anterior horn of the medial meniscus and the PCL. In extension, this pin should be slightly posterior to the notch outlet. This schematic diagram demonstrates the importance of knee flexion position and orientation of the tibial pin. If the tibial tunnel is too steep, then the femoral tunnel placement may be made too anteriorly with the knee flexed at 90°. A steep tibial tunnel may necessitate less knee flexion at the risk of posterior cortex violation. Similarly, if an appropriate tibial tunnel angle is selected (45°-50°) but the knee is inadequately flexed, posterior cortical blowout may occur. **Figure 6.** Arthroscopic visualization of the tibial tunnel following reaming. The motorized shaver is placed retrograde through the tibial tunnel to smooth posteriorly and posterolaterally. **Figure 7.** An arthroscopic rasp is used to smooth the posterior tibial tunnel.



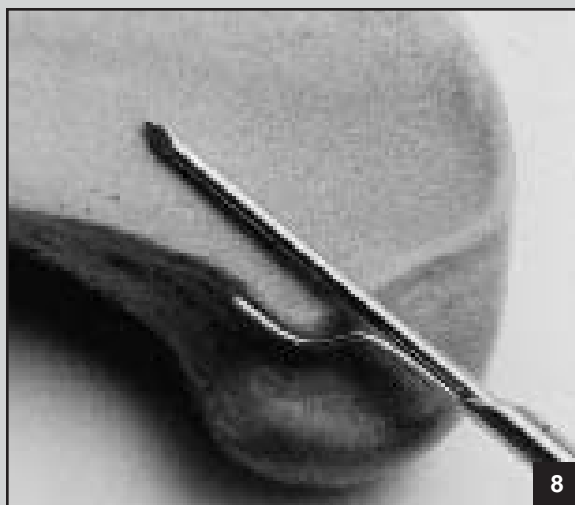
translation, we maintain the tibia in neutral rotation. The posterior edge of the tibial tunnel may be contoured with a motorized shaver to minimize cantilevering of the suture. The femoral tunnel may require repositioning. We commonly note 1-2 mm of elongation (tightening) in terminal degrees of extension. This closely mimics the normal behavior of the ACL.<sup>12,13</sup> After the Isotac has been accurately placed, the cannulated screwdriver is then replaced over the sutures retrograde through the tibial tunnel to its attachment site on the femur and is removed.

#### **Femoral Tunnel**

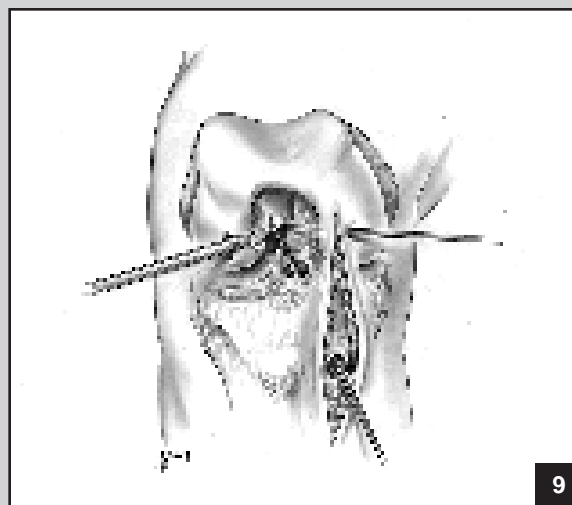
The goal of the femoral tunnel placement is to avoid placing the tunnel too far anteriorly, yet avoid posterior cortical breakout, thus leaving a 1- to 2-mm cortical shell. Pin placement guides, which key off the posterior "over-the-top" edge and have a 7-mm offset for pilot pin placement, are now available commercially from Arthrex Inc (Portsmouth, NH) and Concept Inc (Largo, Fla) (Figure 8). We have not yet used these guides, which should make femoral pin placement easier. One should recognize that the femoral drilling angles differ with this technique, and a technical adjustment must be made by the surgeon.

A calibrated guide wire pin is then replaced retrograde through the tibial tunnel with the knee flexed 90° (depending on the tibial tunnel angle) and is placed into the prior Isotac femoral attachment site or pilot burr hole established with a 2-mm round burr (Figure 9). This is tapped with a mallet or drilled to a depth of 5-7 mm further than the length of the femoral bone plug, or it can be drilled in a routine fashion. The bone is hard, especially in young patients. The femoral guide pin may skive posteriorly as it is tapped into place with the mallet; therefore, the pin placement should be reassessed with probe measurement after partial insertion.

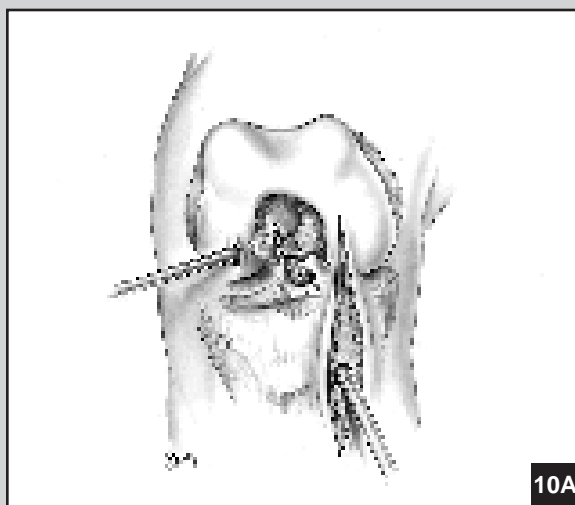
A cannulated calibrated end-cutting reamer, the identical size of the femoral bone plug width (10 mm), is manually pushed retrograde through the tibial drill hole into position over the K-wire to the level of the bone at the lateral intercondylar notch region (Figure 10). A smaller sized reamer (eg, 8 mm) may be used alternatively to create a recess and confirm accurate anatomic placement, in an attempt to minimize posterior cortical breakout. A probe can be placed anteromedially to help retract the PCL or a shaver can be placed through the anteromedial portal to aid with visualization



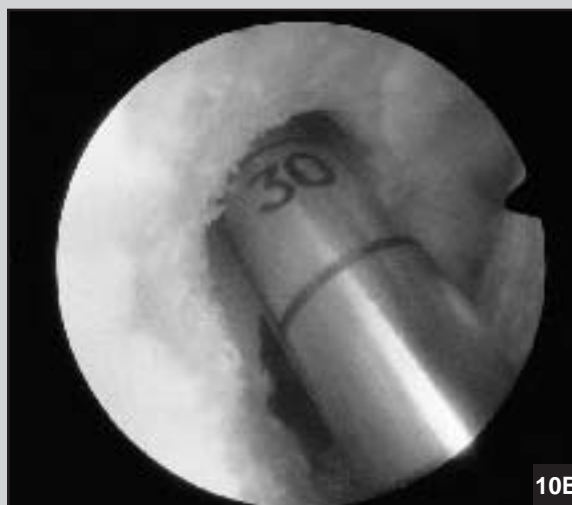8



9



10A



10B

**Figure 8.** The Arthrex femoral pin placement guide is demonstrated. This was developed to place the femoral pin 7 mm from the over-the-top location. Over-reaming with a 10-mm diameter endoscopic reamer will provide a 2-mm posterior cortical shell (photograph courtesy of Arthrex Inc, Portsmouth, NH). **Figure 9.** A 3/32-inch threaded pin is placed retrograde through the tibial tunnel with the knee flexed approximately 90°. This is tapped into the pilot hole previously established with a 2-mm round burr and drilled to a depth of 2.5-3 cm. The amount of knee flexion and extension should be minimized so that the pin is not bent. **Figure 10.** A 10-mm endoscopic reamer is manually inserted retrograde through the tibial tunnel up to the femoral region (A). This is reamed to a depth 5 mm deeper than the longest bone-plug length on the patellar tendon construct. Calibrations on the reamer allow accurate assessment of the depth of the tunnel (B).

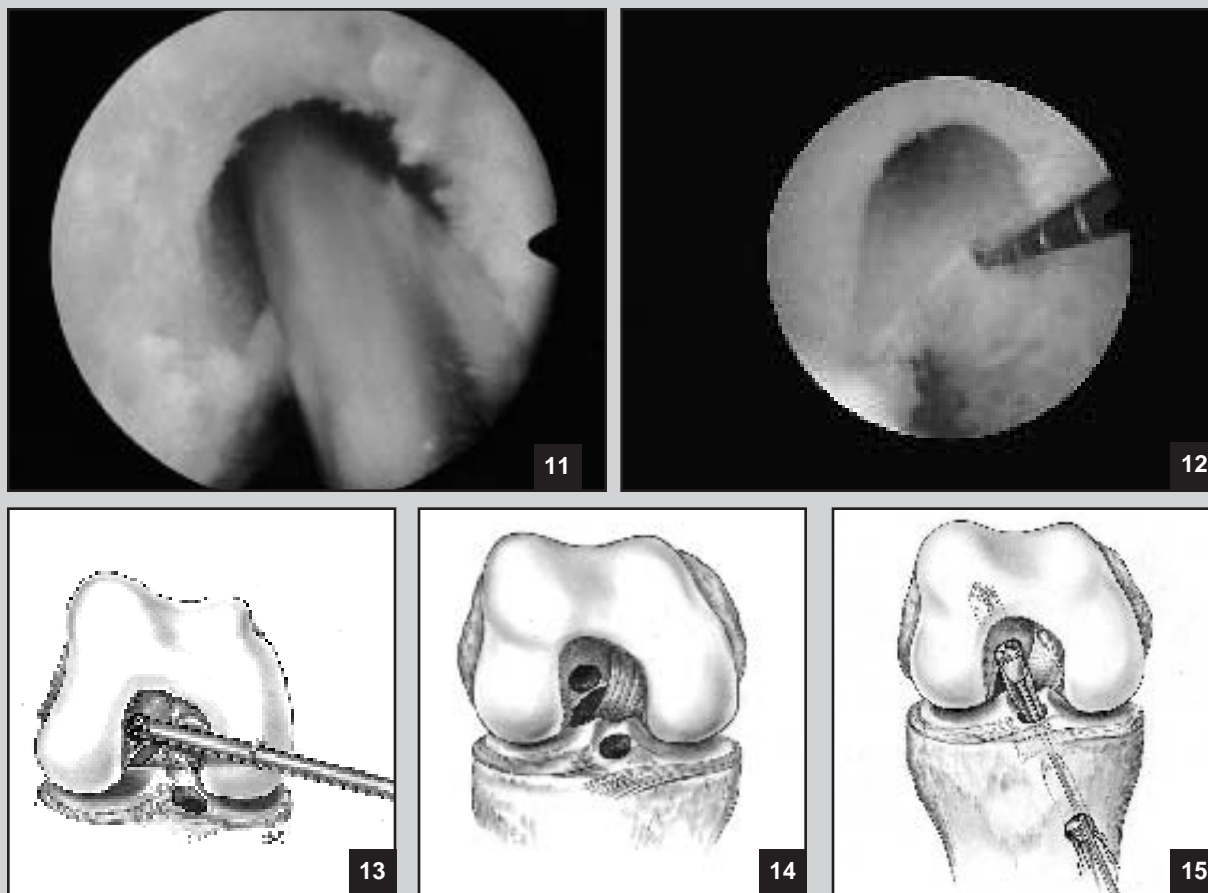
via debris removal using suction and shaving at femoral drilling.

The femoral attachment site is then drilled to a depth of 3-5 mm deeper than the femoral bone-plug length. The motorized shaver is placed retrograde through the tibial tunnel into the femoral tunnel, and removal of bone debris within the femoral tunnel is performed (Figure 11). The posterior cortical shell should be assessed with an arthroscopic probe to confirm accurate placement and integrity; 1-2 mm should remain (Figure 12). Reaming debris may collect in the posterior compartment and should be inspected. The shaver is placed through the anteromedial

portal and smoothing of the outlet of the femoral tunnel is performed along with further refinement of the notch-plasty (Figures 13 and 14).

#### **Graft Placement**

The graft has been prepared previously with three sutures in the shorter bone plug. The shorter bone plug of the graft construct is placed on the tibial side to minimize protrusion of the plug from the tibial tunnel. The tendosseous interface on the longer bone plug has been previously marked on the cancellous surface (Figure 4). The femoral tunnel is colinear to the tibial tunnel, created with



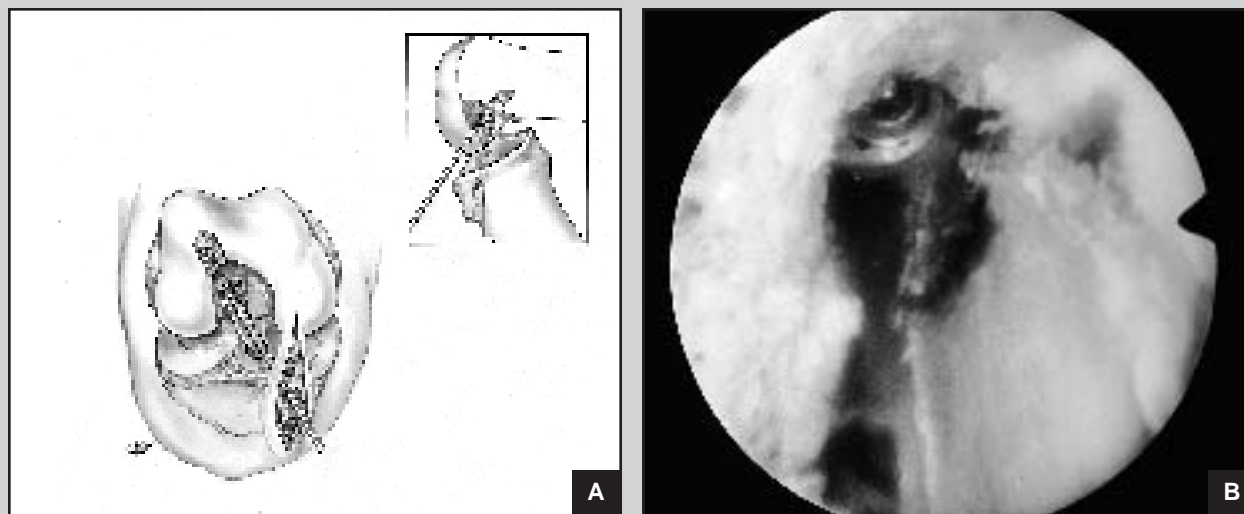
**Figure 11.** The motorized shaver is passed retrograde from the tibial tunnel. With the knee flexed approximately 90°, passage of the shaver into the femoral tunnel confirms a straight line between tunnels. Passage of the shaver into the femoral tunnel also clears any remaining cancellous remainings that may be impacted. The arthroscope likewise may be passed retrograde via the tibial tunnel to confirm posterior cortex integrity. **Figure 12.** After femoral tunnel reaming, the arthroscope probe is used to confirm that a posterior cortical has been maintained. The arthroscope can be placed in either the inferomedial portal or placed retrograde via the tibial tunnel to assist in visualization if needed. **Figure 13.** After reaming the femoral tunnel, phase two notchplasty is performed. **Figure 14.** The inner edge of the femoral tunnel is smoothed. **Figure 15.** The graft is pushed retrograde with the assistance of the Acufex "pusher" through the tibial tunnel, intra-articular, and in some situations, directly into the femoral tunnel. An arthroscopic grasping instrument or Acufex "pitbull" grasper is helpful in positioning the graft. If the cortical edge of the graft is placed posteriorly, it is less likely to injure the graft tissue during screw placement.

the knee in 90° flexion. Problems have been encountered and reported with the Beath needle "pull through" technique for graft passage. This needle has an eyelet on its trailing end and serves as a suture passer. The pin may not exit the femur and thigh where desired. It may skive along the cortex and remain intramedullary, or it may skive along the iliotibial band and exit proximal to the leg holder or tourniquet. A "push-in" technique using the Acufex Pitbull grasper (Acufex Microsurgical Inc) or small Kocher clamp to take the graft from the intra-articular tibial hole and push it up into the femoral tunnel has worked well.

The longer bone-plug end of the graft (without sutures) is pushed retrograde through the tibial tunnel with an endoscopic plunger (Acufex Microsurgical Inc) into the

notch region viewing from the anterolateral portal (Figure 15). The grasper is then used to place the bony portion of the graft into the tunnel with the cancellous surface facing superiorly. Alternatively, one may push the graft retrograde the entire distance up into the femoral tunnel recess. One can drill a threaded 3/32-inch Steinmann pin into the longitudinal axis of the bone plug to act as a "pusher." The knee is typically flexed 90°, which is the angle at which the initial femoral tunnel was created.

It is important to have the graft oriented with the cancellous aspect of the bone plug facing superiorly (anteriorly). Attempting to place the graft with the cancellous bone facing posterior makes visualization more difficult with the tendon closer to the examiner. Also, at interference



**Figure 16.** Endoscopic interference screw placement is facilitated with the placement of a flexible 14-in Nitenol (Concept Inc, Largo, Fla) through an accessory parapatellar tendon portal (A). The pin should be placed anterolaterally to the graft, initially seated, and the knee is flexed further to 120° and the pin further advanced. This places the pin parallel to the graft. A 7-mm wide, 25-mm long cannulated endoscopic screw is inserted via this accessory portal (B).

screw placement, abrasion or amputation of the tendinous portion of the graft is more likely to occur. When the bone plug is seated within the tunnel, the graft is palpated to verify that the mark at the tendon-osseous junction is at the tunnel outlet.

#### **Femoral Fixation**

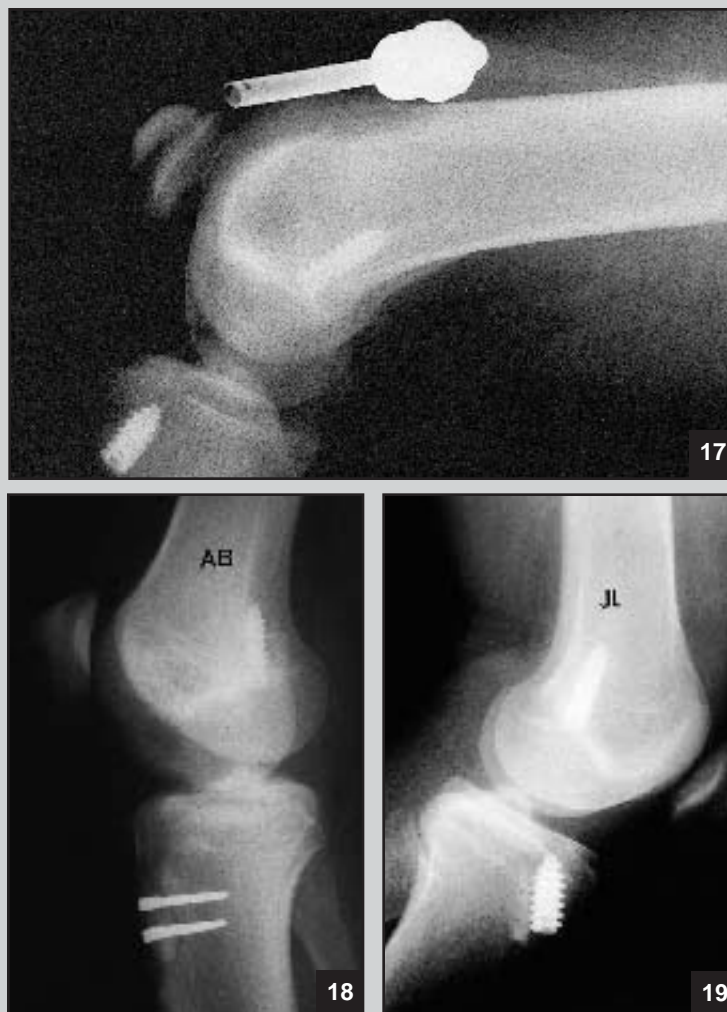A small indentation at the superior lateral outlet of the tunnel is made with an arthroscopic curette or motorized burr to allow a starting point for the cannulated interference screw.<sup>23</sup> An accessory anteromedial capsular portal (within the retracted anterior skin incision) directly above the drilled tibial tunnel is made, penetrating completely through the fat pad. The leg should be hyperflexed to approximately 120° (the difference between this portal angle and the tibial tunnel angle) so that the interference guide pin and screw can be placed directly through the accessory portal at a parallel angle (Figure 16A). Flexible Nitenol pins are available commercially from Concept Inc (Largo, Fla). The screw is now parallel to the bony graft with the tendinous portion safely posterior to the screw. Failure to appropriately hyperflex the knee may result in screw divergence and possible posterior cortical screw breakout.

The guide pin is passed anterolateral to the bone plug with the knee hyperflexed (120°) until it seats at the depths of the tunnel (drilled 3-5 mm deeper than the actual length of the bone plug). The screw is inserted with the knee held at 120° of flexion (Figure 16B). It should be verified that the graft fits snugly and does not rotate during screw placement to avoid graft injury. The remainder

of the patellar tendon graft and tibial bone plug distally can be pushed further into the joint allowing some laxity. Thus, the tendon is not on tension at placement of the screw and it can fall further posteriorly in the joint. The screw is placed on the anterolateral aspect of the graft. Typically, a 7-mm screw of the same length as the bone plug is used. Once secured, the knee should be multiply cycled with tension being placed on the tibial plug sutures to confirm rigid fixation. A true lateral intraoperative radiograph of the knee flexed at 90° can verify accurate femoral tunnel screw placement and can be obtained until the surgeon is completely comfortable with this technique (Figure 17).

#### **Tibial Fixation**

The extremity is taken through a full range of motion noting the excursion of the graft in the tibial tunnel with manual tension held on the bone-plug sutures. It is unusual to have >1-2 mm of excursion at full extension. The length of the tibial tunnel and shorter bone plug is now assessed. Tibial plug fixation is performed with the knee in extension. Approximately 25% of the time, the graft length is excessive and requires the creation of a tibial metaphyseal bone trough with either a power burr or gouge, and fixation with two 10-mm wide barbed staples (Smith & Nephew Richards Inc, Memphis, Tenn) (Figure 18). In most cases, the grafts allow for fixation using an interference fit screw placed anteromedially on the cortical edge of the tibial bone-plug (Figure 19). We do not place the screw posteriorly to the bone plug as the screw may more easily diverge and anteriorize the graft, and we



**Figure 17.** An intraoperative radiograph may be obtained to confirm accurate placement of the femoral interference screw. **Figure 18.** Lateral radiograph demonstrates placement of the femoral interference screw. Note the orientation of this screw with the knee flexed. The tibial side has been secured with two 7/16-inch barbed staples with the graft placed in a bone trough. **Figure 19.** Interference screws have been used on the femoral and tibial sides for fixation.

cannot be certain that the screw tip may be advanced beyond the bone plug possibly abrading the tendon.<sup>4,26</sup>

The graft is stabilized with a Kocher clamp or hemostat to prevent rotation during screw placement. The knee is placed through a full range of motion to check for graft dislodgment, and Lachman, anterior drawer, and pivot shift tests are performed. The arthroscope is reinserted anterolaterally and inspection of graft tension, orientation, and hardware, and assessment for graft impingement along the lateral wall or in the notch apex with full knee extension is performed. If there is impingement, the notchplasty is refined. A goal of 3-5 mm of clearance between the graft and the roof of the notch at full extension is desired. Fixation at both graft sites is rechecked.

#### **Wound Closure**

The tourniquet is deflated, hemostasis obtained, and closure performed in a routine layered fashion. The patellar tendon defect is loosely approximated with the knee flexed approximately 70°. Drains can be placed intra-articularly through one of the portals and subcutaneously anteriorly. Bone from prior reamings or harvested from the tibial tubercle defect are placed in the patellar bone defect.<sup>7</sup> Arthroscopic portals, not created through the anterior incision, are closed as is the anterior incision. A Cryocuff compression sleeve (Aircast Inc, Summit, NJ) is applied over an elastic stocking, and a drop-lock, full range-of-motion knee brace (Smith & Nephew DonJoy Inc, Carlsbad, Calif) is used during the first 6 weeks to protect the donor site.

## DISCUSSION

The senior author's (B.R.B.) initial experience with the double-incision arthroscopic-assisted ACL reconstruction was recently reviewed. Sixty-two of 75 patients were independently reviewed after minimum 2-year follow-up and average 3-year follow-up. Objective stability via negative pivot shift and KT-1000 maximum manual side-to-side differences of  $\leq 3$  mm were observed in 91% of patients. Subjective, isokinetic, functional assessment, and Noyes, modified Hospital for Special Surgery, Tegner, and Lysholm scores were encouraging. Based on these results, a decision was made to prospectively attempt the endoscopic technique with the theoretical goals of reduced morbidity, lessened hospitalization time, accelerated rehabilitation, and reduced postoperative patellofemoral pain.

The endoscopic technique is a technically demanding procedure with a steep learning curve. Visualization is more critical with this technique as the knee is flexed 90°-120° during portions of the procedure, which may tamponade inflow from the suprapatellar pouch. Pin placement must be accurate, and the retrograde placed femoral pin may be bent with inadvertent knee flexion, and possibly sheared off while reaming. The PCL may be injured while reaming the femoral tunnel. Posterior cortical shell breakout may occur, particularly if the knee is not flexed enough. If this occurs, transition to the double-incision technique is advisable with standard outside-in femoral tunnel placement to allow rigid fixation of the femoral graft.

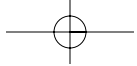
As described earlier, a "push in" technique is used rather than the Beath needle "pull through" technique to avoid the problems inherent with that technique. The cannulated screw may abrade or even amputate the graft. The screw may not obtain rigid fixation if placed in a divergent direction, and one must be certain that the screw has not violated the posterior cortex. The graft construct may be "too long," resulting in the necessity to create a trough and staple the tibial plug. Patella alta may be a relative contraindication for this technique if the surgeon desires to use interference screw fixation on the tibial side. Placing the longer bone plug on the femoral side reduces the likelihood of having a graft construct mismatch.

In knee ligament surgery, innovations are rapidly occurring before clinical follow-up studies have been performed to confirm the efficacy of our previous procedures. The endoscopic procedure is an attractive technique modification with many potential pitfalls that advanced arthroscopic ACL surgeons have experienced. Attention to detail is critical when performing this procedure. If one is to consider this technique, the surgeon must be prepared to deal with the myriad of pitfalls that may occur. The surgeon should critically assess his or her

experience and technical skills before attempting this technique. Our short-term results using this technique have been encouraging.

## REFERENCES

1. Anderson AF, Lipscomb AB, Lindahl KJ, et al. Analysis of the intercondylar notch by computed tomography. *Am J Sports Med.* 1987; 15:547-552.
2. Arms SW, Pope MH, Johnson RJ, et al. The biomechanics of anterior cruciate ligament rehabilitation and reconstruction. *Am J Sports Med.* 1984;12:8-47.
3. Bach BR Jr. Arthroscopy-assisted patellar tendon substitution for anterior cruciate ligament insufficiency: surgical technique. *Am J Knee Surg.* 1989;2:3-20.
4. Bach BR Jr. Potential pitfalls of Kurosaka screw interference fixation for ACL surgery. *Am J Knee Surg.* 1989;2:76-82.
5. Bray RC, Dandy DJ. Comparison of arthroscopic and open techniques in carbon fibre reconstruction of the anterior cruciate ligament: long-term follow-up after 5 years. *Arthroscopy.* 1987;3:106-110.
6. Clancy WC, Nelson DA, Reider B, et al. Anterior cruciate ligament reconstruction using one third of the patellar ligament augmented by extra-articular tendon transfer. *J Bone Joint Surg Am.* 1982;64:352-359.
7. Daluaga D, Johnson J, Bach BR Jr. Primary bone grafting following graft procurement for anterior cruciate ligament insufficiency. *Arthroscopy.* 1990;6:205-208.
8. DeAndrade JR, Grant C, Dixon SJ. Joint distention and reflex muscle inhibition in the knee. *J Bone Joint Surg Am.* 1965;47:313-322.
9. Eriksson E. Rehabilitation of muscle function after sports injury. Major problems in sports medicine. *Int J Sports Med.* 1981;2:1-6.
10. Friedman MJ. Arthroscopic semitendinosus (gracilis) reconstruction for anterior cruciate ligament deficiency. In: Koor L, ed. *Techniques in Orthopaedics.* Rockville, Md: Aspen Publishers Inc; 1988:74.
11. Gardener ED. The innervation of the knee joint. *Anat Rec.* 1948;101:109-130.
12. Graf B. Isometric placement of substitutes for the anterior cruciate ligament. In: Jackson DW, Drez D, eds. *The Anterior Cruciate Deficient Knee.* St Louis, Mo: CV Mosby Co; 1987:55-71.
13. Graf B, Simon T, Jackson DW. Isometric placement of cruciate ligament substitutes: a new technique. Presented at: the International Knee Meeting; May 1985; Bern, Switzerland.
14. Graf B, Uhr F. Complications of intra-articular anterior cruciate reconstruction. *Clin Sports Med.* 1988;7:835-848.
15. Hamburg P, Gilquist J, Lysholm J, Oberg B. The effect of diagnostic and operative arthroscopy and open meniscectomy on muscle strength in the thigh. *Am J Sports Med.* 1983;11:289-292.
16. Hefzy MS, Grood ES, Noyes FR. Factors affecting the region of most isometric femoral attachments. *Am J Sports Med.* 1989;17:208.
17. Houseworth SW, Mauro VJ, Mellon BA, et al. The intercondylar notch in acute tears of the anterior cruciate ligament: a computer graphics study. *Am J Sports Med.* 1987;15:221-224.
18. Jackson DW, Jennings LD. Arthroscopically-assisted reconstruction of the anterior cruciate ligament using a patellar



- tendon bone autograft. *Clin Sports Med.* 1988;7:785-800.
19. Jackson DW, Rieman PR. Principles of arthroscopic anterior cruciate reconstruction. In: Jackson DW, Drez D, eds. *The Anterior Cruciate Deficient Knee.* St Louis, Mo: CV Mosby Co; 1987:273.
  20. Johnson LL. Second look arthroscopy and biopsy: double loop semitendinosus ACL grafting. Presented at: the ACL Study Group; 1988; Snowmass, Colo.
  21. Jones KG. Reconstruction of the anterior cruciate ligament using the central one-third of the patellar ligament. *J Bone Joint Surg Am.* 1970;52:1302-1308.
  22. Keifer DA, Houseworth SA, Mauro VJ, et al. Anterior ligament tears, intercondylar notch relationship proposed. *Orthopedics Today.* January 1986;6:1.
  23. Kurosaka M, Yoshiya S, Andrich JT. A biomechanical comparison of different surgical techniques of graft fixation in anterior cruciate ligament reconstruction. *Am J Sports Med.* 1987;15:225-229.
  24. Markey KL. Rehabilitation of the anterior cruciate ligament deficient knee. *Clin Sports Med.* 1985;1:513-526.
  25. Marzo JM, Bowen MK, Warren RF, et al. Intraarticular fibrous nodule as a cause of loss of extension following anterior cruciate ligament reconstruction. *Arthroscopy.* 1992;8:10-18.
  26. Matthews LS, Soffer SR. Pitfalls in the use of interference screws for anterior cruciate reconstruction: brief report. *Arthroscopy.* 1989;5:225-226.
  27. Meade TD, Dickson TB. Technical pitfalls of single incision arthroscopic assisted ACL ligament reconstruction. *Am J Arthroscopy.* 1992;2:15-19.
  28. Mitchell N, Shepard N. The deleterious effects of drying on articular cartilage. *J Bone Joint Surg Am.* 1989;71:89-95.
  29. Moyer RA, Betz RR, Iaquinio J, et al. Arthroscopic cruciate ligament reconstruction using the semitendinosus and gracilis tendons: preliminary report. *Contemp Orthop.* 1986;12:17-23.
  30. Noyes FR, Mangine RE, Barber S. Early knee motion after open and arthroscopic anterior cruciate ligament reconstruction. *Am J Sports Med.* 1987;15:149-160.
  31. Paulos LE, Chorf J, Rosenberg TD, et al. Anterior cruciate ligament reconstruction with autografts. *Clin Sports Med.* 1991;10:469-485.
  32. Penner DA, Daniel DM, Wood P, et al. An in vitro study of anterior cruciate ligament graft placement and isometry. *Am J Sports Med.* 1988;16:238-243.
  33. Roberts TS, Drez D, Banta CJ. Complications of anterior cruciate ligament reconstruction. In: Sprague NF ed. *Complications in Arthroscopy.* New York, NY: Raven Press Publishers; 1989:169-177.
  34. Rosenberg TD. *Arthroscopic Technique for Anterior Cruciate Ligament Surgery.* Norwood, Mass: Acufex Microsurgical; 1984. Technical Bulletin.
  35. Rosenberg TD. *Arthroscopic Technique for Anterior Cruciate Reconstruction.* Norwood, Mass: Acufex Microsurgical; 1988. Technical Bulletin.
  36. Rosenberg TD. *Endoscopic Technique for Anterior Cruciate Ligament Reconstruction With Pro-Trac Tibial Guide.* Norwood, Mass: Acufex Microsurgical; 1991. Technical Bulletin.
  37. Rosenberg TD. *Technique for Endoscopic Method of ACL Reconstruction.* Norwood, Mass: Acufex Microsurgical; 1989. Technical Bulletin.
  38. Rosenberg TD, Paulos LE, Abbot PJ. Arthroscopic cruciate repair and reconstruction: an overview and description of technique. In: Feagin JA, ed. *The Crucial Ligament.* New York, NY: Churchill Livingstone; 1988:409-423.
  39. Sherman WM, Pearson DR, Plyley MJ, et al. Isokinetic rehabilitation after surgery: a review of factors which are important for developing physiotherapeutic techniques after knee surgery. *Am J Sports Med.* 1982;10:155-161.
  40. Speer KP, Callaghan JJ, Seaber AV, et al. The effects of exposure of articular cartilage to air. *J Bone Joint Surg Am.* 1990;72:1442-1450.
  41. Wainer RA, Clark TJ, Poehling GG. Arthroscopic reconstruction of the anterior cruciate ligament using allograft tendon. *Arthroscopy.* 1988;4:199-205.
  42. Warren RF. Arthroscopic meniscus repair. *Arthroscopy.* 1985;1:170-172.
  43. Wilcox PG, Jackson DW. Arthroscopic anterior cruciate ligament reconstruction. *Clin Sports Med.* 1987;6:513-524.

