

**MICHAEL J. DeFRANCO, MD**  
**REBECCA CARL, MD**  
**BERNARD R. BACH Jr, MD**

*Understanding the anatomy, biomechanics, and risk factors is essential*

## Differentiating low and high ankle sprains

**ABSTRACT:** Differentiation between low and high ankle sprains is critical to delivering appropriate care. The classic mechanism for a low ankle sprain is inversion and plantar flexion. A history of ankle ligament injury predisposes to recurring sprains. The ankle anterior drawer test may be used to evaluate ligamentous instability. Plain radiographs of the foot and ankle may be indicated in a patient who has an acute ankle injury. Clinicians often use the Ottawa ankle rules to determine the need for radiographs. In the acute phase, the goals of treatment are to alleviate pain, reduce swelling, and protect the ankle from further injury. NSAIDs and rehabilitation are important components of management. Primary prevention may be possible with strengthening and balance programs. (J Musculoskel Med. 2008;25:438-443)

Ankle sprains are the most common musculoskeletal injury in athletes, accounting for 10% to 30% of sports injuries.<sup>1</sup> Differentiation between low and high (syndesmotic) sprains is critical to delivering appropriate care to patients who sustain either injury.

An understanding of the anatomy and biomechanics of the ligaments that provide stability to the ankle and distal tibiofibular joint, as well as the risk factors for ankle sprains, is essential to performing a competent clinical evaluation. In most cases, applying this knowledge during the physical examination allows for an accurate diagnosis.

This 2-part article defines the

salient points of clinical evaluation of ankle sprains to differentiate between low and high sprains and, as a result, provide patients with the most appropriate treatment. In this first part, we focus on low ankle sprains. The second part, to appear in a later issue of this journal, will discuss diagnosis and management of high ankle sprains.

### BACKGROUND

Acute ankle injuries are especially common in persons who participate in basketball, racquet sports, gymnastics, volleyball, and soccer.<sup>1-3</sup> Athletes who compete at higher levels of play are at increased risk for ankle sprains<sup>4</sup>; they are the most common injury in college athletes, according to the National Collegiate Athletic Association Injury Surveillance Survey results, accounting for 15% of reported injuries.<sup>5</sup> Ligamentous injuries to the ankle are the most common injury regardless of the sport or exposure

type (game or practice).<sup>1,5</sup>

The incidence of reinjury in athletes with ankle sprains is significantly higher than the incidence of first-time ankle sprains.<sup>6</sup> Disability resulting from ankle sprains may be severe; 40% of patients experience dysfunction for as long as 6 months after the injury. In a Marchi and associates<sup>7</sup> study, 23% of ankle sprains resulted in permanent sequelae over 12 years.

The cost of treating patients with ankle sprains is staggering. In 2003 alone, the direct medical cost of managing ankle sprains was more than \$1 billion, according to US Consumer Products Safety Commission estimates.<sup>8</sup>

### ANATOMY AND BIOMECHANICS

Both osseous congruity and ligaments confer stability to the ankle joint. Osseous congruity exists between the tibiotalar and distal tibiofibular joints.

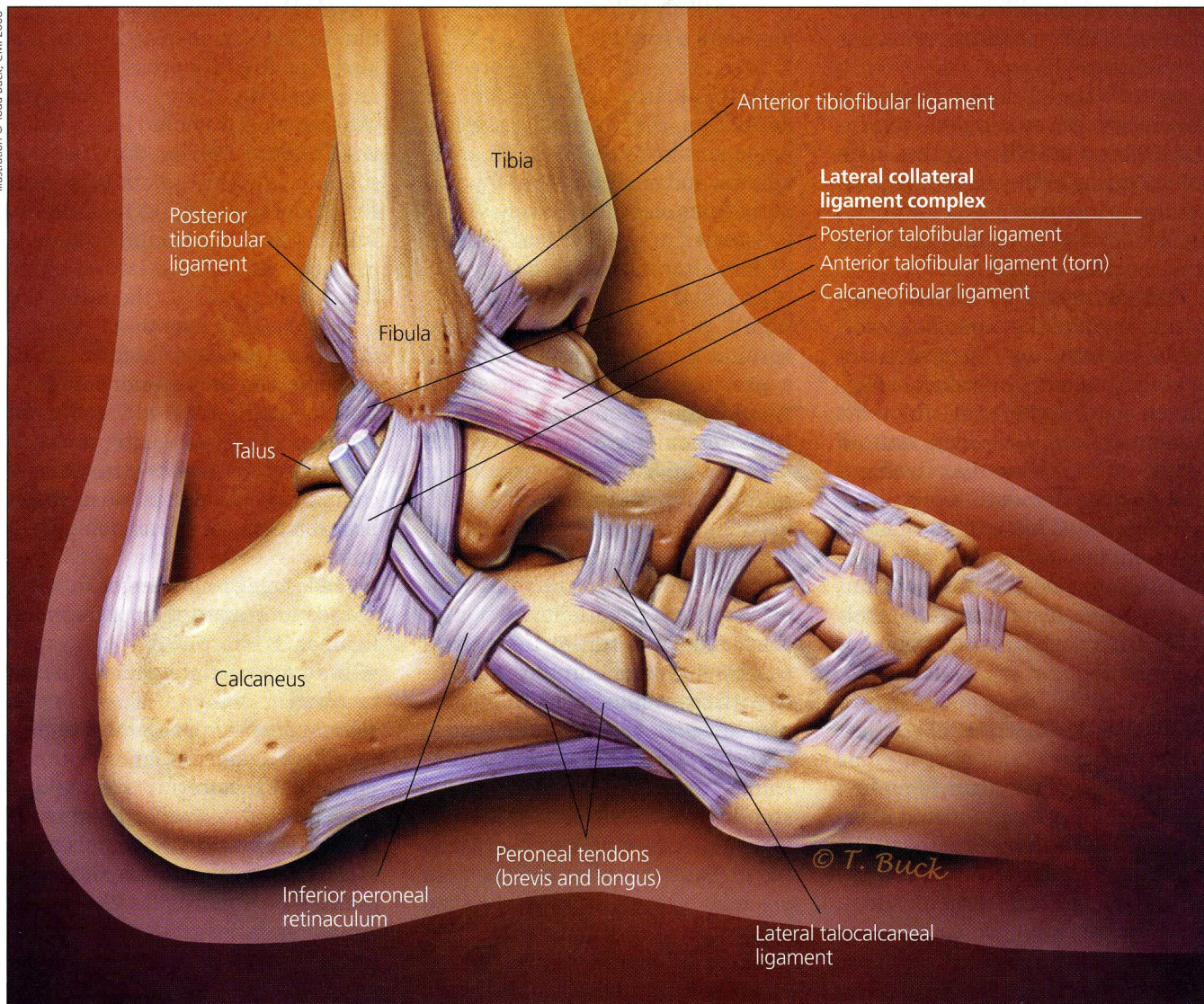
*Dr DeFranco and Dr Carl are primary care sports medicine fellows, and Dr Bach is professor, The Claude N. Lambert, MD-Helen S. Thomson Endowed Chair of Orthopedic Surgery, and head of the section of sports medicine, Sports Medicine Fellowship Program, at Midwest Orthopaedics at Rush University Medical Center in Chicago.*

The ligaments on the lateral side of the ankle consist of the anterior talofibular ligament (ATFL), calcaneofibular ligament (CFL), and posterior talofibular ligament (PTFL) (Figure 1). The relationship between the positions of the talus and the longitudinal tibial axis determines

the function of the ankle ligaments. The ATFL is perpendicular and the CFL is parallel to the longitudinal axis of the tibia with the ankle in neutral dorsiflexion. In this position, the CFL resists inversion stress and varus tilt of the talus. With dorsiflexion, the CFL experi-

ences more strain. With plantar flexion, internal rotation, and inversion, strain increases in the ATFL.

Plantar flexion is the position in which a lateral ankle ligament injury most often occurs. In this position, the ATFL is parallel and the CFL is perpendicular to the longi-



**Figure 1** – The lateral anatomy of the lower ankle is shown in this drawing. Both osseous congruity and ligaments confer stability to the ankle joint. The ligaments on the lateral side consist of the anterior talofibular ligament, calcaneofibular ligament, and posterior talofibular ligament. The relationship between the positions of the talus and the longitudinal tibial axis determines the function of the ankle ligaments. Plantar flexion is the position in which a lateral ankle ligament injury most often occurs.

