

An Unusual Neurological Complication of the Bristow Procedure

A CASE REPORT*

BY BERNARD R. BACH, JR., M.D.†, STEPHEN J. O'BRIEN, M.D.‡, RUSSELL F. WARREN, M.D.‡, AND MICHAEL LEIGHTON, B.A.§, NEW YORK, N.Y.

From the Sports Medicine Service, The Hospital for Special Surgery, New York City

The Bristow procedure, first described in the literature by Helfet in 1958, is an operation for recurrent anterior subluxation or dislocation of the shoulder that involves transfer of the coracoid process to the margin of the glenoid fossa to create a bone block, thus preventing redislocation. Various technical modifications have been described^{6,8}. The operation has become popular because it is technically easier than a Bankart repair, is associated with a low rate of redislocation^{7,10}, and has few complications, although problems with screw fixation have not been uncommon¹¹. We are reporting an unusual complication of the Bristow procedure.

Case Report

In August 1977, an eighteen-year-old woman, a competitive collegiate swimmer who was right-hand dominant, sustained a subluxation of the right shoulder while swimming, and thereafter she had many such episodes. All were followed by severe pain. In December 1977, a modified Bristow procedure was done. Intraoperatively, a small Bankart lesion was noted at the anteroinferior part of the labrum. A Hill-Sachs deformity was not noted. The distal two centimeters of the coracoid process, with the entire conjoined tendon, was transferred through the incised subscapularis and attached to the glenoid fossa with a lag screw. The postoperative course was uneventful.

The patient did well for a year until, while swimming, she noted a sudden looseness and crepitation in the right shoulder associated with burning pain, which subsequently extended down the arm into the fourth and fifth digits of the right hand. There was no objective neurological deficit. Radiographic evaluation showed that the screw had backed out from the original position and was displaced approximately 1.3 centimeters (Fig. 1).

In February 1979, the screw and overlying bursa were removed through the distal two-thirds of the previous deltopectoral incision. The coracoid process was noted to be well healed in its transferred position. The pain was relieved. However, the patient was seen again in July 1981 with a recurrence of pain and with increased paresthesias in the fourth and fifth digits. A soft-tissue prominence was noted in the axilla, and a bruit was heard when the arm was abducted and externally rotated.

Electromyography of the muscles that are supplied by the ulnar nerve — the flexor digitorum profundus, abductor pollicis brevis, first dorsal

interosseous, and abductor digiti quinti — were negative. An arteriogram was refused by the patient. The symptoms continued. In April 1985 she was re-examined because of localized pain in the ulnar distribution of the fourth and fifth digits of the right hand and weakness in the hand, particularly when the arm was in the overhead position of abduction and external rotation. The range of motion of the shoulder was decreased in external and internal rotation. With the arm in the abducted position, the previously

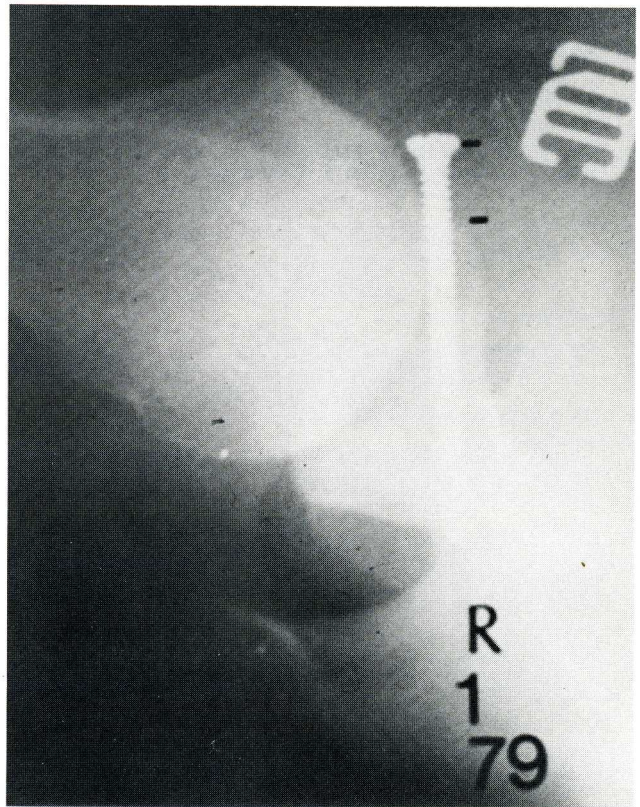


FIG. 1

Axillary radiograph showing migration of the screw.

noted bruit was not present, but a prominence in the axilla, previously noted on deep palpation, remained. Sensory examination revealed decreased sensation to pinprick in the distribution of the lateral antebrachial cutaneous nerve, but sensation in the digits was intact. The electromyograms again were normal. An arteriogram was negative.

Clinically, our impression was that there was an injury to the musculocutaneous nerve related to the transferred conjoined tendon, and an exploration of that nerve was done. When the patient was under anesthesia, the shoulder was stable to examination. Intraoperatively, it was noted that

* No benefits in any form have been received or will be received from a commercial party related directly or indirectly to the subject of this article. No funds were received in support of this study.

† Rush Presbyterian-St. Luke's Medical Center, Professional Office Building, Suite 492, 1725 West Harrison Street, Chicago, Illinois 60612.

‡ Sports Medicine Service, The Hospital for Special Surgery, 535 East 70th Street, New York, N.Y. 10021.

§ University of Medicine and Dentistry of New Jersey, Rutgers Medical School, Piscataway, New Jersey 08854.

The pain usually is severe and becomes worse with activity, and it is often present at night. The only physical finding that can be elicited is exquisite tenderness over the medial aspect of the tibial plateau. Early in the disease, the roentgenograms either are normal or show minor arthritic changes. Injection of the joint with local anesthetics or steroids does not relieve the pain. The bone scan or a magnetic resonance imaging scan is of value in making an early diagnosis.

The use of crutches and relief from weight-bearing may prevent the collapse of the medial plateau in many patients and avoid an arthroplasty. If the disease is not extensive, healing may occur without collapse of the plateau.

Lotke and Ecker¹ noted that this condition often is misdiagnosed as a torn meniscus and that arthroscopy is performed, without affording relief of the symptoms. Pes anserinus bursitis may also be confused with osteonecrosis, but if there is no improvement after treatment by local injection of the bursa with a steroid, the diagnosis of osteonecrosis should be considered. The patient who has only slight arthritic changes in the knee joint will not have the sudden and severe pain that is associated with osteonecrosis of the femoral condyle or tibial plateau.

Although most symptoms will resolve in a year, Lotke and Ecker² reported on two patients who had a lesion of the tibial plateau that caused collapse of part of the surface of the tibial articulation. The cases of these two patients were unusual because of the localized lesion in the tibial plateau. The pathological specimen in my patient is an excellent illustration of this disease and confirms the findings of Lotke and Ecker^{1,2}, but it also revealed one additional finding — a roentgenographically identifiable longitudinal fracture through the rim of the plateau (Fig. 1-C). This undoubtedly followed the crush-down of the subjacent necrotic bone.

Another woman, eighty-one years old, who had the same complication was seen by me also. The roentgenogram revealed a fracture of the medial aspect of the cortical rim of the tibia, adjacent to the area of osteonecrosis (Fig. 2-A). A unicompartmental arthroplasty was necessary to relieve the pain (Fig. 2-B).

Treatment of the patient at the time of early diagnosis should be conservative, because most of the lesions will heal spontaneously when the patient is treated with protected weight-bearing. Once there is collapse or fracture of the plateau, arthroplasty may be indicated.

References

1. LOTKE, P. A., and ECKER, M. L.: Osteonecrosis-Like Syndrome of the Medial Tibial Plateau. *Clin. Orthop.*, **176**: 148-153, 1983.
2. LOTKE, P. A., and ECKER, M. L.: Osteonecrosis of the Knee. *Orthop. Clin. North America*, **16**: 797-808, 1985.

the entire conjoined tendon, not including the pectoralis minor but with a bone block of the coracoid process, had been transferred to the so-called five-o'clock position on the glenoid fossa. A large amount of scar tissue surrounded the transferred conjoined tendon, extending both medially to its original position and inferiorly to the lower half of the subscapularis. The musculocutaneous nerve, which could be seen originating from the lateral cord of the brachial plexus, entered the muscular portion of the conjoined tendon quite proximally, 1.5 centimeters from the tip of the transferred coracoid process (Fig. 2). This proximal site of the muscular insertion resulted in a tenting effect, with traction on the brachial plexus as the arm was abducted. The traction on the nerve and plexus could be demonstrated intraoperatively to be markedly exacerbated when the arm was abducted. In addition, the coracoid process (on the glenoid fossa) was prominent, placing pressure on the neurovascular structures when the arm was abducted. The operative treatment consisted of dissecting the musculocutaneous nerve from the subscapularis and following it proximally, as well as separating the conjoined tendon from the coracoid process and allowing it to slide distally, thereby releasing the tension on the musculocutaneous nerve. The coracoid bone graft on the glenoid fossa was trimmed to decrease pressure on the plexus with elevation of the arm. Postoperatively, the patient did well, and there were no complications. Over the first six months, there appeared to be significant improvement compared with the preoperative status.

Two years postoperatively, the patient had normal strength of all muscle groups and normal motion. She continued to have paresthesias involving the ulnar-nerve distribution, although it was mildly improved compared with the preoperative status. Decreased sensation was again noted over the distribution of the lateral antebrachial cutaneous nerve. The symptoms were exacerbated by abduction and external rotation of the shoulder, although to a lesser degree than preoperatively. Surgical treatment appeared to have resulted in only slight improvement.

Discussion

The Bristow procedure and its modifications have been associated with a low rate of redislocation and have not resulted in a high incidence of complications, although problems with screw fixation around the shoulder have been common¹¹ and vascular problems have been reported^{1,2,4}. In addition, after the operative procedure, athletic patients generally cannot return to a high level of performance in sports that require overhead activities, particularly throwing^{7,10}.

In our opinion, our patient's symptoms were related to abnormal tension applied to the musculocutaneous nerve,

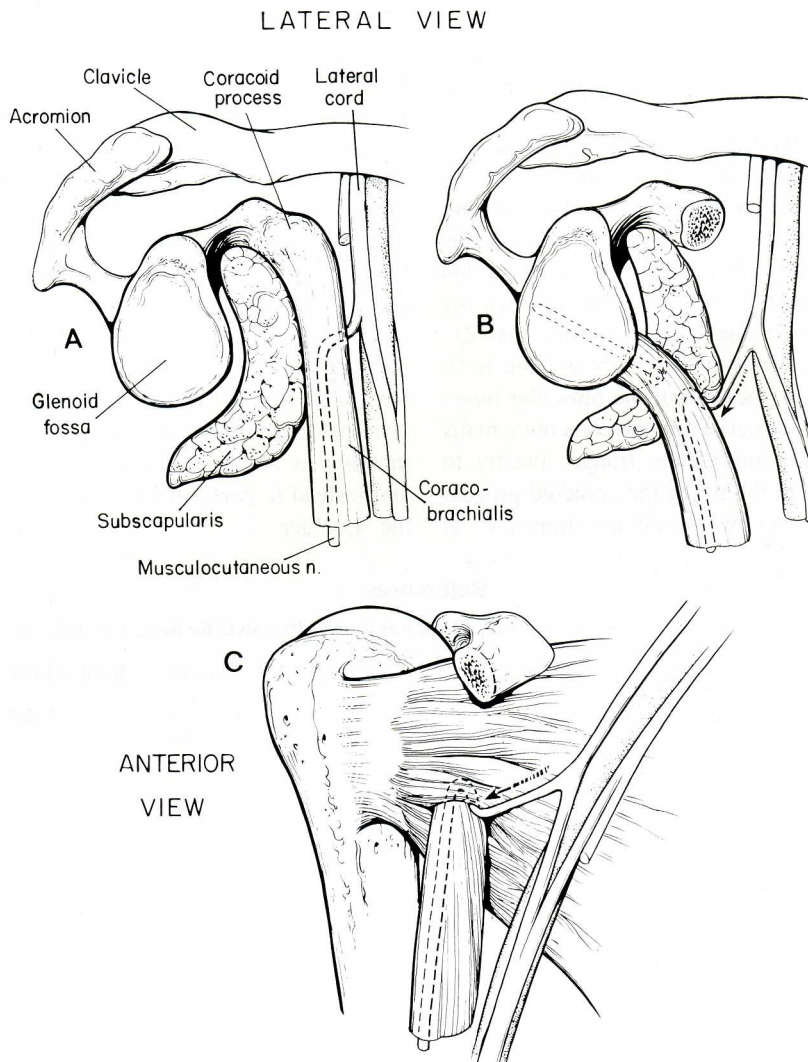


FIG. 2

A: Lateral view depicting the relationship of the proximal take-off of the musculocutaneous nerve to the conjoined tendon in this patient. The nerve entered the coracobrachialis 1.5 centimeters distal to the coracoid process.

B and C: Lateral and anterior views demonstrating the tenting effect on the musculocutaneous nerve and the increased tension on the lateral cord of the brachial plexus when the patient had a modified Bristow procedure.

