

## Plica Excision: Revisited

John-Paul H. Rue, MD, Amon T. Ferry, MD, and Bernard R. Bach, Jr, MD

*Division of Sports Medicine*

*Department of Orthopaedic Surgery*

*Rush University Medical Center*

*Chicago, Illinois, U.S.A.*

### ■ ABSTRACT

A step-wise and systematic technique for safe, efficient, and thorough excision of a plica shelf is described. Although there is considerable debate regarding plica in general, there are clearly cases where a plica shelf is the cause of a patient's pain. This technical note describes a simple technique that, when expanded upon, can give a surgeon the tools required to perform a more complex synovectomy for various conditions such as an arthrofibrotic or septic knee.

**Keywords:** plica, excision, synovectomy, debridement

### ■ HISTORICAL PERSPECTIVE

The medial patellar plica represents a thin, filmy, pliable remnant of embryonic mesenchymal tissue that is typically resorbed by the 10th week of embryologic life.<sup>1</sup> When present, the medial plica runs in the coronal plane from the infrapatellar fat pad to the medial wall of the knee approximately one fingerbreadth medial to the patella. The overall incidence of medial plicae based on the literature ranges from 9% to 64%.<sup>2-5</sup> There is, however, considerable debate as to what percentage is symptomatic. It has been proposed that a plica may become symptomatic after blunt trauma to the anterior knee leading to an inflammatory response and ultimately a thickened inflamed synovial fold.<sup>3,4</sup> Further impingement of this now thickened plica can cause predictable and reproducible pain with direct pressure or when tension is placed on the sensitive synovial tissue.<sup>5</sup>

Athletes at risk for symptomatic medial plica include bicyclists, runners, rowers, and others where direct blows to the medial aspect of the knee may occur. Patients with a symptomatic medial plica primarily complain of medial parapatellar pain and occasional snapping with repeated flexion and extension of the knee between 30 and 60 degrees. Symptoms may overlap those of medial meniscal pathology. On examination, the most common finding is pinpoint medial parapatellar

tenderness. Patients may demonstrate a bandlike distribution of pain from the medial midpatellar region to the medial joint line. Less commonly, intermittent swelling and instability may be related.<sup>4</sup> When a patient's preoperative findings are suggestive of a medial plica and a corresponding thickened medial plica shelf or sheet is encountered and excised at the time of arthroscopy, the patient's symptoms reliably and quickly resolve. This article details a stepwise technique to arthroscopically excise a symptomatic medial plica.

### ■ INDICATIONS AND CONTRAINDICATIONS

Arthroscopic examination of the knee is indicated after failure of conservative management including but not limited to rest, ice, nonsteroidal anti-inflammatory medications, physical therapy, and avoidance of overuse activities.<sup>6</sup> A symptomatic medial plica is typically thickened, fibrotic, and prone to impingement and can be capable of causing bony erosions of the medial femoral condyle<sup>4</sup> (Fig. 1). Our indications for excision of a pathologic plica are based on the correlation of the clinical examination, the patient's history and symptoms, and intraoperative findings.

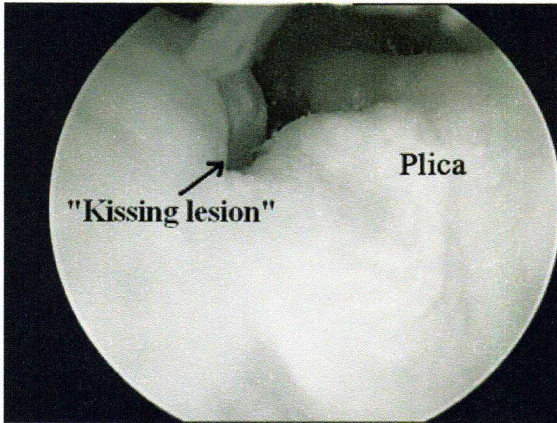
### ■ PREOPERATIVE PLANNING

A detailed history and physical examination with appropriate imaging are recommended to identify possible co-existent pathology, which may need to be addressed at the time of arthroscopy.

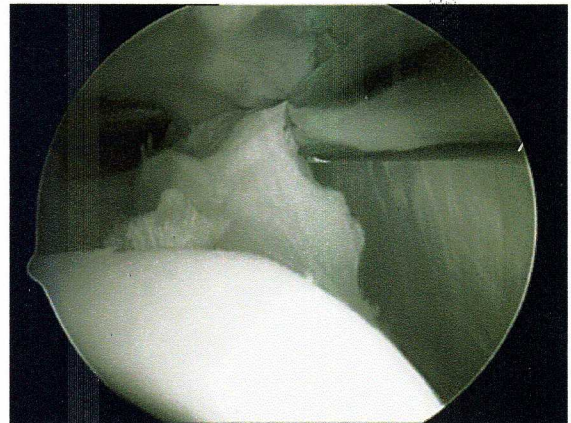
### ■ TECHNIQUE

The patient is positioned supine on the operating room table. Either a lateral post or an arthroscopy leg holder may be used, depending on surgeon preference. A tourniquet is placed and may be used if needed, depending on surgeon preference. Although medial plica excision is frequently approached from a superolateral portal, we have evolved to a technique exclusively using the standard inferomedial and inferolateral arthroscopic portals. We have observed that many patients who have classic

Address correspondence and reprint requests to Bernard R. Bach, Jr, MD, 1725 W. Harrison St, Suite 1063, Chicago, IL 60612. E-mail: brbachmd@comcast.net.



**FIGURE 1.** A large, thickened plica may have a "kissing lesion" on the medial femoral condyle due to the erosive effect of the plica shelf.

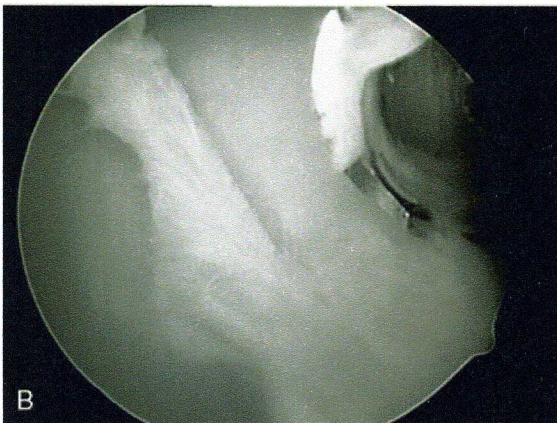
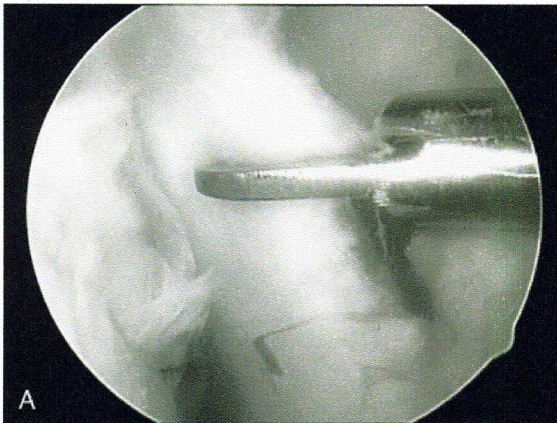


**FIGURE 3.** Once the interval between the plica shelf and the joint capsule is fully exposed, the shaver is used to debride the inferior and superior leaves of the shelf.

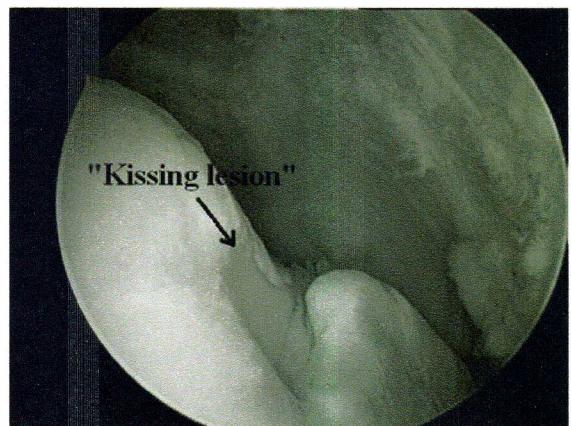medial plica symptoms may, at the time of arthroscopy, have a medial plica, which is adherent to the overlying capsule, and, thus, not visualized as a classic plica shelf, but rather as a thickened plica sheet, which is

only visualized after debridement is initiated. Because of this, the initial key step in excision is to define the interval between the plica and the overlying capsule.

The debridement begins with the knee in flexion. With the arthroscope in the standard inferolateral portal, a large motorized shaver is used to debride the fat pad anteromedially, working medially to the periphery of the medial femoral condyle. Occasionally, either an arthroscopic scissors or motorized shaver is used to start the excision (Fig. 2). The goal is to expose the interval between the thickened medial plica and the overlying capsule. The shaver opening should not be directed toward the capsule because one can easily create capsular herniations. By maintaining visual contact with the cutting surface of the shaver and maintaining positive control of the shaver's suction, the surgeon is able to



**FIGURE 2.** An arthroscopic scissors (A) or motorized shaver (B) is used to create a layer between the plica shelf and the overlying joint capsule.



**FIGURE 4.** The anteromedial aspect of the knee should be closely inspected through a full range of motion after plica debridement to ensure that no remnant of the plica remains.

