
Arthroscopy-Assisted Patellar Tendon Substitution for Anterior Cruciate Ligament Insufficiency

Surgical Technique

Bernard R. Bach, Jr, MD

ABSTRACT: Numerous operative procedures have been described to stabilize the clinically symptomatic ACL insufficient knee. During the past 20 years, primary repair with and without augmentation, extra-articular tenodesis, combined intra- and extraarticular, and patellar tendon reconstruction have been popularized as surgical techniques for ACL reconstruction. The latter half of the 1980s has witnessed the evolving techniques of arthroscopy-assisted ACL reconstruction which use a variety of autogenous and synthetic tissues. The surgical description of arthroscopy-assisted ACL reconstruction using patellar tendon is presented, emphasizing a step-by-step approach and potential pitfalls that the surgeon may encounter.

From the Sports Medicine Section, Department of Orthopedic Surgery, Rush-Presbyterian-St Luke's Medical Center, Chicago.

Address reprint requests to Bernard R. Bach, Jr, MD, Director, Sports Medicine Section, Department of Orthopedic Surgery, Rush-Presbyterian-St Luke's Medical Center, 1725 W Harrison, Suite 492, Chicago, IL 60612.

Introduction

Marked progress in the current understanding and treatment of the anterior cruciate ligament (ACL) insufficient knee has occurred during the past decade. The use of the patellar tendon as a free nonvascularized bone-ligament-bone construct for the surgical reconstruction of the ACL insufficient knee has been advocated for acute and chronic insufficiency. Noyes' classic biomechanical studies demonstrated that a 14 mm patellar tendon graft was 158% as strong as the normal anterior cruciate ligament.⁵⁵ The appealing biomechanical properties of this construct, the ability to achieve bone-to-bone union allowing early range of motion, the easy surgical access to the tissue, and the apparent minimal surgical morbidity of graft harvesting, with regard to late patellar tendon rupture^{9,45} or patellar fracture,^{44,47,69} are all attractive aspects of the use of the patellar tendon for ACL insufficiency. This article describes the technique of arthroscopy-assisted, patellar-tendon substitution for ACL insufficiency.




Fig. 1: Variation in the position of the hip and tibial rotation may affect the magnitude of the pivot-shift phenomenon. Relaxation of the iliotibial band with hip abduction and external rotation provides an easily demonstrable pivot shift. Tibial internal rotation may dampen the pivot shaft, as can hip adduction (Reprinted from *The American Journal of Sports Medicine*, in press).

Jones presented the concept of utilizing a strip of the patellar tendon to surgically replace the ACL.^{38,39} He did not use a free bone-ligament-bone construct, and the concepts of isometry and anatomic positioning of the graft were not emphasized at that time.^{6,29,48,61} Subsequently, Clancy,^{13,15-17} Noyes,⁵⁶ and Paulos⁶⁰ popularized the use of the vascularized medial and lateral one-third of the patellar tendon for ACL substitution. Currently, many ligament surgeons favor the use of a free central third patellar-tendon, bone-ligament-bone construct when using autogenous tissues.^{12,34,62,63} Arthroscopy-assisted techniques which use a variety of autogenous tissues have been described.^{22,28,36,37,51} Additionally, numerous authors have described the use of the ACL arthroscopy-assisted techniques with allograft tissues^{11,24,26,54} or synthetic ligaments.^{10,21,23,32,65}

The advantages of an arthroscopy-assisted technique are numerous. One of the major problems associated with ACL surgery, in general, has been the high incidence of postoperative patellar pain. This may, in fact, be secondary to rehabilitation techniques, but it is thought by many that an arthrotomy may be responsible for the development of patellar-pain symptoms. An arthroscopy-assisted technique obviates the use of an antero-medial arthrotomy and is theoretically advan-

tageous in that the incidence of patellar pain should be reduced and capsular mechanoreceptors are not violated. By avoiding an arthrotomy, early range of motion, less postsurgical morbidity and pain, and shortened hospitalization become feasible. Additionally, the articular cartilage is not exposed to desiccation during the course of a closed operative procedure.

Preliminary Technique

The patient is placed in the supine position. A lateral valgus post is removed after diagnostic arthroscopy. A tourniquet is placed high on the thigh, although this technique can be performed without inflating the tourniquet. The majority of the operative procedure is done with the knee flexed at approximately 45° to 60°. Alternatively, a leg-holder may be employed with the foot of the table dropped so that the surgeon is directly facing the knee. Routinely, 1 gm of a first-generation cephalosporin is administered intravenously within 30 minutes of the skin incision and is continued for 24 hours postoperatively. Prior to diagnostic arthroscopy, an examination under anesthesia is carefully performed and the results are recorded. Particular attention is paid to the Lachman test and the presence or absence of an end point. Additionally, the pivot-shift test is performed (Fig. 1). The position of 20° of hip abduction and tibial external rotation relaxes the iliotibial band and provides the greatest magnitude of the pivot-shift phenomenon.⁸ Varus-valgus laxity at 0° and 30°, as well as posterior cruciate laxity via the posterior sag, recurvatum, and posterior drawer tests are assessed. Posterolateral rotatory instability should be addressed, both at 90° and 30°.^{27,30} Once a careful ligament examination has been performed and recorded, a KT-1000 evaluation under anesthesia is performed.^{5,18,46}

Diagnostic Arthroscopy

Routine superomedial cannula inflow, with inferolateral and inferomedial portals are used for diagnostic arthroscopy. A diluted 1:300,000 epinephrine solution is injected intraarticularly, and one can generally proceed with a diagnostic arthroscopy without inflating the tourniquet. This is advantageous, as ACL reconstruction and concomitant meniscal repair may result in lengthy tour-

niquet times. Inflow is attained using the gravity technique, although inflow pumps have also been used. Four bags of inflow solution are connected to #5 TURP tubings (Fig. 2) which are connected near the arthroscopic inflow cannula with a Y-connector, allowing the surgeon to control the inflow. In the author's experience, less inflow is used with the gravity technique compared to inflow pumps.

Diagnostic arthroscopy is performed in a standard fashion. Particular attention must be paid to partial thickness tears in the posterior horns of the medial and lateral menisci, which are often longitudinal.⁶⁸ If these tears are stable, are of partial thickness, and are within the vascular zone, they are neither resected nor repaired. The presence of a bucket-handle tear is commonly associated with ACL insufficiency and a decision of bucket-handle resection versus meniscal repair must be made.^{14,19,20,31,35,49,50,66,67,71} The vascular zones must be carefully assessed.^{2,3} Depending on the location of the tear, "inside-out"^{50,67} or "outside-in,"^{31,35,49,66} techniques for meniscal repair may be employed. Sometimes a combination will be required. If meniscal repair is performed at the time of ligament reconstruction, the author generally does not tie these sutures onto the capsule until the ligament reconstruction has been performed.

Some surgeons perform meniscal repair as a staged procedure prior to ligament reconstruction. The author prefers to stabilize the meniscus at the time of ligament reconstruction, believing that the fibrin and platelet derived growth factors from the hemarthrosis enhance meniscal healing.

Articular surface defects must be critically evaluated. One common area is in the normal indentation in the lateral femoral condylar region slightly posterior to Blumensaat's line. In chronic ACL insufficiency with repetitive episodes of instability, this indentation may become exaggerated and has been described as the "lateral notch sign" of ACL insufficiency.⁷⁰ It is interesting to note that, frequently, in chronic ACL insufficiency, the torn ACL may scar to adjacent intercondylar structures. It is common to see a long remnant of former ACL tissue which has scarred to the adjacent posterior cruciate ligament so that the ligament remnants have a vertical orientation. The intercondylar wall of the lateral femoral condyle is then easily visible

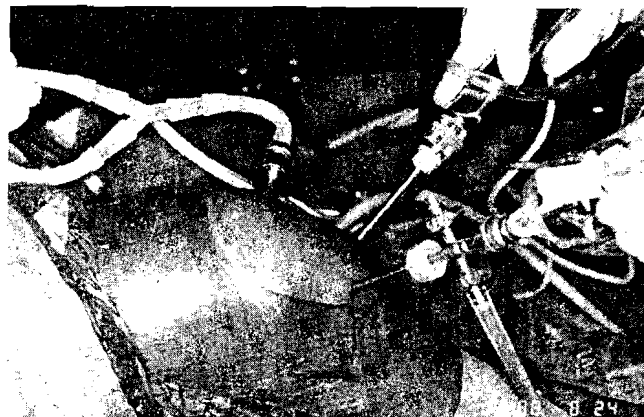


Fig. 2: A standard superomedial cannula inflow portal connected to a Y-tube allows the surgeon to monitor arthroscopic inflow. The anterolateral portal is made 4 mm distal to the distal patellar pole and close to the patellar tendon, allowing a 25° arthroscope to easily view the lateral intercondylar wall. A standard inferomedial portal is used for probe insertion and motorized notch debridement and notchplasty. A midpatellar portal may also be used to view the tibial drill hole site through the patellar tendon rent.

and has been described as an "empty wall sign." In a prospective study of 84 patients with ACL insufficiency, the empty wall sign and a vertical strut were present in 82% and 50% of the patients, respectively.⁷

Intercondylar Preparation

Intercondylar preparation and notchplasty are addressed once diagnostic arthroscopy, meniscal resection, and/or meniscal repair have been performed. The anatomy of the intercondylar notch has been well described by Kieffer,^{40,41} Anderson,¹ and Houseworth.³³ The intercondylar notch varies in size and shape, the average width being 22 mm. The ligamentum mucosum should be resected from the apex of the anterior outlet early in the notchplasty to facilitate visualization throughout the procedure.

The second step in intercondylar preparation is debridement of the remaining ACL tissue. In the knee with acute ACL injury undergoing patellar tendon substitution, it is important to debride residual tissue aggressively to visualize the intercondylar wall of the lateral femoral condyle and the ligament insertion site on the tibial eminence. If the tibial eminence region is not debrided, soft tissue incarceration may occur as the graft is passed intraarticularly. Debridement is accomplished with

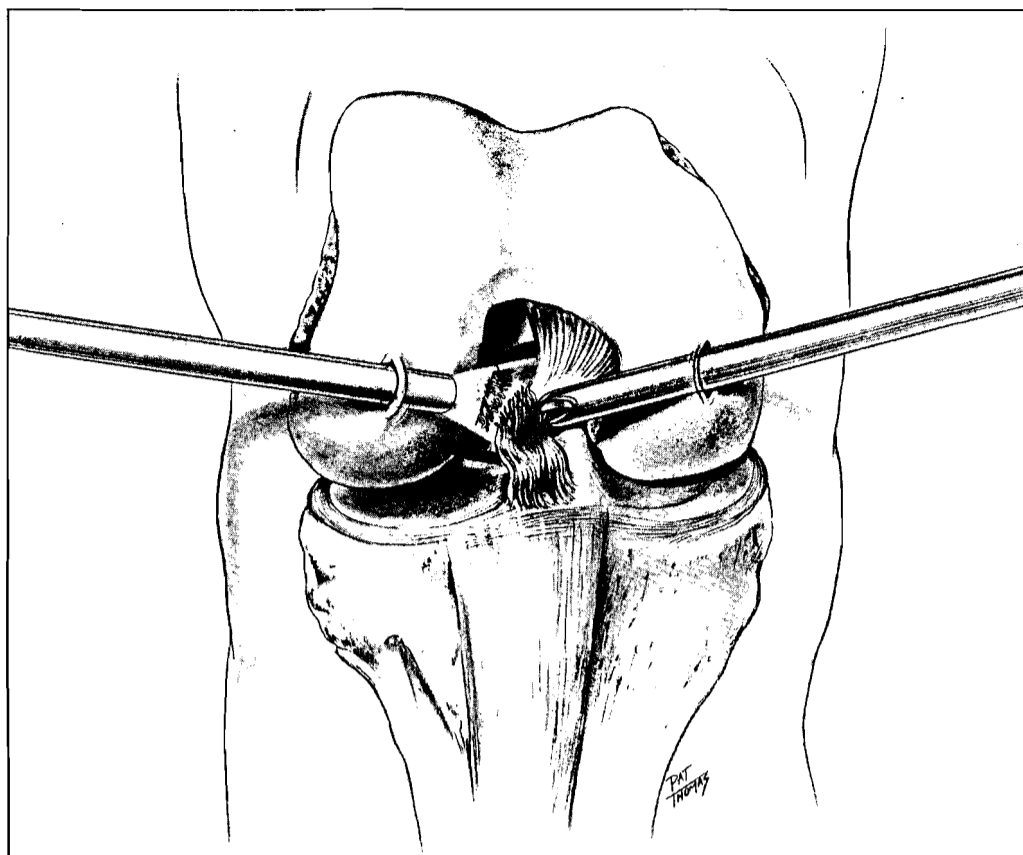


Fig. 3: A motorized shaver inserted through the inferomedial portal is used to debride ACL remnant tissues, including the tibial stump. The shaver may be used to perform notchplasty.

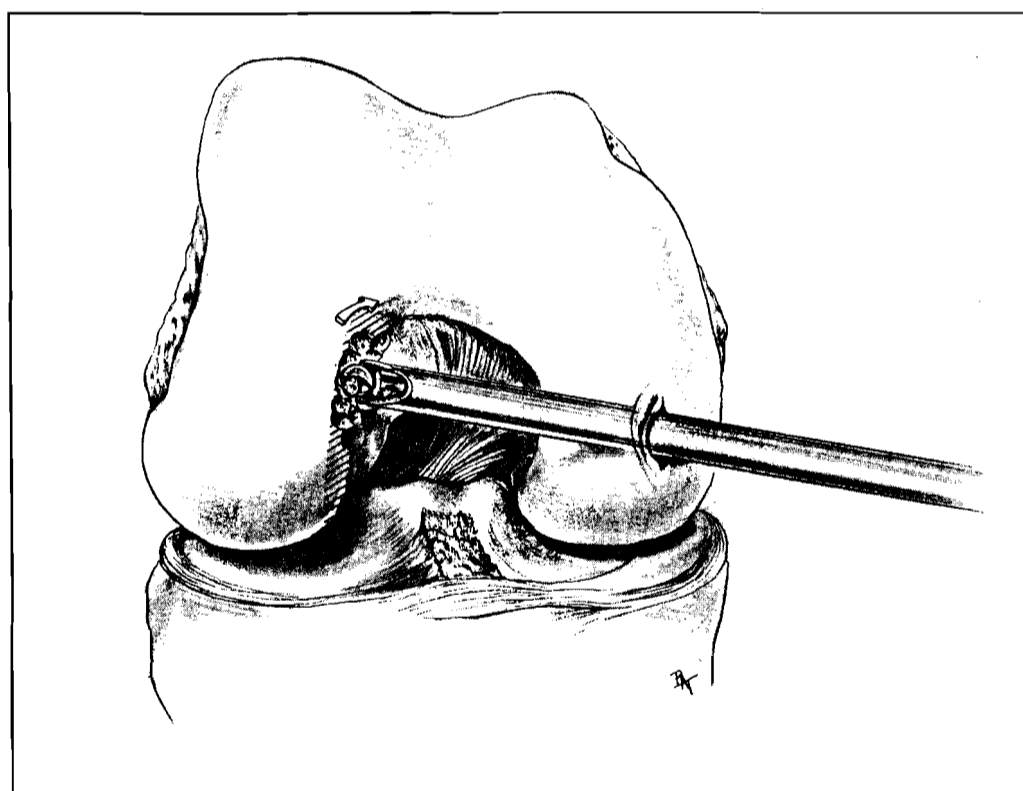
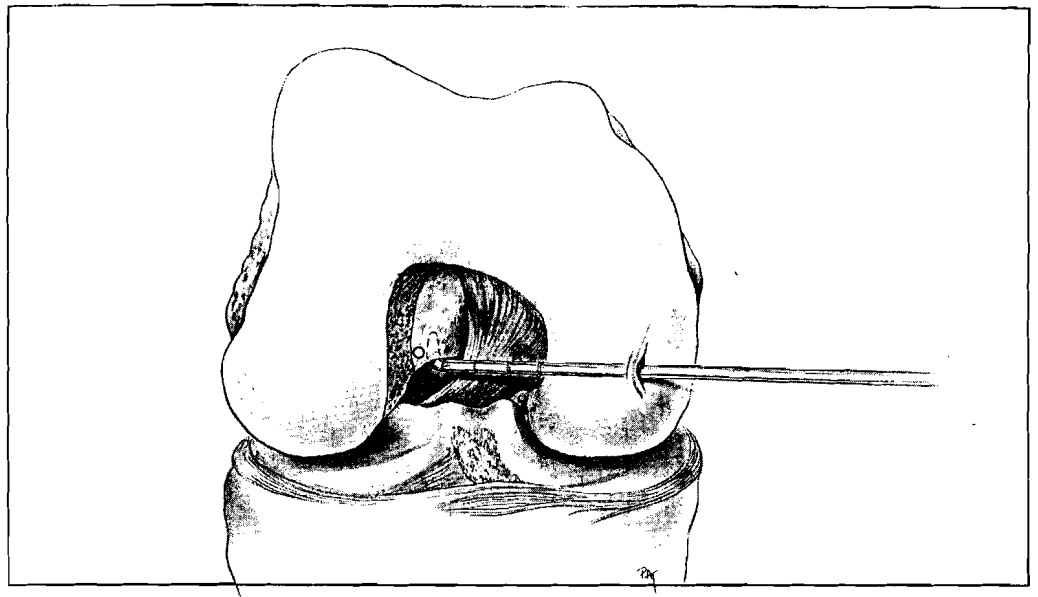


Fig. 4: Notchplasty is usually performed with a motorized burr progressing from anterior to posterior and to the anterior outlet.

Fig. 5: An arthroscopic probe is inserted to palpate the femoral condyle-posterior shaft transition which represents the over-the-top region.



a motorized arthroplasty unit (Fig. 3). The majority of the intercondylar notch preparation and notchplasty can be achieved with the 5.5 mm synovial resector, although the author also employs small and large motorized burrs.

Notchplasty

Notchplasty follows after ACL tissue debridement. The notchplasty aids arthroscopic visualization and protects the graft from abrasion. A notchplasty is performed carefully, progressing from anterior to posterior (Fig. 4). One must be careful not to misinterpret a ridge that occurs about two thirds of the way posteriorly as the "over-the-top" region. The notchplasty should be large enough to expose the intercondylar wall via the inferolateral portal. The size and shape of the notchplasty may be fine-tuned later, after the femoral drill hole has been made. The notchplasty includes debridement of additional tissue along the intercondylar wall.

The apex of the intercondylar notch requires particular attention. Many notches have a trefoil or cloverleaf configuration, especially in chronic ACL insufficiency where there may be intercondylar osteophytes that require debridement. Once the medial wall of the lateral femoral condyle has been thoroughly prepared to its posterior margin, one should be able to insert a probe from the inferomedial portal, in the over-the-top position

(Fig. 5). The position can be confirmed by placing the tip of the synovial resector over the top as well. While Clancy feels that the medial arthroscopic approach affords easier visualization of the intercondylar region,¹² many surgeons find inferolateral placement of the arthroscope adequate.

Patellar Tendon Graft Procurement

Following preparation of the intercondylar area including notchplasty, a 75 mm to 87.5 mm longitudinal skin incision is made 9.375 mm medial to the midline in the region of the patellar tendon (Fig. 6). The distal pole of the patella and the tibial tubercle are useful landmarks. Although a smaller incision can be made, precise graft harvesting requires adequate visualization. Harvesting can be performed with the tourniquet deflated up to the point that one is ready to use an oscillating micro-air saw.

The transversely-oriented fibers of the deep fascial layer are superficial to the patellar tendon tissue. This layer is reflected medially and laterally to identify the most medial and lateral edges of the patellar tendon. Proximal and distal measurements of patellar tendon width are recorded routinely to ensure accurate and reproducible graft size. Noyes has recommended 20 mm in width of graft tissue distally.⁵⁵ Although Erickson noted no patellar tendon ruptures in a review of more than 2,000 patellar tendon reconstructions, three patellar tendon ruptures after harvesting have been reported in the

Fig. 6: Surgical incisions for graft harvesting are noted. This 75 mm to 87.5 mm incision allows access to the patellar tendon and distally to place the tibial drill hole. The incision is placed 9.375 mm to 12.5 mm medial and longitudinally oriented (A). The lateral supracondylar incision is 62.5 mm long and in the mid-lateral line (B).

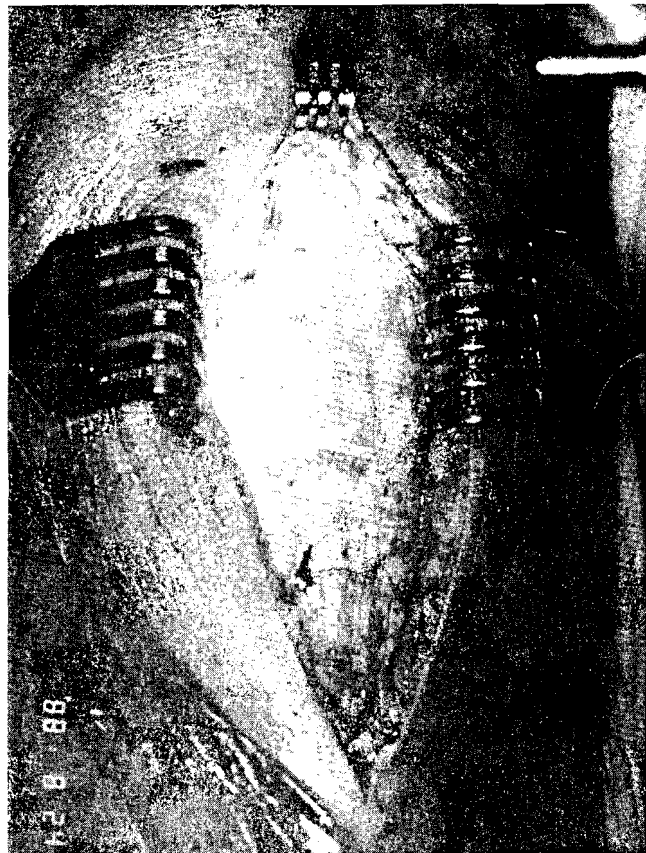


Fig. 6A.




Fig. 6B.

Fig. 7: Graft bone plugs are obtained with a small oscillating saw blade. The depth should not exceed 5 mm to 6 mm, and the saw should be angled 45° to create a wedge-shaped graft.

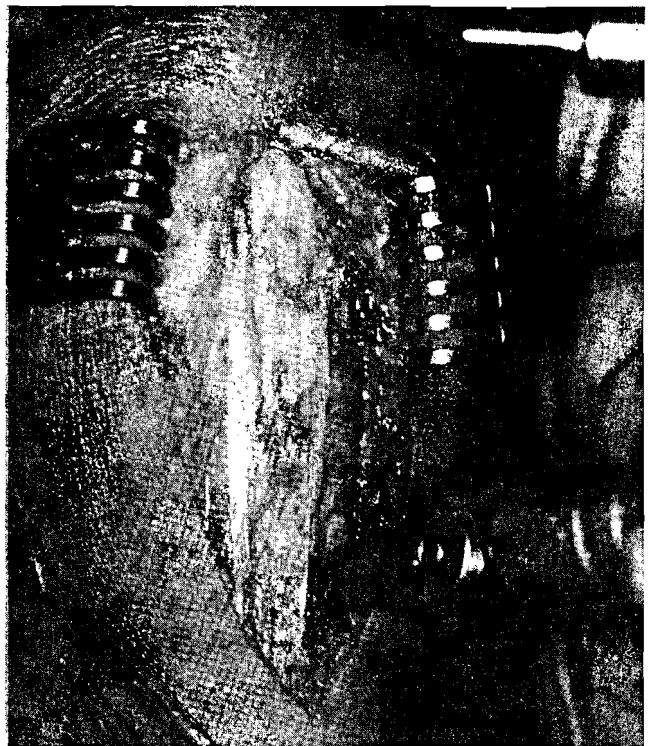


Fig. 7A.

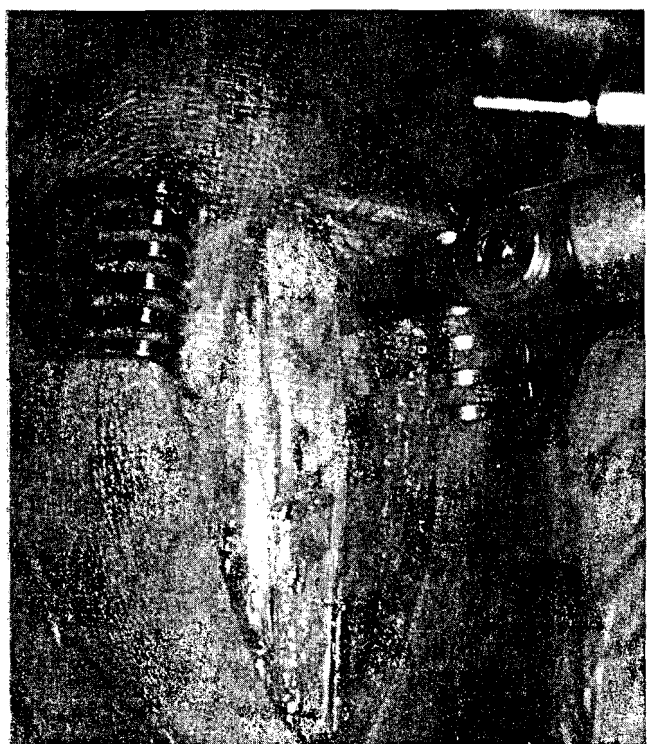


Fig. 7B.

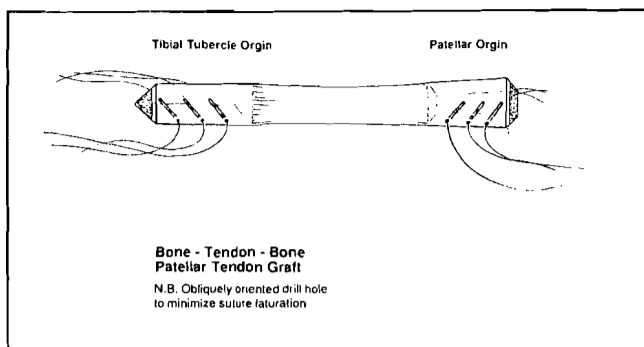


Fig. 8: A prepared graft is depicted. Edges are contoured to minimize incarceration. Drill holes are placed obliquely to avoid suture laceration. The patellar tendon is usually 45 mm \pm 3 mm in length. The tibial plug is 20 mm to 25 mm and the patellar bone plug is 20 mm to 25 mm. The entire construct is generally 85 mm to 95 mm long.

literature.^{9,45} It is important to record the dimensions of the tissues that are left in place in the operative report. The tibial tubercle and distal patella bone blocks are outlined sharply with a 15-blade scalpel. Templates are commercially available. On the tibial side, a 20 mm to 25 mm bone block is created, using an oscillating saw directed 45° to the sagittal and coronal planes. On profile, the tibial plug will be triangular in shape. On the patellar side, the longitudinal cuts are similarly directed at 45° to an approximate maximum depth of 5 mm to 6 mm. The transverse cut, completing the patellar block, is made at a 45° angle (Fig. 7). The grafts are lifted from their bone bed with a 12.5 mm to 18.75 mm curved osteotome. The fat pad is dissected from the patellar tendon with Metzenbaum scissors. If the fat pad itself is left intact, there should not be extravasation of irrigation fluid as a result of harvesting the patellar tendon segment.

The graft with bone blocks on either end is prepared (Fig. 8). Sharp bone edges must be contoured to facilitate passage through femoral and tibial holes. Three drill holes are made with a smooth 0.062 K-wire oblique to the cortical surface of the bone plugs, incorporating an edge of the cortex. Prior to the routine employment of the Kurosaka screw for interference fixation of the bone graft, drill holes are placed perpendicular to the cortex of the patellar and tibial bone plugs. However, if Kurosaka⁴² or AO screw interference fixation⁴³ is employed, the risk of suture laceration




Fig. 9: Sizing tubes of various widths are noted ranging from 8 mm to 12 mm. Generally, 10 mm to 12 mm sizing tubes are selected (Photograph courtesy of Acufex Microsurgical, Norwood, MA).

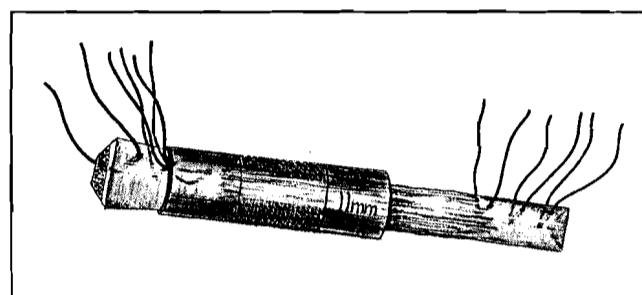


Fig. 10: The patellar plug has been contoured and wedges halfway on a sizing tube. This will allow impaction of the graft. The tibial plug must easily slide through the selected femoral sizing tube.

by the screw threads is possible. For this reason, the holes are oriented obliquely and spaced evenly within the plug. This allows suture placement through the bone blocks with Keith needles. Two sutures of #0 braided polyester are used through each hole. The tibial block will eventually be secured to the tibial side and the patellar block to the femoral side of the joint. Since the graft is brought from the femoral side, passed intraarticularly, and then into the tibial hole, the tibial block must slide easily through the femoral drill hole. The block is contoured to pass through an appropriate sized tube, (Acufex Microsurgical, Norwood, MA) measuring between 8 mm to 12 mm in diameter (Fig. 9). The tunnel is subsequently overdrilled by 1 mm to assure easy passage of the tibial block. The patellar block is lodged approximately halfway down a sizing tube (Fig. 10). Most tibial drill holes range from 10 mm to 11 mm and the majority of the




Fig. 11: A Chandler retractor reflects the vastus lateralis. The total supracondylar geniculate vessels must be identified and coagulated. Subperiosteal over-the-top dissection is performed.

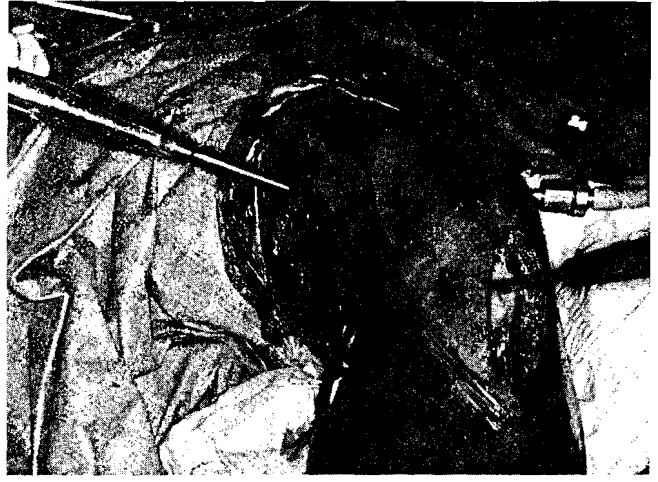

Fig. 12: The guide passer (Acufex Microsurgical, Norwood, MA) is inserted through a midpatellar portal. The surgeon's finger is placed posteriorly to palpate the tip before it is passed through the capsule.

Fig. 13: The appropriate side (left, right) rear-entry guide is inserted onto the eyelet of the guide passer (A), passed intraarticularly (B), and disengaged, and then the guide passer is removed (C).



Fig. 13A.

femoral holes range from 11 mm to 12 mm. Graft harvesting and preparation requires approximately 15 minutes.

Supracondylar Femur Preparation

Prior to or following graft harvesting and preparation, a 50 mm to 62.5 mm incision is made in the midline of the lateral supracondylar area of the femur, using the proximal pole of the patella as a

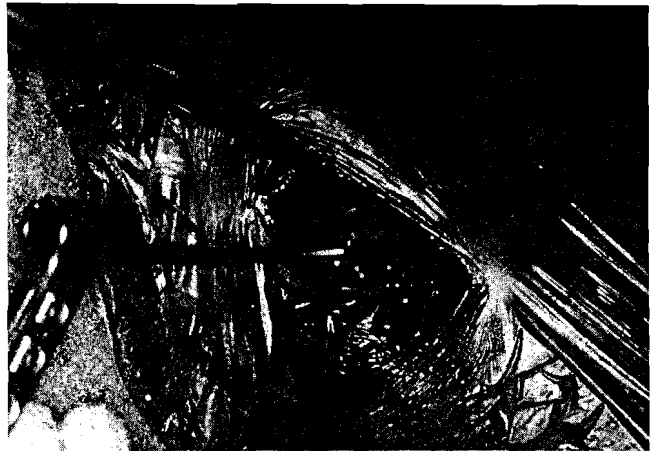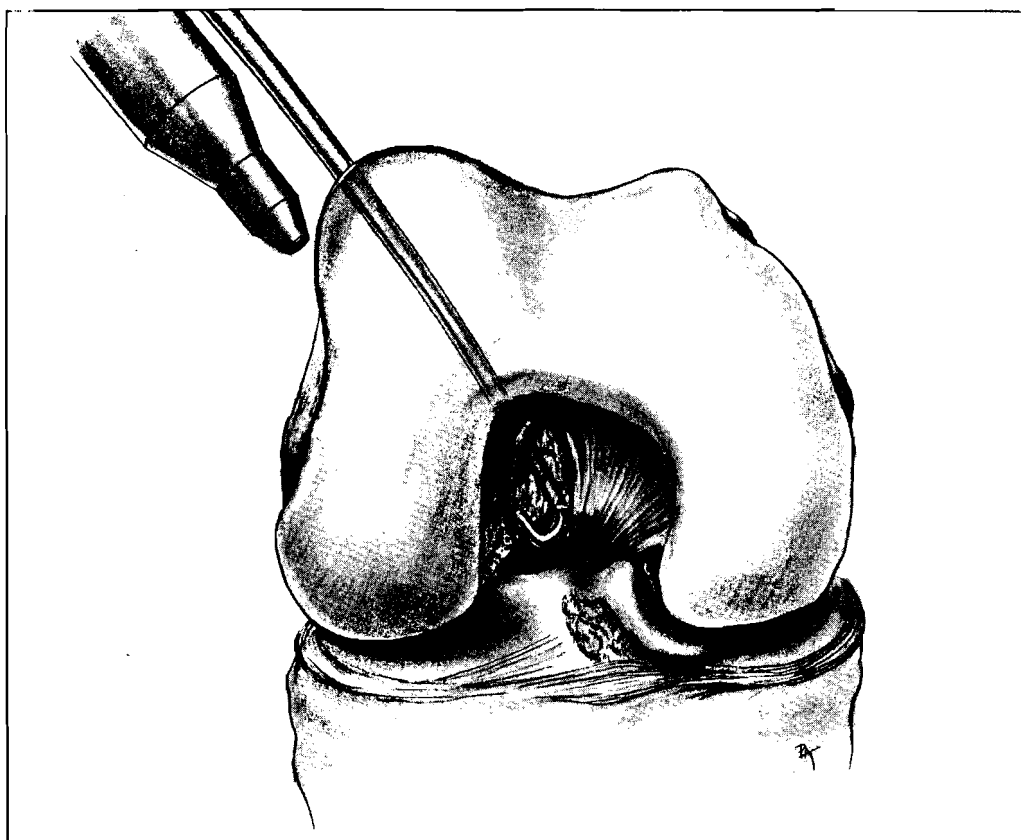


Fig. 13B.



Fig. 13C.

Fig. 14: The rear-entry guide eyelet is positioned at the 11-o'clock (right) or the 1-o'clock (left) position 3 mm to 4 mm from the posterior edge. When overdrilled, this will result in anatomic placement of the ACL substitute.



landmark. The iliotibial band is identified and divided parallel to its fibers for a similar length. The vastus lateralis is elevated from the intermuscular septum and retracted anteriorly with a Chandler retractor that rests on the anterior surface of the femur (Fig. 11). With the knee in about 45° of flexion, the lateral supracondylar geniculate vessels are identified and electrocoagulated. A longitudinal incision is made in perosteum with electrocautery followed by subperiosteal dissection over the top of the femoral condyle and posterior to the femoral metaphysis with a Cobb elevator. The surgeon should be positioned proximal to the knee at this point so that the periosteal elevator is directed posteriorly and distally towards the intercondylar region. After adequate dissection, one should be able to palpate the posterior intercondylar region under the posterior capsule. This step is necessary in order to pass either the right or left "rear entry guide system"⁶² (Acufex Microsurgical, Norwood, MA) to the desired site on the posterior joint. It has been found that most front-entry guide systems may be twisted during positioning or drilling with reduced accuracy.

Femoral Drill Hole Placement

The rear-entry guide system requires a mid-patellar anterior portal, through the rent in the patellar tendon, so that the J-shaped guide passer can be introduced through the knee joint, from the front, to facilitate passage of the rear-entry guide (Fig. 12). The guide passer is visualized in the joint with the arthroscope and placed in the over-the-top position. The surgeon places a finger in the over-the-top position from behind the knee to palpate the tip of the guide passer before it penetrates the posterior capsule. This allows the rear-entry guide to be easily introduced (Fig. 13) and positioned, under arthroscopic visualization, approximately 4 mm anterior to the over-the-top position (either the 1-o'clock position for left knee, or the 11-o'clock position for right knee) (Fig. 14). Prior to drilling the Steinmann pin through the femur, probing is routinely necessary to confirm its entry position relative to the over-the-top region. The entrance site of the Steinmann pin on the lateral supracondylar region should be approximately 4 cm proximal to the lateral epicondyle slightly posterior to the mid-lateral line of the femoral metaphysis. A 2.3 mm

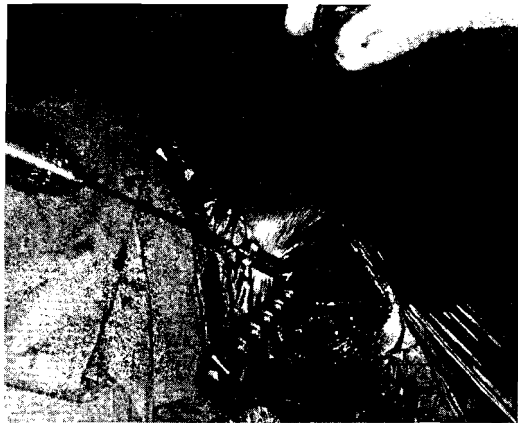

Fig. 15A.

Fig. 15: A threaded Steinmann pin is drilled (A) and its intraarticular entrance is documented arthroscopically. An arthroscopic probe may be placed over the top to assess its placement (B).

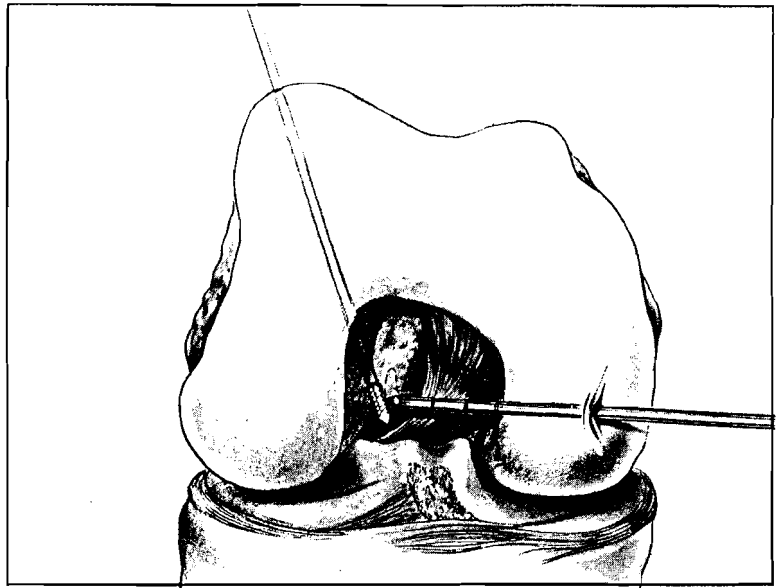


Fig. 15B.

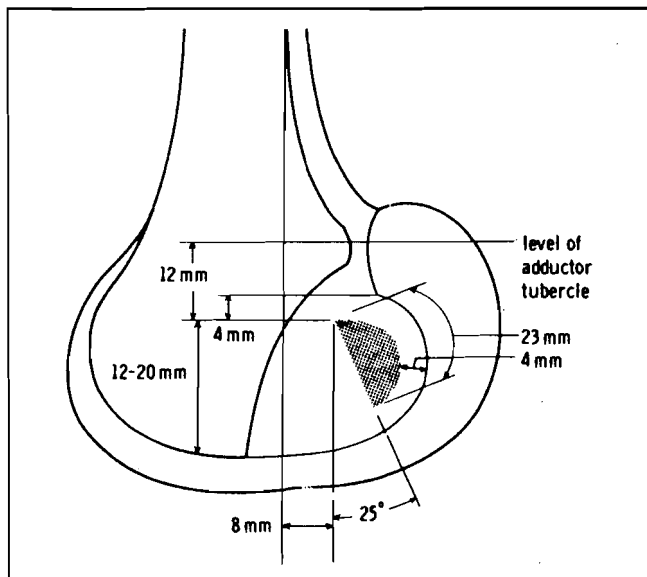


Fig. 16: Anatomic studies have demonstrated the normal origin and insertion sites of the ACL (Reprinted from *Clinical Orthopaedics and Related Research* 1975; 106:218).

threaded Steinmann pin is then placed on the entrance site and drilled from outside into the knee under arthroscopic visualization. Its placement in the over-the-top region is verified using a probe (Fig. 15).

Tibial Hole Placement

Arthroscopic instruments are removed, and the knee is flexed into the "figure four" position. The

skin edges of the tibial incision are retracted to expose the medial metaphysis of the proximal tibia. The anatomic landmarks for the tibial drill hole extraarticular entrance site define a triangle bound by the medial edge of the patellar, the medial third of the patellar tendon laterally, the distal aspect of pes anserinus inferiorly (which can be palpated and has a rubbery sensation on palpation), and the superficial medial collateral ligament medially.

The original ACL insertion site is broad, spanning approximately 2.5 cm to 3.0 cm on the intercondylar eminence region. A 1.5 cm × 2.0 cm osteoperiosteal flap, based medially, is then created with electrocautery and a Cobb elevator. The normal ligament anatomic attachment sites have been well described by Girgis,²⁵ Odensten,⁵⁹ and Norwood^{52,53} (Fig. 16).

The arthroscope is replaced in the inferolateral portal to visualize the tibial eminence. The arthroscope should be rotated and directed anteromedially. The site for intraarticular placement of the K-wire is bound by the medial aspect of the intercondylar eminence, the anterior outlet of the intercondylar notch, and the posterior edge of the anterior horn of the medial meniscus. A site 1 mm to 2 mm lateral to the medial base of the intercondylar eminence is selected, and this should be in a line dropped from the perpendicular from the anterior outlet (Fig. 17). The hole is drilled at an angle



Fig. 17A.

Fig. 17: The tibial drill site is anterior and medial to the center of the former tibial insertion site (A). When overdrilled, graft placement should then be centered in the former ACL's central region. The medial tibial eminence and the notch outlet are guidelines for drill hole placement (B).

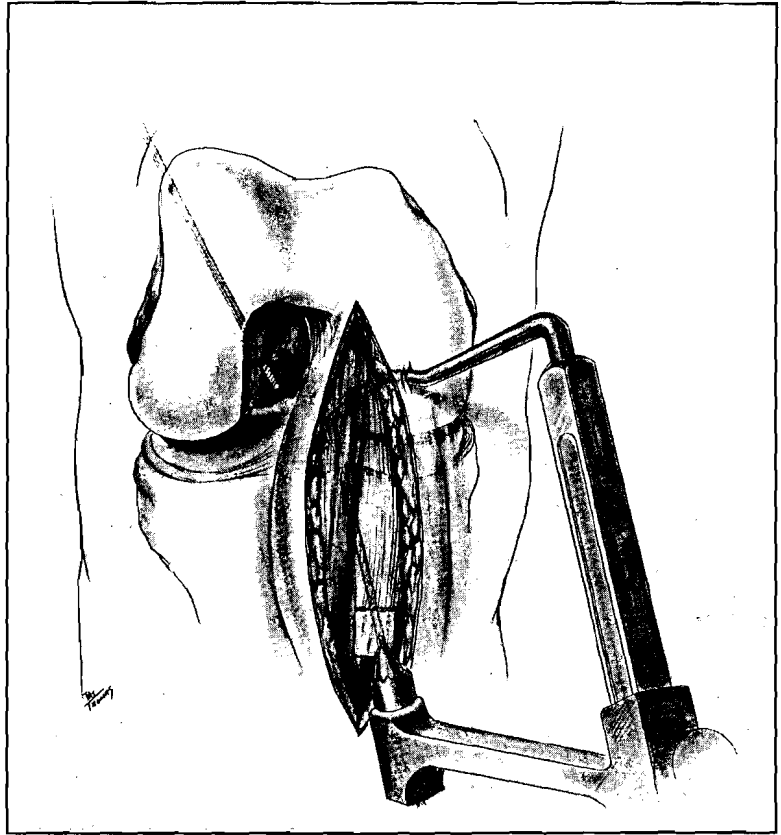
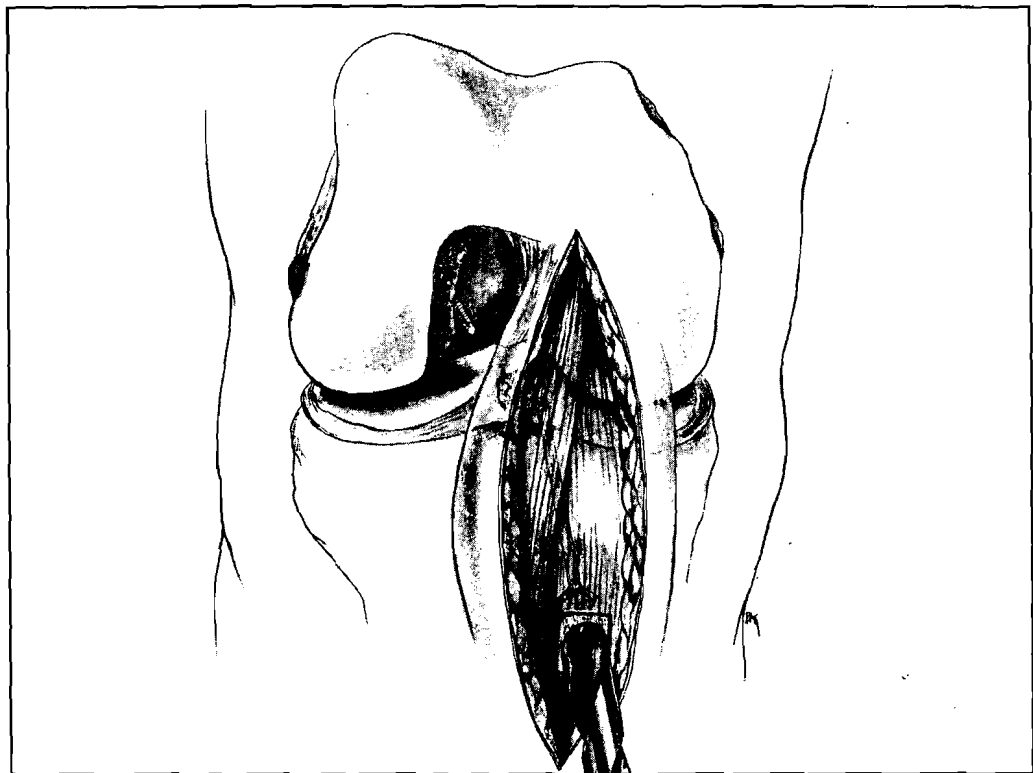


Fig. 17B.

Fig. 18: An appropriately placed Steinmann pin is overreamed.



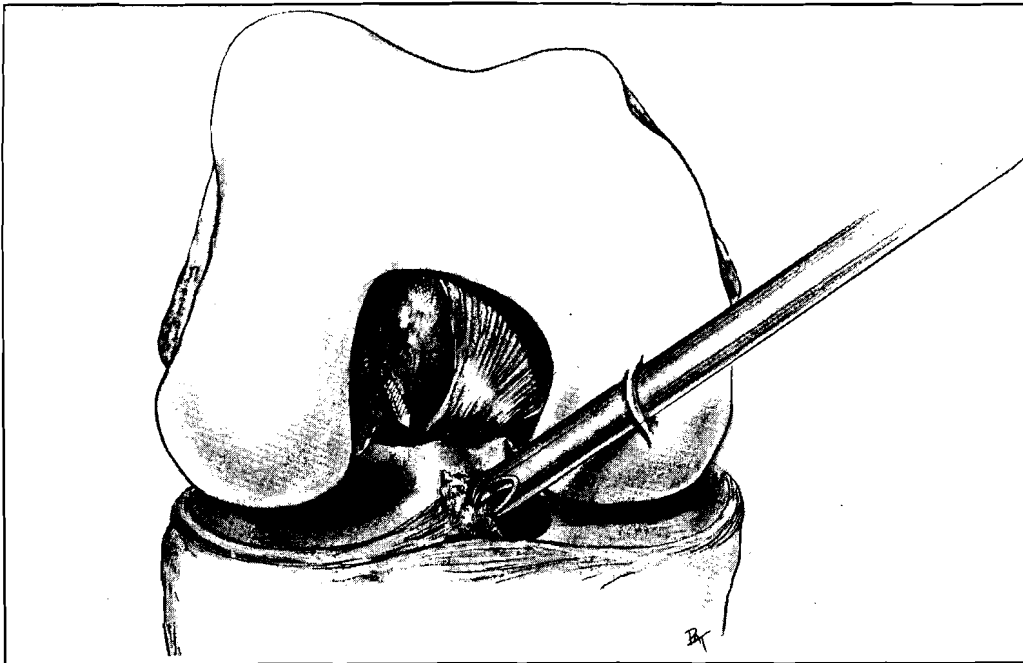


Fig. 19: A synovial resector, burr, and/or arthroscopic rasp is inserted through the tibial drill tunnel to contour the posterior and posterolateral corners. The inferomedial portal is also utilized.

approximately 30° from the sagittal plane such that, when overdrilled, it will be in the center of the previous insertion of the ACL. A ligament-guide system is used to create the tibial tunnel (Acufex Microsurgical, Norwood, MA). As noted, the intercondylar landmarks for placement of the tibial drill hole include the medial eminence of the tibia, as well as the anterior outlet of the intercondylar region. A 2.34 mm K-wire is drilled to exit slightly anterior and medial to the center of the original ACL insertion into the tibial eminence region. The rationale for this is that, as the drill hole is obliquely oriented from the sagittal and coronal planes, the graft will be oriented posterolaterally in its orientation towards the femoral attachment site. If one were to place the K-wire in the anatomic center, then after using the cannulated reamer to enlarge this hole, the graft would be placed posterolateral to the original insertion center.

Prior to placement of the front-entry-guide stylet slightly lateral to the medial edge of the intercondylar eminence, it is helpful to use a small, motorized burr as a set point to minimize stylet migration. With the knee flexed approximately 30°, the drill guide is secured to the tibial metaphysis, making certain that the guide pin will not enter the tibia too proximally, leaving a bone bridge and tunnel that is too short to secure the graft. A threaded

Steinmann pin is then drilled from the proximal tibia into the joint under arthroscopic visualization. If there is any error in the position of the hole in the joint, it is usually because the pin enters too far laterally. This error would be compounded later by overreaming the tunnel. The position should be perfect. With the K-wire properly placed, a cannulated drill is used for overreaming (Fig. 18). The posterior edge of the tunnel and intraarticular soft tissues are debrided with a motorized synovial resector that is introduced alternately through the inferomedial portal and tibial tunnel (Fig. 19). An arthroscopic rasp is introduced through the tunnel to smooth the intraarticular opening and eliminate points of high stress on the graft. The hole is temporarily occluded to minimize fluid extravasation.

Isometry Testing

The K-wire in the lateral femoral condyle is removed and replaced under direct vision by a 22 gauge wire loop. The loop is positioned in the knee and grasped, under arthroscopic visualization, with an instrument that had been inserted through the inferomedial portal. The wire loop is brought through the tibial tunnel and out through the anterior tibia. The wire is secured proximally with a hemostat so that it will not slip through the joint. A suture, previously positioned through a strain

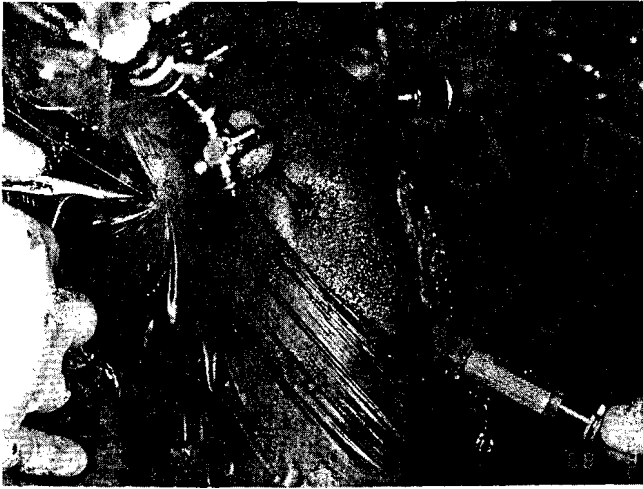


Fig. 20: The strain gauge (Graf-Clancy, Acufex Microsurgical, Norwood, MA) is demonstrated.

gauge²⁹ (Fig. 20) (Graf-Clancy, Acufex Microsurgical, Norwood, MA), is attached to the wire loop and drawn back through the tibia, the joint, and then the femur (Fig. 21). The suture is secured on the lateral supracondylar region of the femur hole by a straight hemostat. The strain gauge is secured to the hole on the tibial metaphysis, making certain that the knee is not translated anteriorly (Fig. 21). The knee is extended from 90° to 0°, noting the excursion on the strain gauge. If excursion exceeds 2.5 mm, one should inspect the joint with the arthroscope to explain and remedy the possible non-isometric position of the graft. The suture must not impinge on either tibial or femoral tunnels. Also, tibial rotation that increases anterior tibial translation must not exist. The posterior edge of the tibial tunnel may be contoured with a motorized shaver to minimize cantilevering of the suture. The femoral hole may require redrilling.

When the strain gauge reads less than 2.5 mm, the suture attached to it may be replaced in the femoral drill hole by a thinner, 0.062 K-wire that is gently tapped into place with a mallet. The hole should not be redrilled, nor should the K-wire be reinserted with a drill for fear of losing the orientation of the original hole. Once this is visualized arthroscopically, an arthroscopic osteotome or curette is inserted through the anteromedial portal to protect the posterior cruciate ligament. A smaller cannulated reamer (7 mm to 8 mm) is used to initiate a hole in the outer cortex. The appropriate

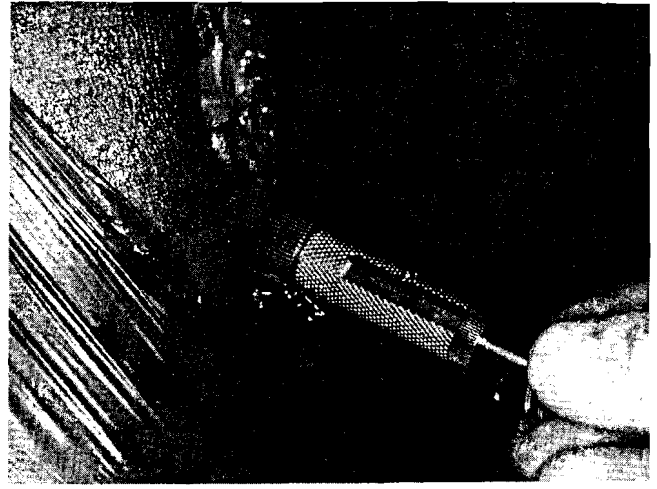


Fig. 21: The strain gauge is positioned and the knee is flexed between 0° and 90°. Excursion is noted. An acceptable reading is currently ≤ 2.5 mm.

sized cannulated reamer, as determined by prior graft preparation and sizing, is used to complete the hole (Fig. 22). Once the drill has passed intraarticularly, it is removed. A finger placed over the lateral supracondylar hole minimizes fluid extravasation and a synovial resector or motorized burr is used to contour the inner edge of the intraarticular region of the femoral drill hole (Fig. 23). Particular attention must be directed towards the most superior and lateral aspects of this hole as this is where the graft may impinge. At this point, a more aggressive notchplasty may be performed if needed.

A Yankauer tube is passed from the tibial tunnel into the joint and then into the femoral tunnel (Fig. 24).⁶⁴ The tube, clamped and held against the cortex of the femur, can be used as an artificial ligament to assess isometricity and position in the intercondylar region. Additionally, one may perform Lachman, anterior drawer, and pivot-shift tests to evaluate stability. The suction tube is cut and can be used as a conduit to pass two wire loops through the joint. These should be clamped on each end with curved and straight hemostats to identify each wire loop; the suction tube is then removed.

Graft Placement

The central third, free bone-ligament-bone graft is ready for placement. It will be admitted from the femoral side, through the joint and into the tibial tunnel where it will be secured on the tibial meta-

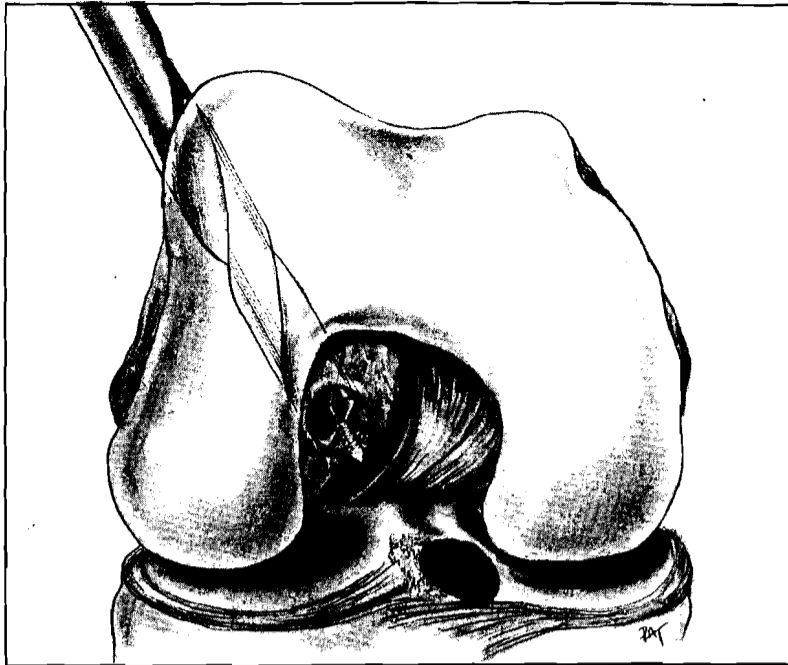


Fig. 22A.




Fig. 22B.

Fig. 22: The femoral guide wire has been replaced. Its position has been confirmed intraarticularly. A cannulated drill is used to create the femoral drill hole.

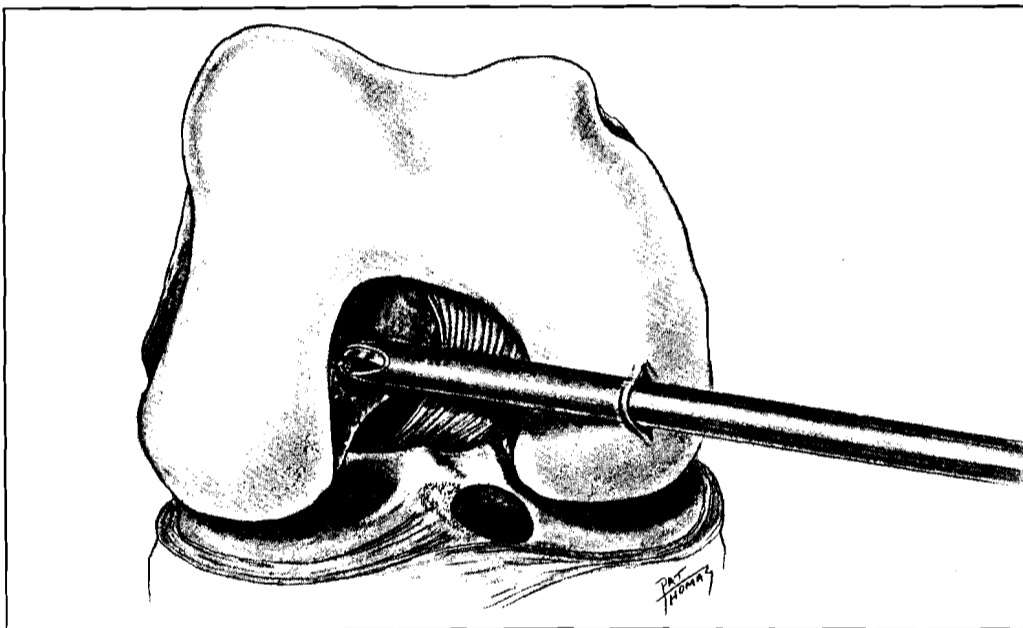


Fig. 23: The inner edges superiorly and superolaterally are contoured to minimize graft abrasion with a synovial resector.

physis (Fig. 25). The graft must be held securely by at least one individual at all times. An arthroscopic osteotome is used to spread the loop in the wire that is situated in the joint. The sutures, previously threaded through holes in the graft tibial bone block, can now be passed as two groups.

Under direct arthroscopic vision, the tibial bone block of the graft is brought through the femoral

tunnel, across the joint and out through the tibial tunnel. The tibial block may require guiding with an arthroscopic elevator or probe because the adjacent posterior cruciate ligament, intercondylar eminence, and lateral wall may obstruct its passage. With tension applied to both sides of the graft, one can insert an arthroscopic probe through the inferomedial portal to assess the tension on the

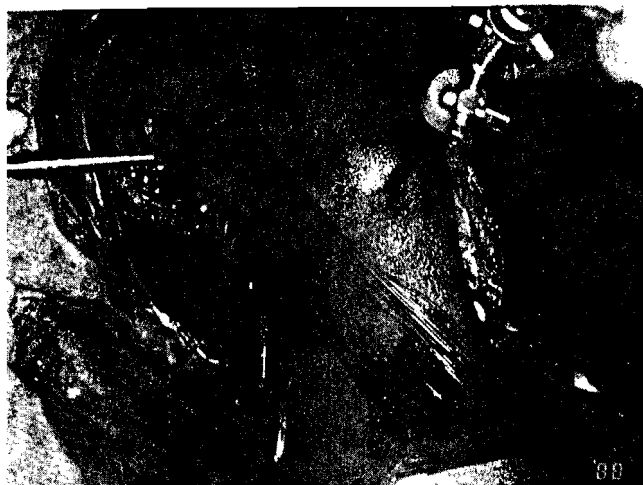


Fig. 24: A suction tube is passed retrograde. It may be clamped and tested as an artificial ligament to assess isometricity and lateral or anterior impingement.

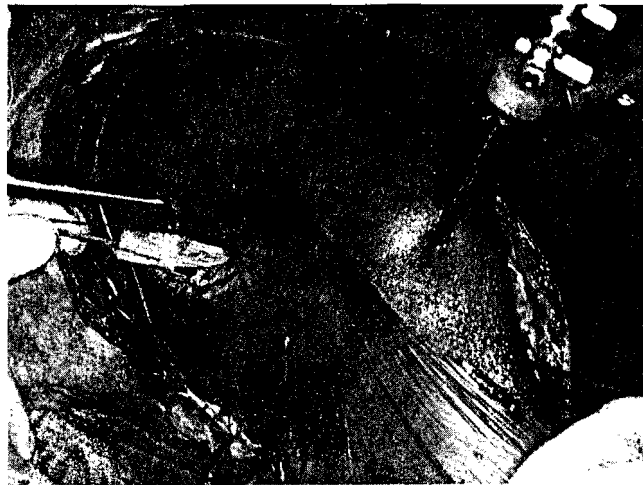

Fig. 25: A bone-ligament-bone construct is positioned from the femoral side, intraarticularly, and into the tibial tunnel.

ligament. Laxity implies that the graft may be incarcerated within the tibial tunnel. If so, the tibial bone block of the graft should be pushed back into the joint and the tibial hole enlarged slightly with a synovial resector or burr. Tension on the ligament can be assessed by alternately pulling on the sutures, or relaxing them and palpating the ligament in the joint with a probe under arthroscopic visualization. Orientation and tension of the new ligament must also be assessed in full knee extension, looking for impingement of the graft on the wall of the lateral femoral condyle and the anterior outlet in particular.

There are a variety of devices available for securing the graft once position and tension are correct. Ligament buttons, various staples, sutures tied over a unicortical screw and post, and interference screw-fixation techniques have been described. In the United States, Lambert has popularized the use of an AO 6.5 mm cancellous screw which is introduced into the tunnels to provide an interference fit that increases bone plug-tunnel contact and enhances union.⁴³

Recently, Kurosaka described a self-tapping screw that provides interference fixation. It is available in 20 mm, 25 mm, and 30 mm lengths and in 7 mm and 9 mm widths (DePuy Co, Warsaw, IN) (Fig. 26). There are advantages to the Kurosaka screw with regard to linear load resistance, stiffness, and maximum tensile strength as opposed to fixation

with ligament buttons, staples, screws, or AO interference techniques.⁴² However, several problems may occur with interference screw fixation, including graft-screw length mismatch, tunnel-graft-screw mismatch, tunnel-screw divergence, graft advancement, graft translocation, graft fracture, and suture laceration of the graft block.⁴ If the screw is longer than the tibial or patellar bone plugs, the screw tip can abrade the new ligament. To minimize the possibility of intraarticular placement of the screw tip, the Kurosaka screw is routinely placed in the anterior aspect of the tibial tunnel against the cortical surface of the graft's tibial bone block. This region is inspected arthroscopically to avoid intraarticular screw penetration and graft abrasion.

A long femoral bone tunnel is not a problem. However, if the bone tunnel is too narrow relative to the size of the graft, it can be difficult for the screw to seek its own pathway. The screw may thus diverge from the tunnel so that fewer threads contact the bone block, thus reducing fixation. The tibial tunnel is routinely overdrilled by 1 mm so that the plug will slide easily and the Kurosaka screw can be easily inserted. There is a chance of graft bone block or tibial or femoral fracture if the relative size of the graft to the tunnel is reduced. Graft advancement by the screw may result if the tibial tunnel is too narrow relative to the graft.

Finally, oblique drill holes through the tibial and




Fig. 26: Kurosaka screws are available in two widths (7 mm and 9 mm) and three lengths (20 mm, 25 mm, and 30 mm). Usually, the length selected matches the length of the graft (Photograph courtesy of DePuy Co, Warsaw, IN).

femoral blocks minimize the chance of suture laceration as the screw is inserted against the cortical surface of the bone blocks. As the screw is inserted, the graft is compressed against the opposite side of the tunnel. This can be used to correct slight abnormalities in the strain gauge readings by altering the orientation of the graft. The cortical surface of the tibial plug is routinely placed anteriorly (Fig. 27). On the femoral side, the cortical surface of the bone plug faces laterally so that the screw will translate the graft medially, but neither anteriorly nor posteriorly, so that the isometry is not affected.

Once the screws have been inserted, the graft is examined and palpated with a probe under arthroscopic visualization to assess tension. The knee is brought through a range of motion to determine if further notchplasty is required. A Lachman test should demonstrate 2 mm to 3 mm of translation and a firm end point. The pivot-shift test should be normal.

The tourniquet is released. In general, meniscal surgery and notchplasty will have been performed with the tourniquet deflated. Notch preparation and notchplasty may take 15 to 20 minutes. Tourniquet time can be limited to about 70 minutes if the tourniquet is not inflated until the skin incision is made for patellar tendon harvesting. If it is inflated at the beginning of the procedure, the total time may be from 1 hour 40 minutes to 2 hours. Time becomes important, particularly if meniscal repair is required. However, if necessary, ACL reconstruction can be performed without tourniquet inflation. With the tourniquet released, meticulous hemo-

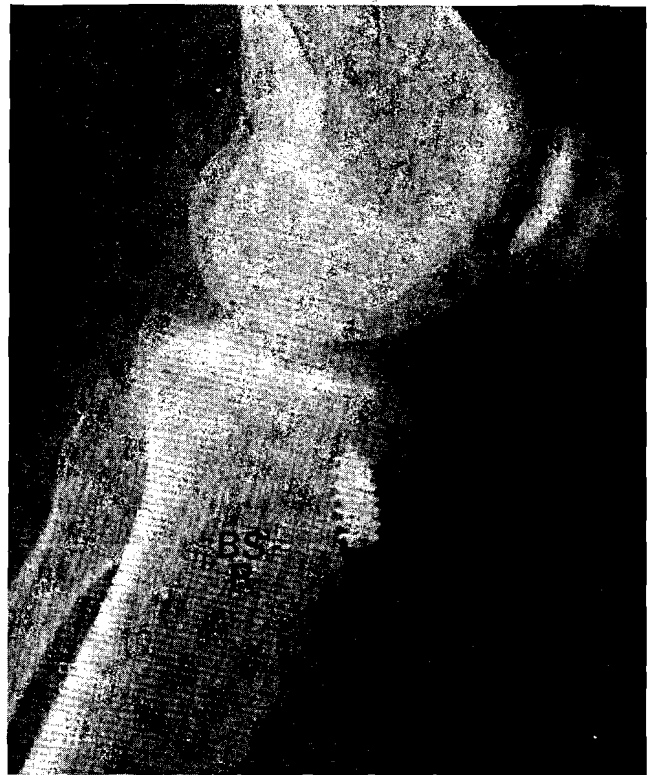


Fig. 27: Radiograph demonstrates placement of Kurosaka screws on the femoral and tibial sides. Note the cortical edge of the tibial plug is facing anteriorly. The interference screw compresses the opposing cancellous bone to assure union. The screw also will translocate the graft to the opposite side of the bone tunnel.

stasis is achieved. In particular, vessels in the lateral supracondylar region and the proximal tibial metaphysis require attention. The osteoperiosteal flap should be closed over the tibial plug. Gelfoam (Upjohn Co, Kalamazoo, MI) is placed in the bone plug sites to minimize bleeding. A hemovac is not used unless necessary. The patellar tendon rent and the iliotibial band are closed with interrupted sutures. Extraarticular iliotibial band augmentation tenodesis is not employed, in order to leave the iliotibial band intact as a dynamic stabilizer.

Open patellar tendon substitution for anterior cruciate ligament procedures has shown no statistical difference with regard to clinical stability, failure, or KT 1000 arthrometer evaluation, whether extraarticular augmentation is performed or not.^{57,58}

Subcutaneous tissue is closed with an inverted Vicryl (polyglactin) suture; the skin, with a running subcuticular sliding nylon; and the arthroscopic portals, with interrupted nylon. Sterile dressings

are applied and the patient is placed in a hinged-knee orthosis, allowing 10° to 90° of motion. The patient, maintained in a continuous passive motion machine and hinged-knee brace, is hospitalized from two to three days. A standard rehabilitation protocol for anterior cruciate ligament rehabilitation is enforced.

Arthroscopy-assisted ACL reconstruction using a central third, bone-ligament-bone, autogenous patellar tendon graft has been an exciting addition to the treatment of anterior cruciate ligament insufficiency. This procedure, used routinely at the author's institution, avoids arthrotomy and allows early range of motion. Clinical assessment by KT-1000 and physical examination has demonstrated excellent restoration of knee ligament stability. The operative procedure gives predictably excellent results with minimal morbidity. The procedure is, however, demanding and requires careful patient selection, meticulous surgical execution, and rigorous postoperative rehabilitation.

References

1. Anderson AF, Lipscomb AB, Liudahl KJ, et al: Analysis of the intercondylar notch by computed tomography. *Am J Sports Med* 1987; 15:547-552.
2. Arnoczky SP, Warren RF: Microvasculature of the human meniscus. *Am J Sports Med* 1982; 10:90-95.
3. Arnoczky SP, Warren RF: The microvasculature of the meniscus and its response to injury: An experimental study in the dog. *Am J Sports Med* 1983; 11:131-141.
4. Bach BR: Potential pitfalls of Kurosaka interference screw fixation in ACL reconstruction. *The American Journal of Knee Surgery*, in press.
5. Bach BR Jr, Flynn W, Warren RE, et al: KT 1000 arthrometer evaluation of normal, acute, and chronic anterior cruciate ligament patients. Transactions of the 33rd Annual Meeting, Orthopedic Research Society 1987; 12:194.
6. Bach BR, Mikosz RP, Andriacchi TP: The influence of changing femoral attachment positions on force displacement characteristics of the anterior cruciate ligament. *Orthopaedic Transactions* 1988; 13:129.
7. Bach BR, Warren RF: The empty wall sign of ACL insufficiency. *Arthroscopy*, in press.
8. Bach BR Jr, Warren RF, Wickiewicz TL: Observations on the effects of the hip and foot position on the pivot shift phenomenon. *Am J Sports Med* 1987; 15:626-627.
9. Bonamo JJ, Krinick RM, Sporn AA: Rupture of the patellar ligament after use of its central third for anterior-cruciate reconstruction. *J Bone Joint Surg* 1984; 66A:1294-1297.
10. Bruchman WC, Bain JR, Bolton CW: Prosthetic replacement of the cruciate ligaments with expanded polytetrafluoroethylene, in Feagin JA (ed): *The Crucial Ligaments*. New York, Churchill Livingstone, 1988, pp 507-515.
11. Caspari RB, Meyers JF, Whipple T: A technique for arthroscopic of the anterior cruciate ligament. *Contemporary Orthopaedics* 1986; 12(3):49-57.
12. Clancy WG Jr: Arthroscopic anterior cruciate ligament reconstruction with patellar tendon, in Dorr L (ed): *Techniques in Orthopaedics*. Frederick, MD, Aspen Publishers, 1988, pp 13-22.
13. Clancy WG Jr: Intraarticular reconstruction of the anterior cruciate ligament. *Orthop Clin North Am* 1985; 16(2): 181-189.
14. Clancy WG Jr, Graf BK: Arthroscopic meniscal repair. *Orthopedics* 1983; 6:1125-1129.
15. Clancy WG Jr, Nelson DA, Reider B, et al: Anterior cruciate ligament reconstruction using one third of the patellar tendon augmented by extraarticular tendon transfers. *J Bone Joint Surg* 1982; 64A:352-359.
16. Clancy WG Jr, Ray MR: Anterior cruciate ligament autografts, in Jackson DW, Drez D (eds): *The Anterior Cruciate Deficient Knee*. St Louis, CV Mosby Co, 1987, p 202.
17. Clancy WG Jr, Thomsen E, Dueland RT, et al: Anterior cruciate and posterior cruciate ligament reconstruction with patellar tendon utilizing a medial vascularized graft, lateral vascularized graft, and free patellar tendon graft. *Orthopaedic Transactions* 1987; 12:70.
18. Daniel DM, Malcom LL, Losse G, et al: Instrumented measurement of anterior laxity of the knee. *J Bone Joint Surg* 1985; 67A:720-726.
19. DeHaven KE: Meniscus repair: Open vs arthroscopic. *Arthroscopy* 1985; 3:173-174.
20. DeHaven KE: Peripheral meniscal repair: An alternative to meniscectomy. *Orthopaedic Transactions* 1981; 5:399-400.
21. Fowler PJ: Techniques using braided polypropylene as a ligament augmentation device, in Dorr L (ed): *Techniques in Orthopaedics*. Frederick, MD, Aspen Publishers, 1988, pp 81-85.
22. Friedman MJ: Arthroscopic semitendinosus (Gracilis) reconstruction for anterior cruciate ligament deficiency, in Dorr L (ed): *Techniques in Orthopaedics*. Frederick, MD, Aspen Publishers, 1988, pp 74-80.
23. Friedman MJ: Gore-Tex anterior cruciate ligament reconstruction, in Dorr L (ed): *Techniques in Orthopaedics*. Frederick MD, Aspen Publishers, 1988, pp 36-43.
24. Gillquist J, Odensten M: Arthroscopic reconstruction of the anterior cruciate ligament. *Arthroscopy* 1988; 4(1):5-9.
25. Girgis FG, Marshall JL, Al Monajem ARS: The cruciate ligaments of the knee joint: Anatomical function and experimental analysis. *Clin Orthop* 1975; 106:216-231.
26. Goble EM: Fluoroarthroscopic allograft anterior cruciate reconstruction, in Dorr L (ed): *Techniques in Orthopaedics*. Frederick, MD, Aspen Publishers, 1988, pp 65-73.
27. Gollehan DL, Torzilli PA, Warren RF: The role of the posterolateral and cruciate ligaments in the stability of the knee. *J Bone Joint Surg* 1987; 69A:233-241.
28. Gomes JLE, Marczyk LRS: Anterior cruciate ligament reconstruction with a 'loop' or double thickness of semitendinosus tendon. *Am J Sports Med* 1984; 12:199-203.
29. Graf B: Isometric placement of substitutes for the anterior cruciate ligament, in Jackson DW, Drez D (eds): *The Anterior Cruciate Deficient Knee*. St Louis, CV Mosby Co, 1987, pp 55-71.
30. Grood ES, Stowers SF, Noyes FR: Limits of movement in

- the human knee effect of sectioning the posterior cruciate ligament and posterolateral structures. *J Bone Joint Surg* 1988; 70A:88-97.
31. Henning CE, Lynch MA, Jelly BL, et al: Arthroscopic meniscal repair. Presented at the AOSS Meeting, Anaheim, CA, August, 1984.
 32. Hill JA: Autograft, xenograft, and synthetic cruciate ligament reconstruction: State of the art, in Parisien JS (ed): *Arthroscopic Surgery*. New York, McGraw Hill, 1988, pp 205-212.
 33. Houseworth SW, Mauro VJ, Mellon BA, et al: The intercondylar notch in acute tears of the anterior cruciate ligament: A computer graphics study. *Am J Sports Med* 1987; 15:221-224.
 34. Jackson DW, Reiman PR: Principles of arthroscopic anterior cruciate reconstruction, in Jackson DW, Drez D (eds): *The Anterior Cruciate Deficient Knee*. St Louis, CV Mosby Co, 1987, pp 273-285.
 35. Jakob RP, Stäubli HU, Zuber K, et al: The arthroscopic meniscal repair: Techniques and clinical experience. *Am J Sports Med* 1988; 16:137-142.
 36. Johnson LL: Extrasynovial conditions, in Johnson LL (ed): *Arthroscopic Surgery*, ed 3. St Louis, CV Mosby Co, 1986, pp 1101-1238.
 37. Johnson LL: Second look arthroscopy and biopsy: Double loop semitendinosus ACL grafting. Presented at the ACL Study Group, Snowmass, CO, March 1988.
 38. Jones KG: Reconstruction of the anterior cruciate ligament: A technique using the central third of the patellar ligament. *J Bone Joint Surg* 1963; 45A:925-932.
 39. Jones KG: Reconstruction of the anterior cruciate ligament using the central one third of the patellar ligament: A follow up report. *J Bone Joint Surg* 1970; 52A:1302-1308.
 40. Kieffer DA, Houseworth SW, Mauro VJ, et al: Anterior ligament tears, intercondylar notch relationship proposed. *Orthopedics Today* 1986; 6(1):1.
 41. Kieffer DA, Lurnow RJ, Southwell RB, et al: Anterior cruciate ligament arthroplasty. *Am J Sports Med* 1984; 12:301-312.
 42. Kurosaka M, Yoshiya S, Andrish JT: A biomechanical comparison of different surgical techniques of graft fixation in anterior cruciate ligament reconstruction. *Am J Sports Med* 1987; 15:225-229.
 43. Lambert KL: Vascularized patellar tendon graft with rigid internal fixation for anterior cruciate ligament insufficiency. *Clin Orthop* 1983; 172:85-89.
 44. Lambert KL, Cunningham RR: Anatomic substitution of the ruptured ACL using a vascularized patellar tendon graft with interference fit fixation, in Feagin JA (ed): *The Crucial Ligaments*. New York, Churchill Livingstone, 1988, pp 401-408.
 45. Langan P, Fontanetta AP: Rupture of the patellar tendon after use of its central third. *Orthopaedics Review* 1987; 16:317-321.
 46. Malcom LL, Daniel DM, Stone ML, et al: The measurements of anterior knee laxity after ACL reconstruction. *Clin Orthop* 1985; 196:35-41.
 47. McCarroll JR: Fracture of the patella during a golf swing following reconstruction of the anterior cruciate ligament. *Am J Sports Med* 1983; 11:26-27.
 48. Melhorn JM, Henning CE: The relationship of the femoral attachment site to the isometric tracking of the anterior cruciate ligament graft. *Am J Sports Med* 1987; 15:539-542.
 49. Miller DB: Arthroscopic meniscus repair. *Am J Sports Med* 1988; 16:315-320.
 50. Morgan CD, Casscells SW: Arthroscopic meniscus repair: A safe approach to the posterior horns. *Arthroscopy* 1986; 2:3-12.
 51. Moyer RA, Betz RR, Iaquinto J, et al: Arthroscopic anterior cruciate ligament reconstruction using the semitendinosus and gracilis tendons: Preliminary report. *Contemporary Orthopaedics* 1986; 12(1):17-26.
 52. Norwood LA, Cross MJ: Anterior cruciate ligament functional anatomy of its bundles in rotatory instabilities. *Am J Sports Med* 1979; 7:23-26.
 53. Norwood LA, Cross MJ: The intercondylar shelf and the anterior cruciate ligament. *Am J Sports Med* 1977; 5:171-176.
 54. Noyes FR: Where we are in 1987 with cruciate surgery. Presented at the American Orthopedic Society for Sports Medicine Annual Meeting, Orlando, FL, June 1987.
 55. Noyes FR, Butler DL, Grood ES, et al: Biomechanical analysis of human ligament grafts used in knee ligament repairs and reconstructions. *J Bone Joint Surg* 1984; 66A:344-352.
 56. Noyes FR, Butler DL, Paulos LE, et al: Intraarticular cruciate reconstruction. Part I: Perspectives on graft strength, vascularization and immediate motion after replacement. *Clin Orthop* 1983; 172:71-77.
 57. O'Brien SJ, Warren RF, Wickiewicz TL: Anterior cruciate ligament reconstruction using central third patella tendon with and without lateral sling augmentation. Presented at The Hospital for Special Surgery Annual Reunion, New York, November 1987.
 58. O'Brien SJ, Wickiewicz TL, Rawlins BA, et al: Anterior cruciate ligament reconstruction using central third patella tendon with and without 'lateral sling' augmentation. Presented at the 14th Annual Meeting of AOSSM, Palm Desert, CA, June 1988.
 59. Odensten M, Gillquist J: Functional anatomy of the anterior cruciate ligament and a rationale for reconstruction. *J Bone Joint Surg* 1985; 67(A):257-261.
 60. Paulos LE, Butler DL, Noyes FR, et al: Intraarticular cruciate reconstruction: Replacement with vascularized patellar tendon. *Clin Orthop* 1987; 172:78-84.
 61. Penner DA, Daniel DM, Wood P, et al: An in vitro study of anterior cruciate ligament graft placement and isometry. *Am J Sports Med* 1988; 16:238-243.
 62. Rosenberg T: *Arthroscopic technique for anterior cruciate ligament surgery*. Technical bulletin. Norwood, MA, Acufex Microsurgical, Inc, 1984.
 63. Rosenberg TD, Paulos LE, Abbott PJ: Arthroscopic cruciate repair and reconstruction: An overview and description of technique, in Feagin JA (ed): *The Crucial Ligaments*. New York, Churchill Livingstone, 1988, pp 409-423.
 64. Skyhar MJ, Altchek DW, Warren RF: Plastic suction tip in anterior cruciate ligament reconstruction. *Orthopaedic Review* 1988; 17:933-935.
 65. Springer SI: Anterior cruciate ligament substitution: Endoscopic technique, in Parisien JS (ed): *Arthroscopic Surgery*. New York, McGraw Hill, 1988, pp 213-220.
 66. Stone RG: Meniscal repair, in Parisien JS (ed): *Arthroscopic Surgery*. New York, McGraw Hill, 1988, pp 189-197.
 67. Warren RF: Arthroscopic meniscus repair. *Arthroscopy* 1985; 1:170-172.
 68. Warren RF, Hanley S, Bach BR: Chronic anterior cruciate ligament injury, in Parisien SJ (ed): *Arthroscopic Surgery*. New York, McGraw Hill, 1987, pp 125-133.
 69. Wang JG, Hewson GF: Anterior cruciate ligament reconstruction using the lateral one third of the patellar tendon, in Dorr L (ed): *Techniques in Orthopaedics*. Frederick, MD, Aspen Publishers, 1988, pp 23-27.
 70. Warren RF, Kaplan N, Bach BR Jr: The lateral notch sign of anterior cruciate ligament insufficiency. *The American Journal of Knee Surgery* 1988; 1:119-124.
 71. Wirth CR: Meniscus repair. *Clin Orthop* 1981; 157:153-160.