

# Arthroscopic Preparation of the Posterior and Posteroinferior Glenoid Labrum

Matthew T. Provencher, MD, LCDR, MC, USNR; Anthony A. Romeo, MD; Daniel J. Solomon, MD, CDR, MC, USN; Bernard R. Bach, Jr, MD; Brian J. Cole, MBA, MD

**Using an anterior portal for a labral elevator and shaver instrument, with the arthroscope in the anterosuperior portal, allows the posterior and posteroinferior chondrolabral junction to be safely prepared.**

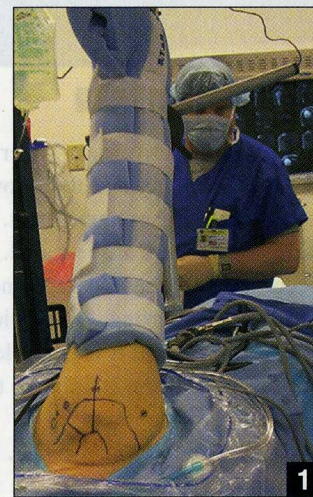Arthroscopic repair of a glenoid labral tear is a common procedure and in certain cases of traumatic shoulder instability, a tear of the posterior or posteroinferior labrum is encountered. Although

a number of portals have been described<sup>1-4</sup> that provide excellent access to place anchors and perform the capsulolabral repair, preparation of the posterior, and posteroinferior glenoid-labral interface may be difficult. Classically, this portion of the labrum has been prepared using a direct posterior or accessory posterolateral portal.<sup>4-9</sup> However, these portals usually provide an unfavorable trajectory that makes insertion of an arthroscopic labral preparation instrument into the chondrolabral junction difficult. This is due to the lack of co-linearity of the cannula relative to the posterior glenoid and labrum.<sup>3,4,10</sup> Because of this trajectory, the labrum may be truncated or inadvertently torn if the posterior and posteroinferior labrum preparation is performed from these portals. This article describes

a technique that allows easy access into the chondrolabral junction of this area of the glenoid labrum, without causing damage to the circumferential fibers of the labral tissue.

## TECHNIQUE

In a patient with a suspected tear of the posterior labrum, the lateral decubitus is preferred, especially when the pathology is in the posterior or posteroinferior aspect of the joint; an arm traction device provides sufficient traction to easily visualize and work in this area of the joint (Figure 1). Glenohumeral arthroscopy is initiated from a standard posterior portal, which is made slightly lateral than our beach chair posterior portal, such that the lateral edge of the acromion and portal are nearly in-line, and 1 cm inferior to the edge of the acromion. This allows the posterior portal to be angled slightly inferiorly (approximately 15°-20° of inclination) relative to the glenoid rim. An anterosuperior portal is made in the superior aspect of a rotator interval and a clear 5-mm cannula inserted. After



**Figure 1:** Patient in the lateral decubitus position in an arm traction device with approximately 65° abduction, 15° forward flexion, and 10 lbs of traction.

the diagnostic glenohumeral arthroscopy is completed, a mid-glenoid (anteroinferior) portal is made just superior to the subscapularis tendon with an 8.25-mm cannula to ensure that the posterior labrum can be accessed. The arthroscope is placed in the anterosuperior cannula over a switching-stick. This then gives excellent visualization to the posterior and inferior aspects of the shoulder joint. The original posterosuperior portal is replaced with a 5-mm cannula over a switching-stick. Alternatively, another

*Dr Provencher is from the Department of Orthopedic Surgery, Naval Medical Center, San Diego, California, and the Division of Sports Surgery, Rush University; Drs Romeo, Bach, and Cole are from the Department of Orthopedic Surgery, Rush University, Chicago, Illinois, and Dr Solomon is from the Naval Medical Center, San Diego, California.*

*Drs Provencher, Romeo, Solomon, Bach, and Cole have no financial interests to disclose.*

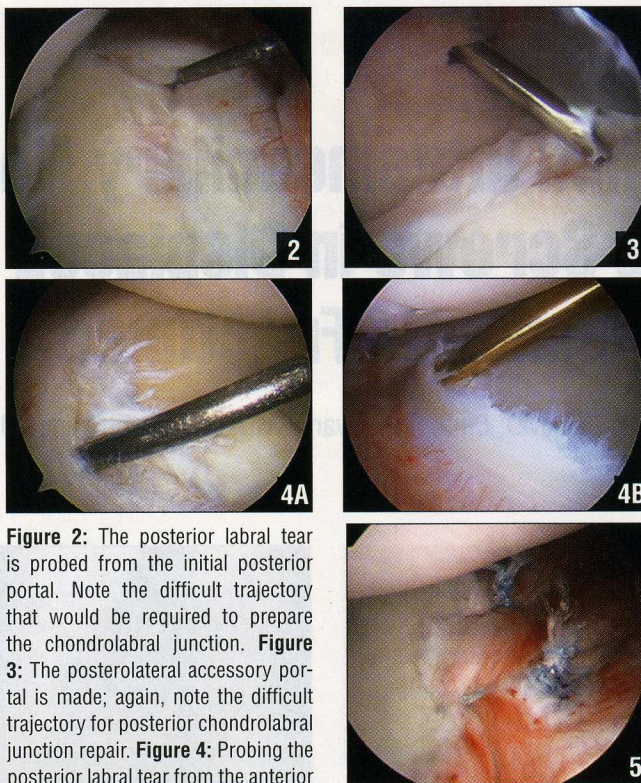
*The views expressed in this article are those of the authors and do not reflect the official policy or position of the Department of the Navy, Department of Defense, or United States Government.*

*Correspondence should be addressed to: Matthew T. Provencher, MD, 455 B Ave, Coronado, CA 92118.*

8.25-mm cannula can be placed if a significant posterior plication is warranted. The arthroscope may also be left in the posterosuperior portal if viewing of the posteroinferior quadrant of the glenoid labrum is sufficient.

The posterior labral tear is then identified and probed from the posterosuperior portal (Figure 2). The chondrolabral junction is evident, as the labrum has peeled off the glenoid. An accessory posterolateral portal may be made at this point and an appropriately sized cannula inserted if necessary. The trajectories provided by both of the posterior cannulas make it difficult for a labral elevator device to obtain access to the chondrolabral junction without causing additional damage to the labral tissue (Figure 3).

Instead of using the posterior portals to perform the posterior labral preparation, the mid-glenoid, or anteroinferior portal is used to identify the tear at the chondrolabral junction, and "peel up" and separate the labral tissue from the glenoid surface (Figure 4). In this manner, the mid-glenoid portal allows the arthroscopic labral elevator to traverse directly across the glenoid, enter the chondrolabral junction posteriorly, and elevate the labrum off of the glenoid, much like lifting a pancake off a hot griddle. Once the arthroscopic elevator is sufficiently under the posterior labral tissue, the device can be manipulated in a superior to inferior direction to complete the separation of the chondrolabral junction. A shaver can then be inserted through the mid-glenoid portal to start bony preparation. The bone in



**Figure 2:** The posterior labral tear is probed from the initial posterior portal. Note the difficult trajectory that would be required to prepare the chondrolabral junction. **Figure 3:** The posterolateral accessory portal is made; again, note the difficult trajectory for posterior chondrolabral junction repair. **Figure 4:** Probing the posterior labral tear from the anterior portal (A), followed by elevation with an arthroscopic elevator (B) (both are viewed from the anterosuperior portal). **Figure 5:** Final repair as viewed from the anterosuperior portal.

this area of the glenoid extends posteriorly from where the labrum normally sits, and can be prepared with the shaver in this manner, taking care not to injure the normal articular cartilage.

After the posterior labrum is sufficiently mobilized, additional preparation may be performed from one of the posterior portals. The posterior and posteroinferior capsulolabral repair can then be accomplished as previously described<sup>5,9,11,12</sup> (Figure 5). Incomplete tears or marginal "cracks" in the posterior labrum have also been described and are also best addressed in a similar fashion with an elevator device from the anterior portal.<sup>13</sup>

Preventing inadvertent trauma to the labrum or articular

cartilage during the labral preparation phase is an important aspect of a capsulolabral repair procedure. The trajectory of the traditional posterior and accessory posterolateral portals make an adequate glenoid labrum preparation difficult to perform. By using an anterior portal for labral elevator and shaver instrumentation, with the arthroscope in the anterosuperior portal, the posterior and posteroinferior chondrolabral junction may be safely prepared. □

## REFERENCES

- Boileau P, Ahrens P. The TOTS (temporary outside traction suture): a new technique to allow easy suture placement and improve capsular shift in arthroscopic bankart repair. *Arthroscopy*. 2003; 19:672-677.
- Costouros JG, Clavert P, Warner JJ. Trans-cuff portal for arthroscopic posterior capsulorrhaphy. *Arthroscopy*. 2006; 22:1138 e1-5.
- Difelice GS, Williams RJ III, Cohen MS, Warren RF. The accessory posterior portal for shoulder arthroscopy: description of technique and cadaveric study. *Arthroscopy*. 2001; 17:888-891.
- Goubier JN, Iserin A, Duranthon LD, Vandebussche E, Augereau B. A 4-portal arthroscopic stabilization in posterior shoulder instability. *J Shoulder Elbow Surg*. 2003; 12:337-341.
- Bradley JP, Baker CL III, Kline AJ, Armfield DR, Chhabra A. Arthroscopic capsulolabral reconstruction for posterior instability of the shoulder: a prospective study of 100 shoulders. *Am J Sports Med*. 2006; 34:1061-1071.
- Lo IK, Burkhart SS. Triple labral lesions: pathology and surgical repair technique-report of seven cases. *Arthroscopy*. 2005; 21:186-193.
- McIntyre LF, Caspari RB, Savoie FH III. The arthroscopic treatment of posterior shoulder instability: two-year results of a multiple suture technique. *Arthroscopy*. 1997; 13:426-432.
- Williams RJ III, Strickland S, Cohen M, Altchek DW, Warren RF. Arthroscopic repair for traumatic posterior shoulder instability. *Am J Sports Med*. 2003; 31:203-209.
- Wolf EM, Eakin CL. Arthroscopic capsular plication for posterior shoulder instability. *Arthroscopy*. 1998; 14:153-163.
- Sekiya JK. Arthroscopic labral repair and capsular shift of the glenohumeral joint: technical pearls for a multiple pleated plication through a single working portal. *Arthroscopy*. 2005; 21:766.
- Bottoni CR, Franks BR, Moore JH, DeBerardino TM, Taylor DC, Arciero RA. Operative stabilization of posterior shoulder instability. *Am J Sports Med*. 2005; 33:996-1002.
- Provencher MT, Bell SJ, Menzel KA, Mologne TS. Arthroscopic treatment of posterior shoulder instability: results in 33 patients. *Am J Sports Med*. 2005; 33:1463-1471.
- Kim SH, Ha KI, Yoo JC, Noh KC. Kim's lesion: an incomplete and concealed avulsion of the posteroinferior labrum in posterior or multidirectional posteroinferior instability of the shoulder. *Arthroscopy*. 2004; 20:712-720.

Section Editor: Steven F. Harwin, MD