



Managing Tunnel Malposition and Widening in Revision Anterior Cruciate Ligament Surgery

Andreas H. Gomoll, MD, and Bernard R. Bach, Jr, MD

Tunnel malposition has been identified as the single most common technical error leading to failure of primary anterior cruciate ligament reconstruction. Revision of malpositioned or widened tunnels remains a challenging procedure that requires thorough preoperative planning. This article will discuss the management of tunnel complications during revision anterior cruciate ligament reconstruction.

Oper Tech Sports Med 14:36-44 © 2006 Elsevier Inc. All rights reserved.

KEYWORDS revision ACL reconstruction, ACL complications, tunnel malposition, tunnel widening

Failure rates of 10% to 15%¹⁻³ are being reported after anterior cruciate ligament (ACL) reconstruction. Malpositioned tibial and/or femoral tunnels are the most commonly identified technical reasons for failure of ACL reconstruction because of the resultant abnormal graft isometry. However, even correctly placed-but-widened tunnels can present a challenge to the revising surgeon as a result of the associated bone loss, which can compromise fixation. This article will focus on the recognition and management of tunnel malpositioning and widening during revision ACL reconstruction. A more detailed description of the basic technical aspects of primary and revision ACL reconstruction has been provided previously.^{4,5}

Preoperative Workup and Surgical Decision-Making

Surgical decision-making before revision ACL reconstruction is based on a thorough history and physical examination, as well as imaging studies to identify associated pathology that might require concomitant correction at the time of surgery.

Radiographic evaluation is essential and should include standing anterior-posterior and 45° flexion posterior-anterior views, lateral, and Merchant views. Any concerns over limb malalignment should be investigated with single- or double-stance, full-length alignment films. On the basis of

these imaging studies, the tibial and femoral tunnels can be classified as either anatomic or malpositioned or widened. Tunnel malposition can be further subclassified according to whether anatomically placed revision tunnels would result in any overlap. Finally, radiographs will provide information on the presence, position, and type of fixation devices, such as interference screws, staples, transfixation pins, or other hardware that could potentially interfere with revision surgery.

If plain radiographs demonstrate tunnel widening, a thin-cut computed tomography (CT) scan, ideally with 2-dimensional image reconstruction in other planes, can be obtained to assist with preoperative planning and assess the potential need for a concomitant or staged bone-grafting procedure. Because widening has been associated with the use of certain graft types, such as hamstring auto- and allograft, Achilles allograft and synthetic Gore-Tex grafts, a preoperative CT is recommended even if widening is not evident on plain radiographs.⁶

After review of the preoperative examination and imaging studies, 1 of 3 situations applies: the existing tunnels are in an anatomic position; the tunnels are in a nonanatomic position; and/or significant bone loss because of tunnel widening is present. Anatomic tunnels usually are easily revised because most can simply be reused after hardware removal. Nonanatomic tunnels that are positioned such as to not interfere with the new revision tunnels (Fig. 1A) can largely be ignored, with hardware removal only when needed (Fig. 1B). It is the nonanatomic tunnels that overlap with the revision tunnels that present a challenge because the resultant oval or figure-eight defect can compromise secure fixation and may require bone grafting (Fig. 2).⁷ Finally, extensive bone loss caused by significant tunnel widening (Fig. 3), although rare, should be

Division of Sports Medicine, Department of Orthopedic Surgery, Rush University Medical Center, Chicago, IL.

Address reprint requests to Bernard R. Bach, Jr, MD, Rush University Medical Center, 1725 W Harrison St, Suite 1063, Chicago, IL 60612. E-mail: brbachmd@comcast.net

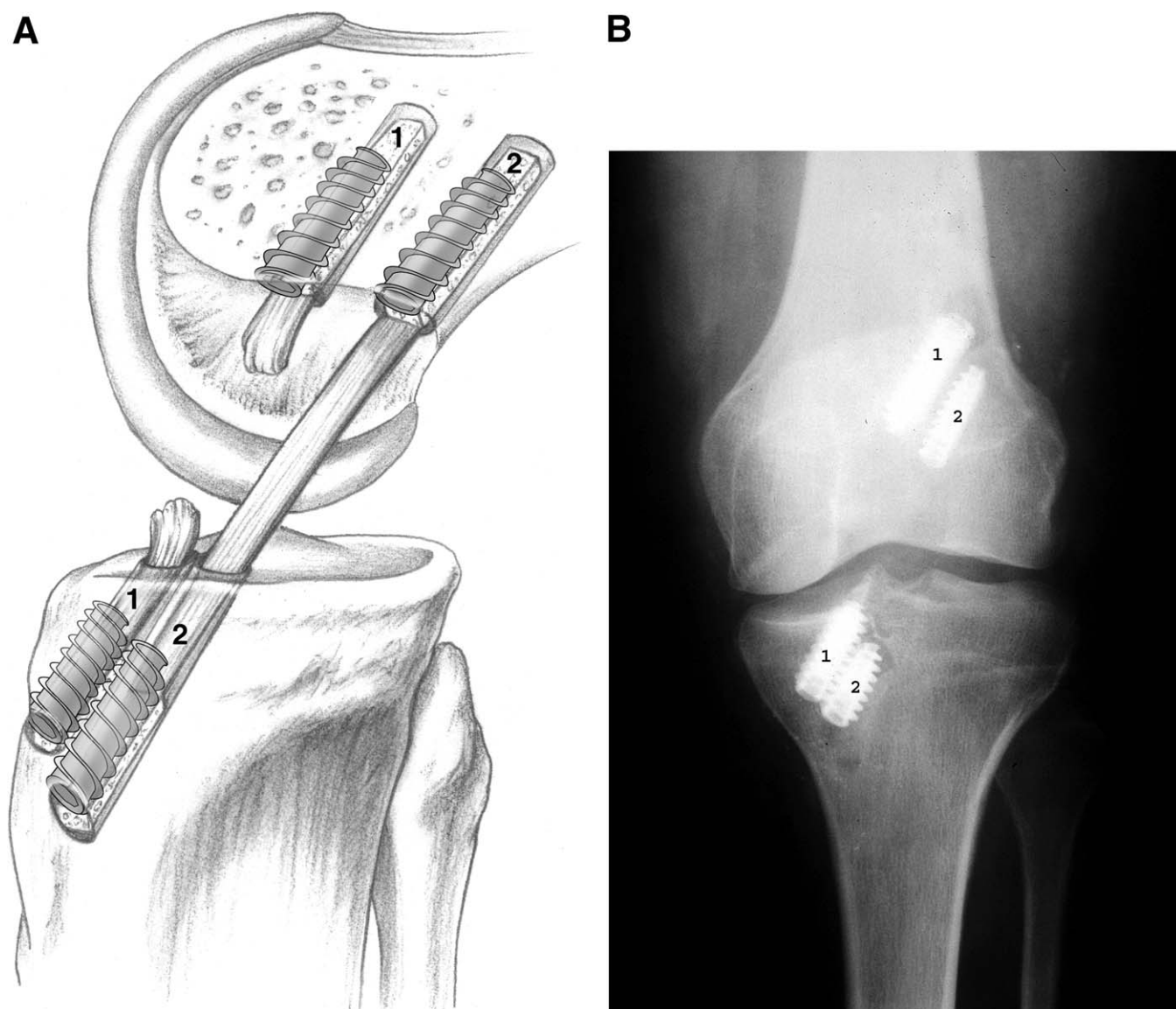


Figure 1 (A) Pre-existing nonanatomic femoral tunnel that was by-passed by a new, anatomically positioned tunnel. The orientation of the initial tunnel might necessitate screw removal during tunnel reaming and subsequent reinsertion. (Reproduced with permission from Bach et al.¹⁰ © 2002 American Academy of Orthopaedic Surgeons.) (B) Radiograph showing by-passing of a pre-existing malpositioned tunnel without hardware removal. (1) Index hardware; (2) revision hardware.

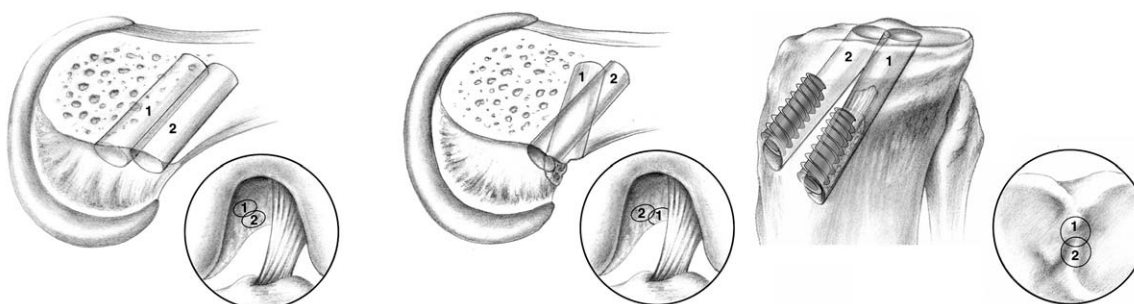


Figure 2 Figure-eight defects as the result of new anatomic revision tunnels overlapping with pre-existing malpositioned tunnels. (Reproduced with permission from Bach et al.¹⁰ © 2002 American Academy of Orthopaedic Surgeons.)

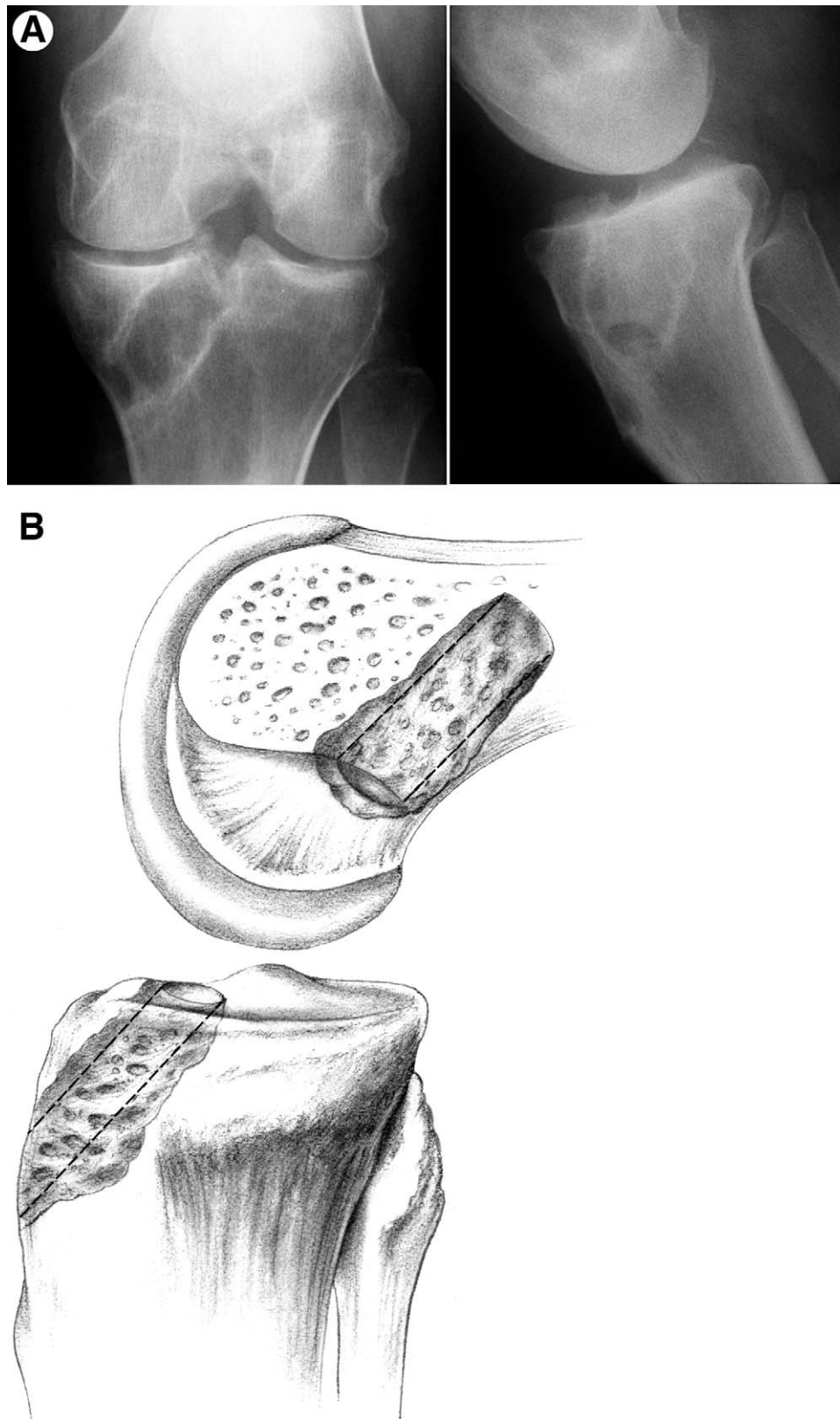


Figure 3 Radiograph (A) and schematic illustration (B) depicting tunnel widening. CT scan should be considered and a staged bone grafting performed before revision reconstruction. (Reproduced with permission from Bach et al.¹⁰ © 2002 American Academy of Orthopaedic Surgeons.)

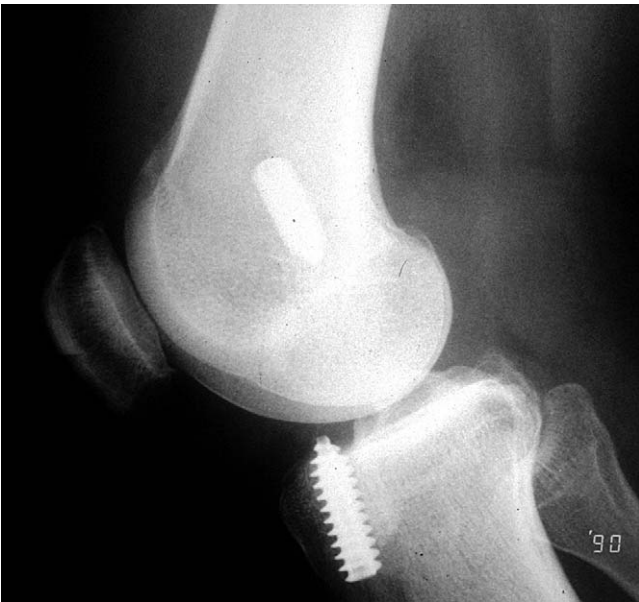

Figure 4 Lateral radiograph showing anterior malpositioning of the tibial tunnel.

treated with a bone grafting procedure, followed by staged ligament reconstruction after 3 to 4 months.

Clinically significant tunnel malposition is more common on the femoral side. If encountered in the tibia, the tunnel is frequently placed too anteriorly (Fig. 4), which predisposes to notch impingement and loss of full extension, or is oriented too much in the sagittal plane. Although itself not clinically significant, a tibial tunnel that is oriented too much

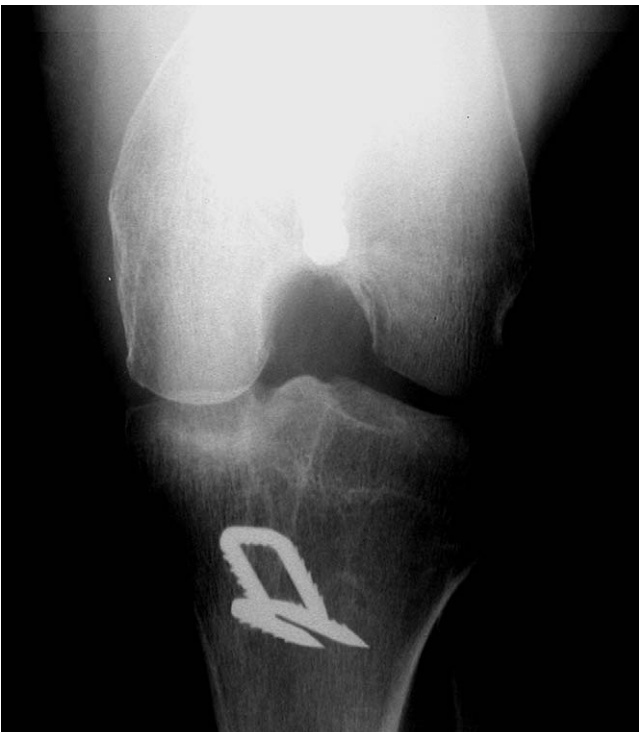

Figure 5 Anteroposterior radiograph demonstrating vertical malpositioning of the femoral footprint and tunnel.

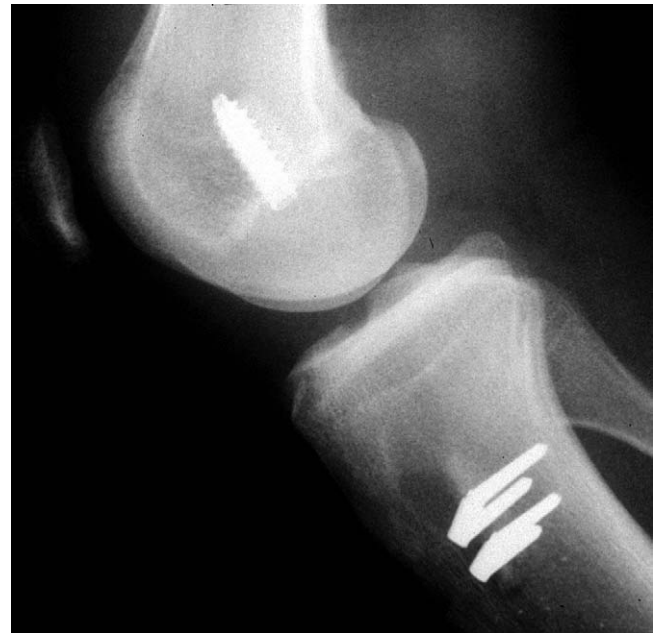

Figure 6 Lateral radiograph depicting anteriorly malpositioned femoral tunnel.

in the sagittal plane (too vertical) forces a femoral starting point that is high in the notch (Fig. 5), rather than in the preferred 1- or 11-o'clock position, and has been associated with inadequate restoration of rotational stability. Besides coronal plane malpositioning, femoral tunnel complications include anterior tunnel placement (Fig. 6), resulting in loss of flexion, and posterior wall insufficiency (Fig. 7), which often requires the use of an alternate fixation device or a 2-incision technique to achieve femoral fixation.

The “divergent tunnel” or “funnel” concept (Fig. 8)^{6,7} allows the surgeon to address malpositioned tunnels and avoid pre-existing hardware that might be difficult to remove (Fig. 9). Although the intraarticular entry points of the tibial and femoral tunnels attempt to recreate the anatomic ACL footprint, extraarticular tunnel orientation is of less importance for ACL function. The footprint can be approached from several different extraarticular orientations. For example, al-

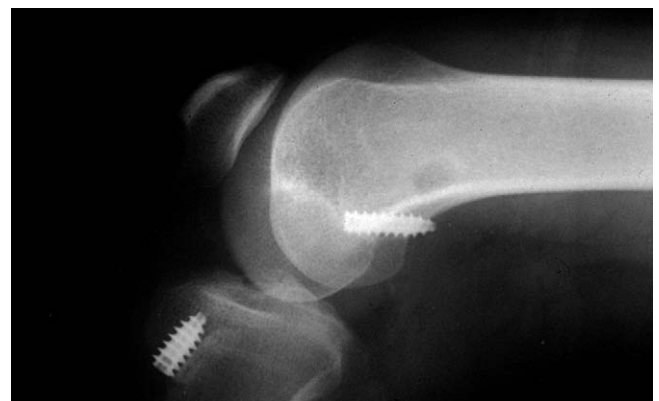

Figure 7 Lateral radiograph showing loss of femoral fixation caused by posterior wall insufficiency.

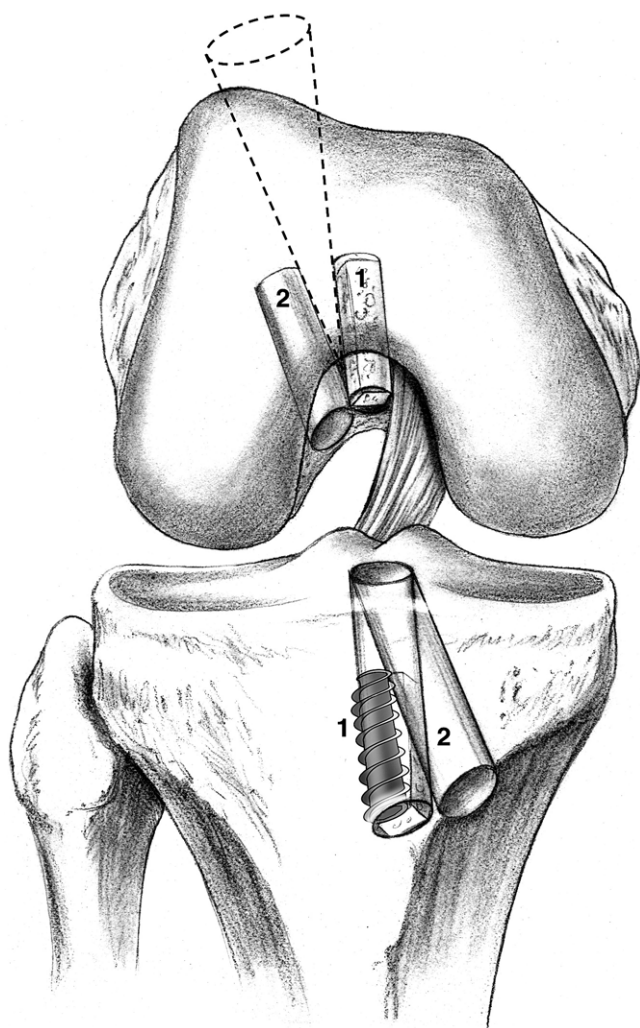


Figure 8 Funnel concept. (1) Index reconstruction. Note how the sagittally oriented tibial tunnel affects orientation of the index femoral tunnel. (2) Correctly oriented revision tunnels. (Reproduced with permission from Bach et al.¹⁰ © 2002 American Academy of Orthopaedic Surgeons.)

though the same femoral intraarticular entry point can be obtained using an endoscopic or 2-incision technique, the extraarticular femoral tunnel directions are quite different. Similarly, the tibial footprint can be approached from multiple angles by choosing different starting points for the tibial tunnel in both the mediolateral and superoinferior planes.

Technical Aspects

The preoperative plan, including the type of reconstruction (endoscopic versus 2-incision), graft type, hardware removal, and bone graft requirement should be prepared before surgery. If allograft tissue is chosen, graft availability should be confirmed before induction of anesthesia. If hardware is present, appropriate tools should be available for removal, including different screwdrivers for the various screw types in use.⁸ In addition, special instrumentation should be readily available to facilitate removal of stripped screws.

ACL insufficiency is confirmed through an examination under anesthesia and arthroscopic evaluation. Once insufficiency is established, debridement of the residual ACL and soft tissue should be performed to expose the tibial footprint, the lateral wall of the intercondylar notch, and the over-the-top position on the distal femur. A notchplasty should be performed as needed to prevent graft impingement.

Tibial Tunnel Preparation

Next, the tibial tunnel is prepared; depending on graft length, the tibial drill guide is set at 50° to 55°. The aiming device is positioned so that the guide wire will enter the joint centrally between the medial and lateral tibial eminence, and at the level of the posterior edge of the anterior horn of the lateral meniscus, which results in an exit point approximately 7 mm anterior to the PCL.

Once the intraarticular arm of the tibial guide has been placed, the extraarticular portion should be positioned. An entry site at least 2 to 2.5 cm below the joint line and halfway between the tibial tubercle and the posteromedial corner of the tibia will produce appropriate tibial tunnel orientation.⁶ An incision is made to expose the medial tibial metaphyseal region, the guide pin is advanced into the joint, and the pin position is confirmed arthroscopically. Frequently, the guide pin will encounter the previous tunnel as it enters the joint. In this case, the pin is not securely fixed at the articular entry point, and a Kocher clamp should be used to stabilize the pin because the reamer will have a tendency to break into the old tunnel, thus deviating from the new path. If pre-existing hardware interferes with reaming of the tibial tunnel, it is removed; otherwise, it can remain in place. If the entry sites of the old and new tunnels overlap, the old screw may be temporarily removed during drilling and then replaced at the time of graft fixation to the tibia, essentially stacking the old and new interference screws (Fig. 10). Alternatively, the old tibial tunnel may be bone grafted, and a single interference screw may be used. Most commonly, however, the diverging tunnel method allows the creation of a separate tibial tunnel with an adequate bony bridge such that bone grafting is not necessary, and conventional interference screw fixation can be used. After reaming, the tunnel can be inspected with the arthroscope placed retrograde for any residual soft tissue from the prior reconstruction, which should be removed with a curette or the shaver.

Femoral Tunnel Preparation

Attention is then directed to the femoral tunnel. If the femoral tunnel is in the appropriate position, it may be reused after hardware removal; any bone around the periphery of the screw should be cleared first with a bur, osteotome, or curette to facilitate screw removal and prevent stripping. Depending on screw orientation, the screwdriver can be introduced from either the standard or accessory inferomedial portals or, in anatomically positioned tunnels, through the tibial tunnel itself. After the screw is completely removed from the femoral tunnel, it can be gripped with a hemostat and removed

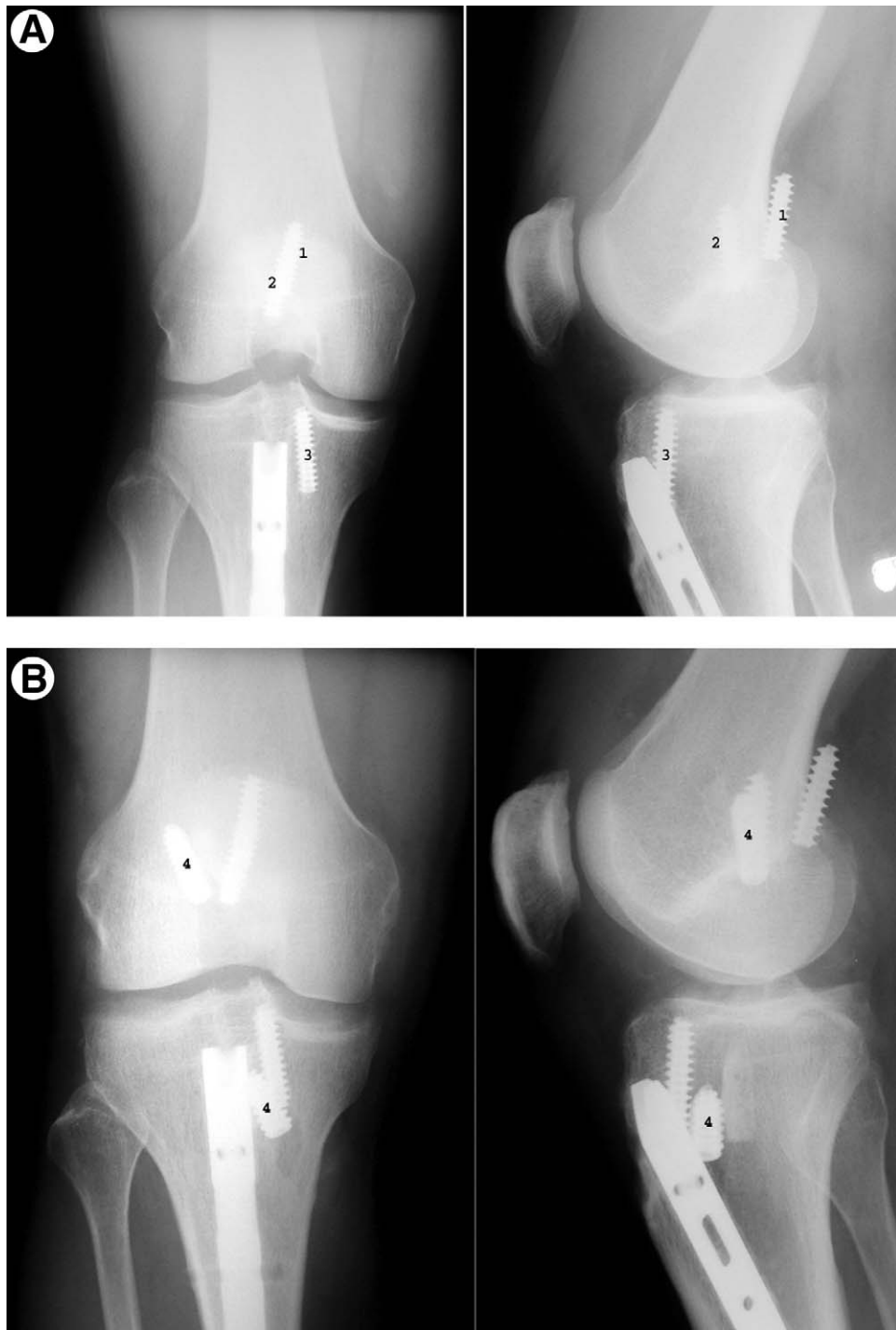


Figure 9 (A) Pre-revision radiographs demonstrating femoral malpositioning. (1) Interference screw positioned in the posterior soft tissues; (2) second screw aiming medially, thus diverging from the femoral tunnel; (3) it is preferable to use a 9 mm interference screw for improved tibial fixation. (B) Postoperative radiographs demonstrating revision ACL reconstruction bypassing preexisting hardware. (4) Revision interference screws in correct position. The interference screw in the posterior soft tissues was not removed to avoid extensive dissection close to the neurovascular bundle.

through a portal. If the tunnel is in a nonanatomic position, it may be possible to bypass the hardware altogether and create an entirely new femoral tunnel.

A femoral offset guide is placed through the tibial tunnel in the over-the-top position on the lateral wall of the intercondylar notch. Occasionally, the alignment of the tibial tunnel

forces the femoral offset guide into an unacceptably vertical position on the femur. In this case, the guide can be placed through an accessory inferomedial portal with the knee hyperflexed (130°) to obtain the correct femoral starting position.⁹ A guide pin is then drilled into the femur to a depth of approximately 3 to 4 cm, and provisionally over-reamed with

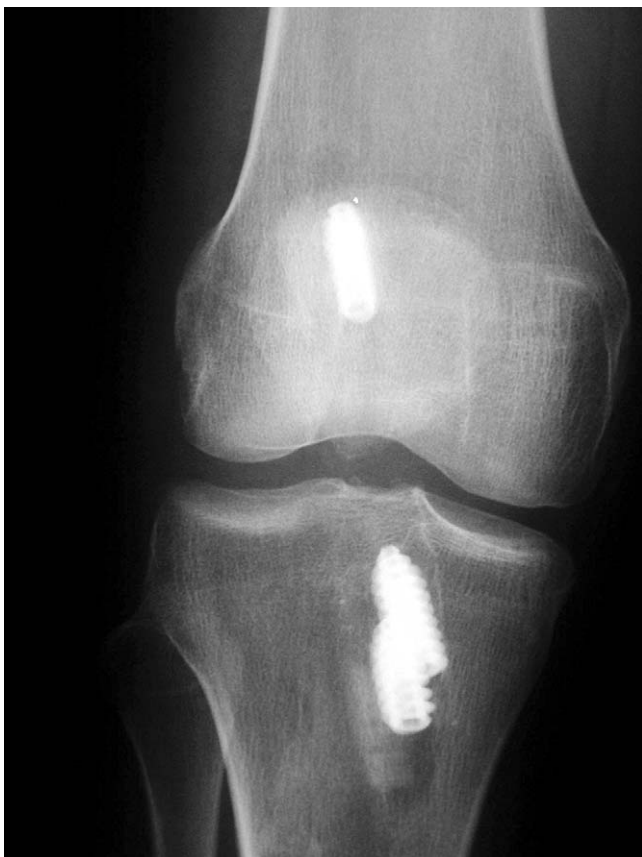

Figure 10 Anteroposterior radiograph depicting stacking of screws to allow for secure graft fixation in a mildly expanded tibial tunnel.

a cannulated reamer to a depth of 5 to 7 mm to create an “endoscopic footprint.” The reamer is then removed, and the footprint is visualized arthroscopically to confirm an intact posterior wall. Once an intact posterior wall is confirmed by probing, the reamer is advanced into the femur approximately 35 mm. Tunnel integrity can be assessed by placing the arthroscope retrograde through the tibial tunnel into the newly created femoral tunnel, to ensure an intact posterior wall along the entire course of the tunnel.

An anatomic but posterior wall-deficient femoral tunnel can be addressed by a 2-incision technique to create a divergent tunnel (Fig. 11). For the 2-incision technique, a lateral incision is made beginning at the level of the proximal pole of the patella and extending 3 to 5 cm further proximally. The exposure is carried down do the iliotibial band, which is incised in its midsubstance. The vastus lateralis muscle is bluntly elevated off the intermuscular septum and retracted anteriorly with a Z-retractor. The periosteum is longitudinally divided with electrocautery, and subperiosteal dissection is continued with a Cobb elevator such that the “over-the-top” position can be palpated. A J-shaped femoral guide passer is then inserted through the anterolateral portal into the intercondylar notch, and around the over-the-top position to exit the joint capsule anterior to the lateral intermuscular septum. The rear-entry femoral guide is then attached to the guide passer and directed into the intercondylar notch. The rear-entry guide is placed in the over-the-top position,

the femoral guide pin is drilled into the distal femur under arthroscopic visualization, and then over-reamed with the cannulated reamer.⁷

Bone Grafting

Bone grafting may be performed in either a concomitant or staged fashion to address overlapping or widened tunnels. Graft choices include autograft or, more commonly, allograft to avoid the morbidity associated with iliac-crest graft harvesting. Allograft bone chips or struts, as well as bone resulting from preparation of the tendon graft is commonly used. In the case of overlapping tibial tunnels, either bone graft or a larger tibial bone plug can be used to fill the defect and still allow for interference screw fixation. Similarly, if the old and new femoral tunnels overlap, bone graft can be used to fill the defect left by the previous tunnel. To minimize extravasation of bone graft material into the joint, we found it helpful to use a clear shoulder arthroscopy cannula or, alternatively, a 3-mL syringe with the front end cut off. The syringe is filled with morcellized bone-graft, introduced through a slightly enlarged arthroscopy portal, directed into the defect, and the

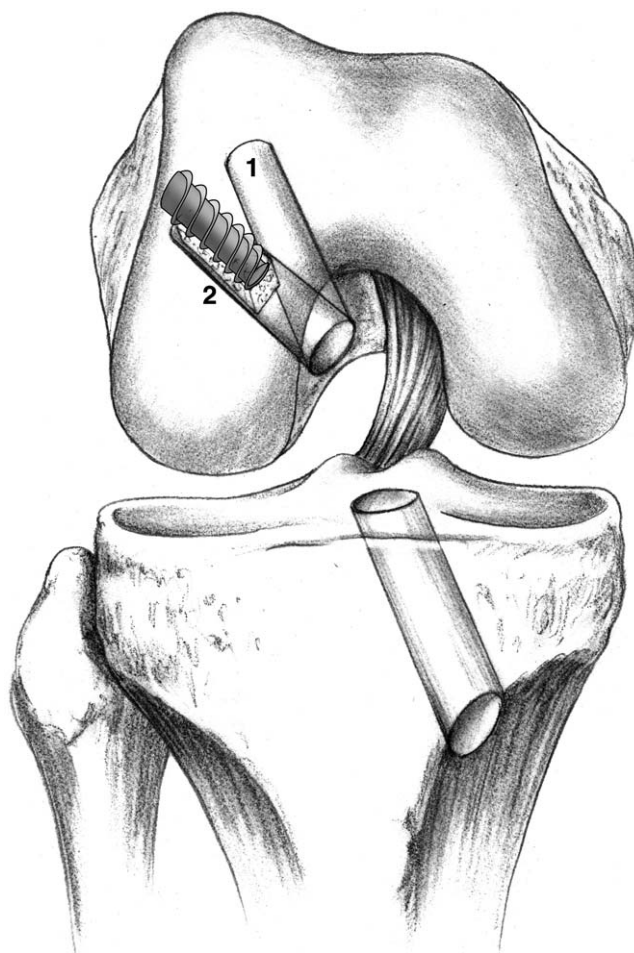


Figure 11 Two-incision technique to address posterior wall deficiency. Note the different tunnel alignment with an identical intra-articular entrance position. (Reproduced with permission from Bach et al.¹⁰ © 2002 American Academy of Orthopaedic Surgeons.)

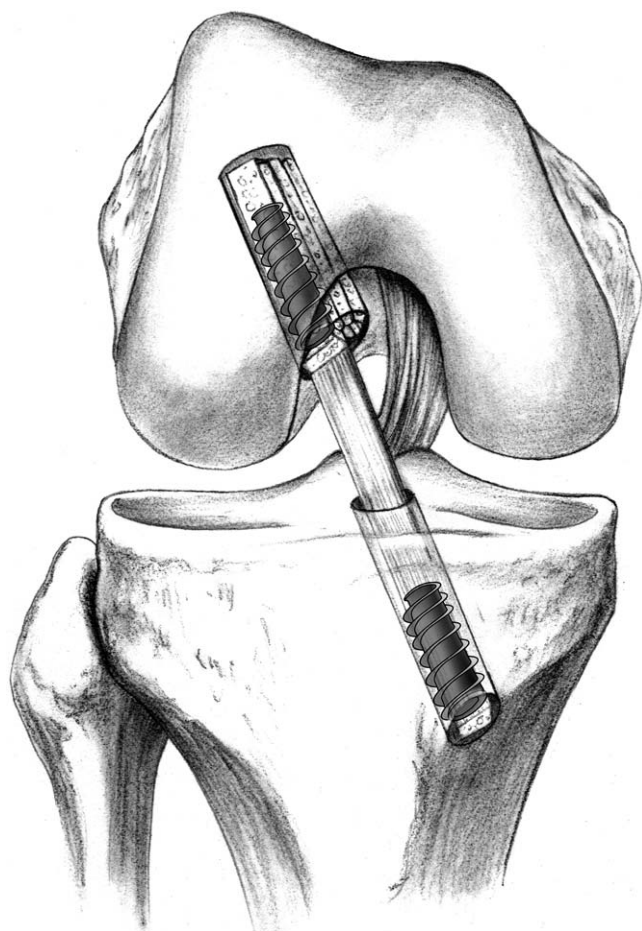


Figure 12 Matchstick bone grafting to address femoral tunnel widening. (Reproduced with permission from Bach et al.¹⁰ © 2002 American Academy of Orthopaedic Surgeons.)

bone graft delivered by advancing the plunger. Other options include placing cortical allograft “matchsticks” into the defect (Fig 12),⁷ or leaving the graft bone plugs sufficiently large to fill the tunnel defects. Alternatively, screws may be “stacked” to enhance bone plug fixation in overlapping or widened tunnels (Fig. 13). Supplemental fixation (eg, Endobutton, staples, post, suture button) on both the femoral and tibial sides should be strongly considered whenever secure graft fixation may be compromised due to enlarged or bone-grafted tunnels (Fig. 14).

If bone stock is severely compromised because of extensive tunnel widening, primary bone grafting is advisable. All hardware is removed, and both tibial and femoral tunnels are filled with morcellized bone graft (Fig. 15). After 3 to 4 months, the patient returns for staged ligament reconstruction.

Graft Preparation, Introduction, and Fixation

We prefer the use of bone–tendon–bone patellar allograft for revision ACL reconstructions. This graft type permits the surgeon to customize the size of the tendon graft and bone plugs, provides additional bone for potential bone grafting, allows for

interference screw fixation on both sides of the joint, and results in low morbidity to the patient.¹⁰ When requesting allograft tissue, the patient’s height and a preferred graft length should be provided to prevent a significant graft/host mismatch. Also, informed consent discussing the risks and benefits of allograft tissue must be obtained from the patient.

The total graft length is generally 95 to 105 mm, with a tendon length between 40 and 50 mm, and bone plugs sized to approximately 25 mm. The femoral plug/tendon interface is marked on the cancellous side with a sterile marking pen to help confirm complete seating of the femoral bone plug during fixation. Two drill holes are placed in the tibial bone plug and #5 braided polyester suture is passed through each hole. Because we prefer the “push-in” technique to guide the proximal bone plug into the femoral tunnel, no holes are drilled into the femoral bone plug. With the knee flexed approximately 80°, the femoral bone plug is advanced through the tibial tunnel into the joint with a two-pronged pusher. A hemostat is then placed through the medial portal, to grasp and advance the proximal plug into the femoral tunnel. A Nitinol wire is inserted through the accessory inferomedial

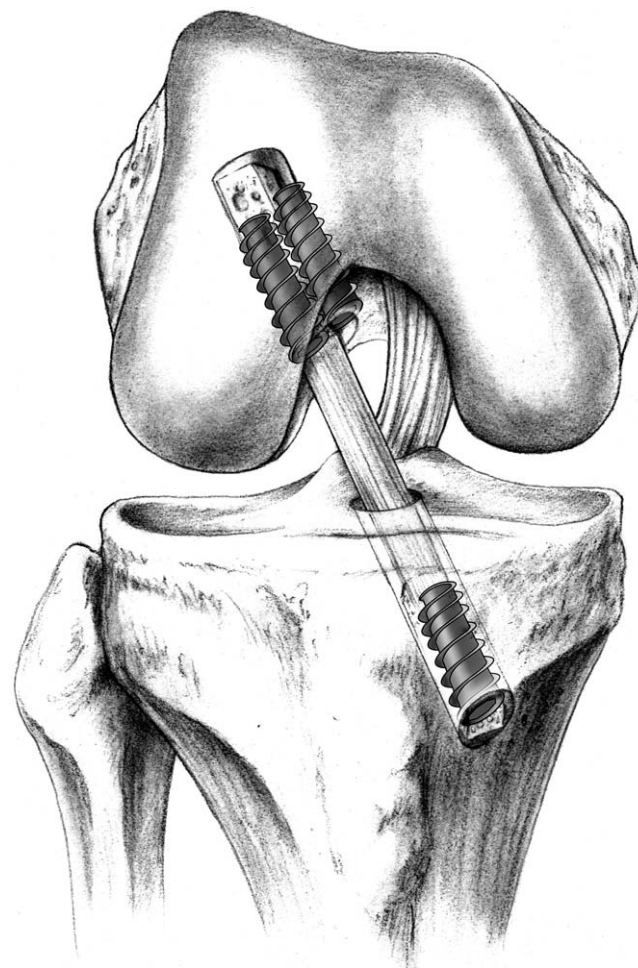


Figure 13 Stacking of screws for improved fixation in mildly widened tunnels, which can be applied to either the femur and tibia. (Reproduced with permission from Bach et al.¹⁰ © 2002 American Academy of Orthopaedic Surgeons.)

portal into the femoral tunnel anterior to the femoral plug with the knee hyperflexed to 100° to 110° to assure parallel placement of the femoral interference screw. Femoral fixation is achieved with a 7-mm × 25-mm cannulated interference screw, and should be performed in hyperflexion to prevent divergent screw placement with potential breakout through the posterior femur.¹⁰

Tibial fixation is then performed. The graft is rotated 180° and oriented such that the cancellous side of the bone plug is facing posterior and the cortical side of the bone plug is facing anterior. While holding tension on the tibial plug to prevent twisting, a tibial interference screw is placed anterior to the bone plug with the knee in full extension. Anterior screw placement is less likely to abrade the tendinous portion of the graft if the screw tip extends past the tibial bone plug. If there are concerns regarding adequate tibial fixation, supplemental fixation with a screw and post construct or use of a Hewson ligament button (Richards, Memphis, TN) may be used.⁷

Once the graft is secured, the knee is cycled multiple times and the reconstruction is assessed with Lachman, anterior

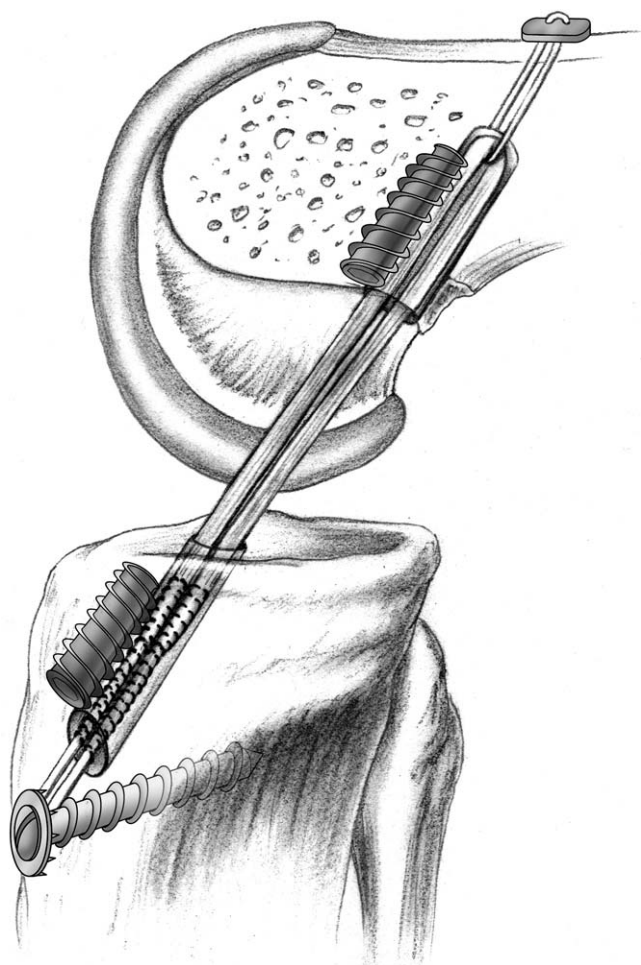


Figure 14 Supplemental graft fixation with femoral Endobutton and tibial post. Note the posterior wall blow-out, which can be managed either with supplemental Endobutton fixation as depicted here, or alternatively, by a two-incision approach. (Reproduced with permission from Bach et al.¹⁰ © 2002 American Academy of Orthopaedic Surgeons.)

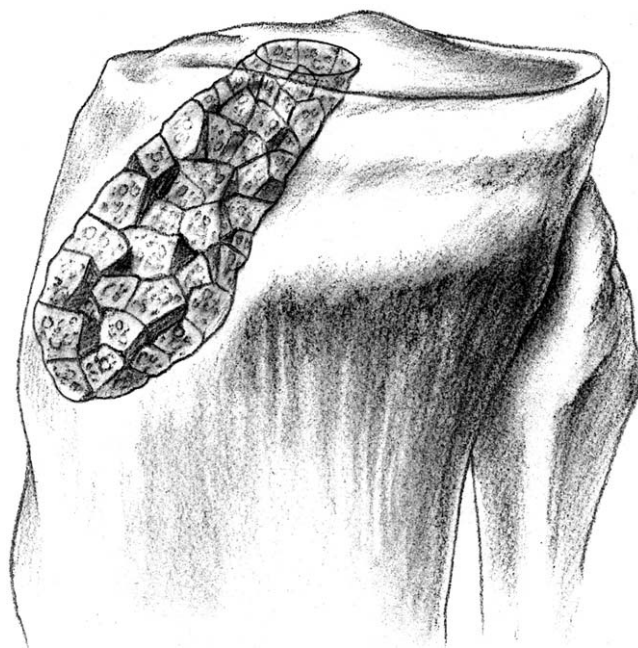


Figure 15 Bone grafting of widened tunnels before staged revision ACL reconstruction (Reproduced with permission from Bach et al.¹⁰ © 2002 American Academy of Orthopaedic Surgeons.)

drawer and pivot-shift tests. The arthroscope is reinserted to inspect the graft, assess for potential graft impingement in the intercondylar notch, and rule out prominent screws or loose bone graft. The knee is then copiously irrigated, and wounds are closed in a standard fashion.

References

1. Bach BR Jr, Jones GT, Sweet FA, et al: Arthroscopy-assisted anterior cruciate ligament reconstruction using patellar tendon substitution. Two- to four-year follow-up results. *Am J Sports Med* 22:758-767, 1994
2. Bach BR Jr, Levy ME, Bojchuk J, et al: Single-incision endoscopic anterior cruciate ligament reconstruction using patellar tendon autograft. Minimum two-year follow-up evaluation. *Am J Sports Med* 26:30-40, 1998
3. Bach BR Jr, Tradonsky S, Bojchuk J, et al: Arthroscopically assisted anterior cruciate ligament reconstruction using patellar tendon autograft. Five- to nine-year follow-up evaluation. *Am J Sports Med* 26: 20-29, 1998
4. Bach BR Jr: Patellar tendon autograft for ACL reconstruction, in Miller M, Cole BJ (eds): *Textbook of Arthroscopy*. Philadelphia, PA, Saunders-Elsevier, 2004, pp 645-655
5. Creighton RA, Bach BR Jr: Revision anterior cruciate ligament reconstruction with patellar tendon allograft. *Surgical technique. Sports Med Arthrosc Rev* 13:38-45, 2005
6. Bach BR Jr: Revision anterior cruciate ligament surgery. *Arthroscopy* 19:14-29, 2003 (suppl 1)
7. Bach BR Jr: Revision ACL reconstruction: indications and technique, in Miller M, Cole BJ (eds): *Textbook of Arthroscopy*. Philadelphia, PA, Saunders-Elsevier, 2004, pp 675-686
8. Bach BR Jr: Special report: observations on interference screw morphologies. *Arthroscopy* 16:E10, 2000
9. O'Donnell JB, Scerpella TA: Endoscopic anterior cruciate ligament reconstruction: modified technique and radiographic review. *Arthroscopy* 11:577-584, 1995
10. Bach BR Jr, Mazzocca A, Fox JA: Revision anterior cruciate ligament surgery, in Grana WA (ed): *Orthopaedic Knowledge Online*. Rosemont, IL, American Academy of Orthopaedic Surgeons, 2002. Available at: <http://www.aaos.org/oko>. Accessed March 9, 2006