

Posterior Cruciate Ligament Reconstruction

Current Trends

Michael G. Dennis, MD
Jeff A. Fox, MD
J. Winslow Alford, MD
Jennifer K. Hayden, MSN
Bernard R. Bach, Jr, MD

ABSTRACT: A survey was conducted of the Herodicus Society membership to assess the current status of treating posterior cruciate ligament (PCL) injuries and compared to a similar survey conducted in 1991. The survey addressed indications, graft choice, surgical technique, graft tensioning, and graft fixation issues. Seventy-eight active surgeons were sent a 34-question survey pertaining to isolated PCL injuries.

The majority of respondents (78%) performed ≤ 10 PCL reconstructions per year. The arthroscopic assisted with posteromedial portal technique was the most commonly used (49%). The tibial inlay/onlay technique was used by 15%, and 68% used the single femoral tunnel technique. The remainder used a double femoral tunnel technique. Allograft Achilles tendon was the most commonly selected graft for acute (43%) and chronic (50%) PCL reconstructions. An interference screw for femoral fixation was used 67%

of the time. The majority of respondents (55%) tensioned their single bundle or anterolateral band of a double bundle in 71° - 90° of flexion. A significant difference in technique was noted when comparing those who performed ≤ 10 PCL reconstructions per year (group 1) versus >10 PCL reconstructions per year (group 2). In group 1, 25% of surgeons used a double tunnel technique versus 59% of surgeons in group 2. The most common operative treatment for PCL injuries consisted of a single femoral tunnel with an Achilles tendon allograft.

When compared to a similar survey conducted in 1991, the notable differences were a trend toward Achilles tendon allograft and the popularization of the double femoral tunnel and tibial inlay/onlay technique.

[*J Knee Surg.* 2004;17:xxx-xxx.]

INTRODUCTION

In contrast to the anterior cruciate ligament (ACL), the indications for posterior cruciate ligament (PCL) surgery are not well established. Posterior cruciate ligament injuries occur less frequently than ACL injuries and many isolated PCL injuries may be undetected.³² As a result, our understanding of the PCL-deficient knee lags

behind that of the ACL-deficient knee. Posterior cruciate ligament injuries have historically been underdiagnosed due to their frequent asymptomatic nature. Natural history studies have suggested that at short and intermediate follow-up, PCL-deficient athletes functioned well despite obvious clinical laxities.^{12,26} Furthermore, a 2%-5% incidence of unrecognized PCL-deficiency has been noted in elite college football players.²⁶ More recently, Shelbourne et al²⁸ reported that PCL tears occur in 1%-44% of all acute knee injuries.

In 1991, the senior author (B.R.B.) conducted a survey of the Herodicus Society membership to evaluate current status of the PCL.² In the past decade, many changes have occurred in the basic science knowledge, available

Drs Dennis, Fox, Alford, and Bach and Ms Hayden are from the Division of Sports Medicine, Department of Orthopedic Surgery, Rush University Medical Center, Chicago, Ill.

Reprint requests: Bernard R. Bach, Jr, MD, 1725 W Harrison St, Ste 1063, Chicago, IL 60612.

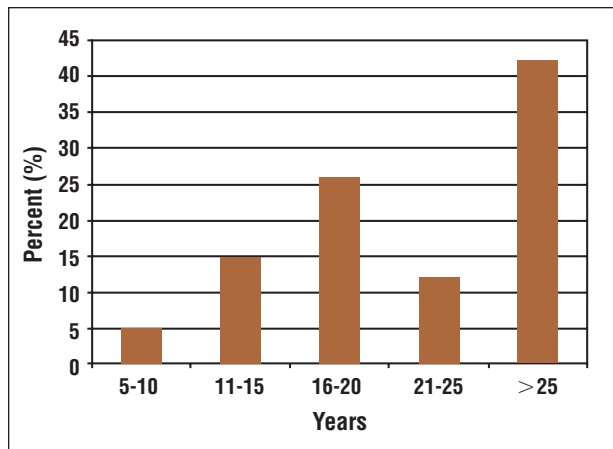


Figure 1. Practice profile of the surveyed surgeons with respect to years in practice.

techniques, and the grafts used. Graft selection, graft placement, fixation method, knee position at fixation, period of immobilization, position of immobilization, and rehabilitation are among the many factors that contribute to the variables affecting PCL surgical results. Additionally, most knee ligament surgeons, many of whom perform >100 ACL reconstructions annually, are relatively inexperienced with PCL reconstructive surgery.

An updated survey was conducted of the Herodicus Society to assess the current status of treating PCL injuries. The survey addressed indications, graft choice, surgical technique, graft tensioning, and graft fixation issues.

MATERIALS AND METHODS

Eighty-one members of the Herodicus Society were sent a 34-question survey pertaining to isolated PCL injuries. The survey was an expansion of the original survey from 1991.²

The Herodicus Society is comprised of 84 members who are experienced national leaders in the field of sports medicine who care for Division I colleges and professional teams, fellowship directors, or directors of academic sports medicine programs. Three Herodicus members were no longer active surgeons and were not sent surveys. The senior author (B.R.B.) was also excluded to eliminate the potential for “investigator bias.”

Mann-Whitney, Wilcoxon, and chi-square statistical analyses were performed where applicable. Statistical significance was $P < .05$.

RESULTS

Practice Profiles

All 80 surveyed members responded, providing a 100% response rate. For this analysis only those surgeons

who performed PCL reconstructions were included ($n=78$). The practice profiles of the survey respondents are depicted in Figure 1. The majority (79%) were in practice >15 years—63% were in private practice and 56% were in academic practice with some overlap present. Many of the surgeons were athletic team physicians with 37% ($n=29$) serving as Division I college team physicians and 24% ($n=19$) had professional team responsibilities. Thirty-six percent of surgeons were affiliated with level one trauma centers.

Frequency of Reconstruction

Compared to ACL reconstruction, PCL reconstruction is uncommon. Seventy percent ($n=54$) performed >60 ACL reconstructions per year whereas 38% performed >100 ACL reconstructions per year. In contrast, 50% performed <5 PCL reconstructions per year. Twenty-eight percent of respondents performed between 5 and 10 PCL reconstructions, and approximately 18% performed between 11 and 20 PCL reconstructions annually. Only 4% ($n=3$) performed >20 PCL reconstructions per year. When asked whether they were performing more reconstructions presently, 24% stated that they were performing more PCL reconstructions than 5 years prior. However, the number increased to 42% when compared to 10 years ago.

Fifty-one percent of respondents reported that they perform the majority of their PCL reconstructions on patients injured as a result of low-energy mechanisms, as opposed to 43% who mostly dealt with high-energy injury patterns.

When evaluating patients with acutely isolated PCL injury, 18% stated that they obtain magnetic resonance imaging (MRI) in $\leq 50\%$ of their patients. In contrast, 81% responded that they obtain MRI $\geq 80\%$ of the time. When evaluating isolated chronic PCL injuries, 53% of surgeons obtained MRI in all of their patients. When asked if they thought MRI provided prognostic information on PCL healing, 43% replied “yes.” Sixty-one percent of those surveyed used KT-1000 testing on their ACL patients; however, only 36% did so on their PCL patients. Forty-nine percent of those surveyed used a brace as part of their conservative care protocol.

Seventy-five percent of surgeons believed that isolated grade II PCL ruptures did well long term with conservative treatment, 5% disagreed, and 20% were undecided. In contrast, only 20% believed that isolated grade III injuries did well long term with nonoperative treatment. Fifty-eight percent disagreed and 22% remained undecided.

Timing of Surgery

Forty-nine percent of surgeons responded that they did not perform any isolated acute PCL reconstructions (<4 weeks). Thirty-two percent stated that they per-

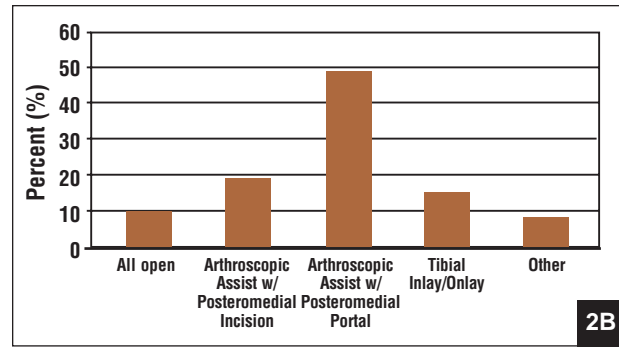
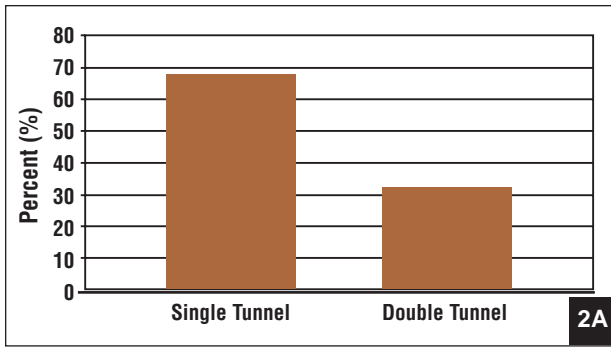


Figure 2. Preferred surgical technique on the femoral (A) and tibial (B) side in PCL reconstruction.

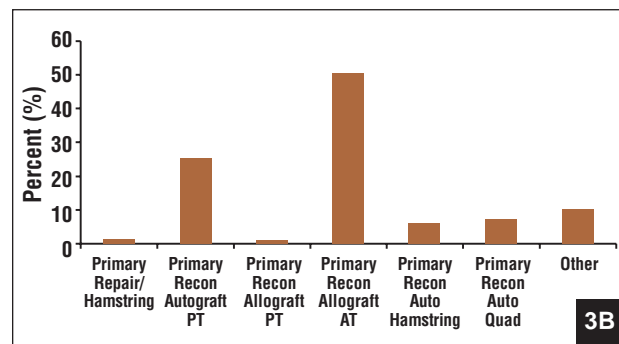
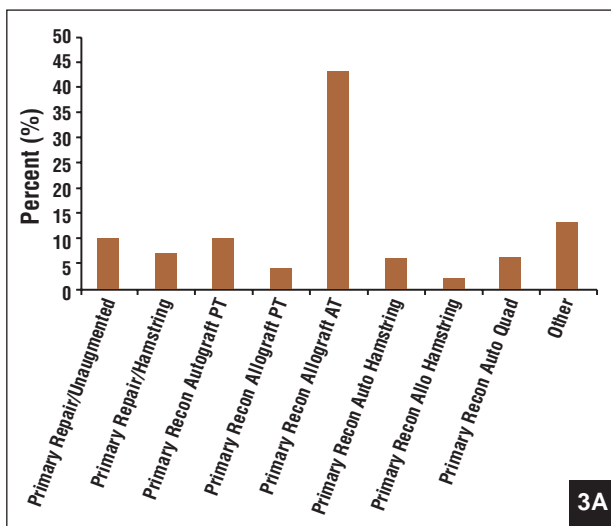


Figure 3. Surgeons' preferred graft selection for reconstruction of acute (A) and chronic (B) PCL injuries. Abbreviations: Allo=allograft, AT=Achilles tendon, Auto=autograft, PT=patellar tendon, Quad=quadriceps, and Recon=reconstruction.

formed all of their PCL reconstructions ≥ 4 weeks postinjury. The majority (97%) never operated on grade I acute PCL injuries. Additionally, 78% did not operate on grade II acute PCL injuries. In terms of chronic repairs, 84% would not repair or reconstruct a grade I injury. For the purposes of this survey, a grade III PCL injury was defined as an injury in which the posterior translation of the tibia was flush to, or posterior to, the medial femoral condyle, or had >10 mm of posterior translation.

Surgical Technique Preference

Figures 2-4 summarize the surgeons' preferences for surgical technique. Of those who performed the inlay/onlay technique, 38% positioned their patients supine and then prone-supine, 28% used the contralateral position, and 7% the ipsilateral decubitus position. Twenty-four percent positioned their patients supine for the entire surgical case.

The most commonly used graft for acute and chronic PCL surgery was allograft Achilles tendon. Figure 3 summarizes the surgeons' preferences with respect to graft choice. Biomechanical graft strength was the most impor-

tant graft selection factor according to 74% of respondents; 10% chose biomechanical fixation strength. Ease of graft passage, graft tissue access, and rehabilitation considerations were the remaining graft selection factors that had similar numbers of respondents. A majority of the surgeons (89%) believed their graft selection allowed for early range of motion exercises.

Fifty-five percent of surgeons tensioned their grafts in 71°-90° of knee flexion. Of these, tensioning in 81°-90° of knee flexion was favored 2:1. Graft tensioning in full extension was favored in 16%. An additional 16% preferred 30°-40° of knee flexion. The remainder of those surveyed chose varying increments of knee flexion ranging from 41°-70°. Figure 4 depicts the surgeons' preferences for graft fixation.

Postoperatively, 45% of surgeons allowed their patients immediate weight bearing. The next most frequent response was weight bearing at 2 weeks (15%). Eleven percent began weight bearing at 4-5 weeks, and 10% delayed weight bearing until 6-7 weeks.

A significant difference in technique was noted when comparing those who performed ≤ 10 PCL reconstructions

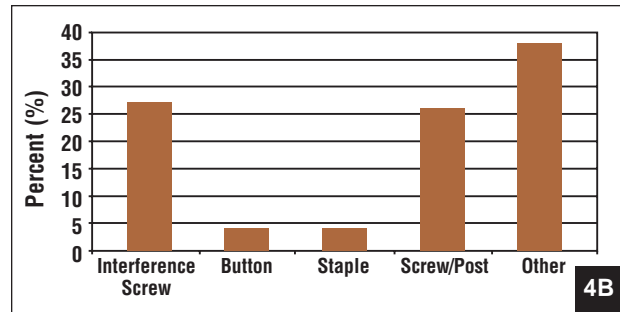
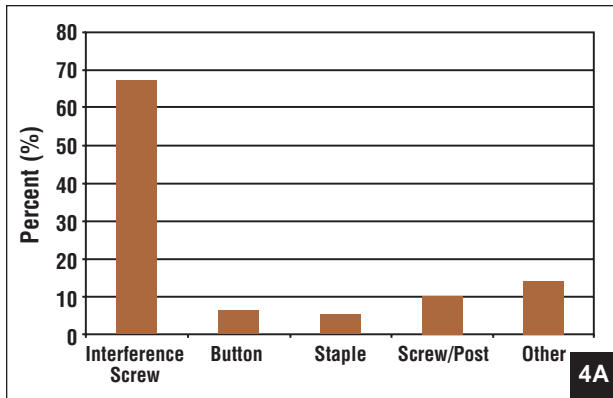


Figure 4. Preferred surgical technique of femoral (A) and tibial (B) fixation in PCL reconstruction.

per year (61 surgeons, group 1) versus >10 PCL reconstructions per year (17 surgeons, group 2). In group 1, 25% of surgeons used a double tunnel technique versus 59% of surgeons in group 2 ($P=0.016$, chi-square). The inference in this observation is that those surgeons who were most experienced were performing a more demanding technique (“double bundle”) in an attempt to improve stability.

DISCUSSION

The present survey represents the thoughts and opinions of a group of knowledgeable and experienced knee ligament surgeons. The potential weaknesses of this study center on the nature of a study whereby the responses may be predicated on recollection, perception, and lack of scientific methodology. Surveys are limited in that they are subject to interpretation bias and can contain leading questions. However, the authors believe the results of this survey represent the trends in current practice of PCL reconstruction.

The reported incidence of PCL injuries among all knee injuries varies between 3% and 37%.^{10,11} According to the literature, the natural history of isolated PCL tears is relatively benign. Natural history studies have suggested that in short and intermediate follow-up, PCL-deficient athletes functioned well despite obvious clinical laxities.^{2,16,26,28,31} Furthermore, a 2%-5% incidence of unrecognized PCL-deficiency has been noted in elite college football players.²⁶ Fowler and Messieh¹² prospectively followed 13 athletes with isolated PCL injuries who were treated with physical therapy. At follow-up, all patients returned without limitation to their previous activities despite having slight translation on posterior drawer testing.

Parolie and Bergfeld²⁶ followed 25 athletes with isolated PCL tears and evaluated them at a mean of 6.2 years after injury. Eighty percent of patients were satisfied with their results, and 84% had returned to their previous sport. They reported that those athletes who were able to maintain quadriceps strength were also able to return to their

competitive sport without requiring surgery.²⁶ Furthermore, Torg et al³¹ reported 86% good to excellent results in a series of 14 patients with isolated PCL instability managed nonoperatively.

In a large series of 133 athletes with isolated PCL instability treated nonoperatively and prospectively followed for an average of 5.4 years, Shelbourne et al²⁸ found little change in laxity rating from the initial injury to final follow-up. In light of the natural history, isolated acute PCL injuries were not routinely reconstructed. If posterior translation was <10 mm (grade II or less) on physical examination, a nonoperative rehabilitation course was recommended.

Veltri and Warren³² recommended nonoperative management with physical therapy for most patients with a chronic PCL deficiency. In such cases, the degree of posterior translation was factored along with the presence of symptoms, results of imaging studies, and the results of nonoperative rehabilitation. Patients with grade III laxity who failed aggressive rehabilitation were considered for surgical reconstruction. Accordingly, 75% of the surveyed surgeons in this study believed that isolated grade II PCL ruptures do well long term with conservative treatment. In contrast, only 20% believed that isolated grade III injuries did well long term with nonoperative treatment. The majority (97%) never acutely operated on grade I PCL injuries. Additionally, 78% would not acutely operate on grade II PCL injuries. In terms of chronic injuries, 84% of those surveyed would not repair or reconstruct a grade I injury.

Magnetic resonance imaging is highly sensitive in establishing the diagnosis and location of an acute PCL tear.¹⁶ Gross et al¹⁵ showed that MRI was 100% sensitive and specific in the diagnosis of PCL injuries. Furthermore, it often is helpful in identifying concomitant lesions.^{9,16,32} Similar to medial collateral ligament tears, some evidence suggests that a torn PCL heals in an elongated position. Therefore, chronic PCL tears may appear relatively normal on MRI.²⁹ In contrast to ACL injuries, meniscal tears and bone bruises are less com-

monly seen with PCL tears.^{28,32} In this survey, 81% of surgeons obtained MRI the majority of the time.

The KT-1000 arthrometer (MEDmetric Corp, San Diego, Calif) can be used to quantify posterior translation in an objective manner. It can be especially useful when trying to compare postoperative results. However, some authors^{26,31} reported poor correlation between posterior laxity measured by arthrometer and functional status. In this survey, 61% of surgeons used this device on their ACL patients; however, only 36% did so on their PCL patients. We did not question the use of the Telos stress device to quantify posterior translations.

Single graft bundles performed through a single femoral tunnel have been performed in open and arthroscopic PCL reconstructions. As the anterolateral bundle is larger and stronger, the femoral tunnel is drilled where the anterolateral fibers of the PCL originate on the femoral condyle. Arthroscopic single-bundle techniques decrease posterior laxity and are technically less demanding than double-bundle techniques, but do not restore normal mechanics. Slightly eccentric placement of the femoral attachment of single-bundle PCL reconstruction results in minor graft force reductions, which are relatively small compared to the magnitude of physiologic loads on the knee.¹¹ Although single-bundle PCL reconstruction limits posterior translation of the tibia, it has not been shown to restore normal 6° of freedom knee mechanics under physiologic muscle load testing, implying a higher propensity to lead to early arthrosis.^{13,14} Cadaver studies have demonstrated that a double-bundle PCL reconstruction creates physiologic knee motion with a codominance between the anterolateral and posteromedial bundle depending on flexion angle; each bundle provides comparable amounts of relative restraint in various knee positions.¹

Support exists for a combination of tibial inlay and double-bundle femoral construct.²² A prospective cohort study of 30 tibial inlay, double-bundle PCL reconstructions demonstrated good results of laxity, range of motion, and Lysholm knee scores at 2 years, which compare favorably to historical outcomes of traditional PCL reconstructions, implicating the importance of anatomic graft construct and location.³⁰

Double-bundle techniques have been introduced in an attempt to reproduce the complex PCL anatomy more accurately. The double-bundle technique also replaces the posteromedial fibers and is believed to be biomechanically superior. In a recent cadaver study, Harner et al¹⁷ demonstrated that use of the double-bundle technique decreased posterior laxity by 3.5 mm. Additionally, the double reconstruction was found to more effectively reproduce intact knee kinematics and in situ forces across the full range of motion.¹⁷ The primary disadvantage of the double-bundle method is that it is technically challenging and controversies remain regarding the correct

orientation of the bundle. In this survey, approximately one third of the surgeons (32%) perform double tunnel reconstructions on the femoral side, whereas 68% use a single femoral tunnel. However, after stratifying our results, 59% of group II surgeons (those who perform >10 PCL reconstructions annually) used a double-bundle technique.

Often an Achilles tendon or quadriceps allograft is used for a double-bundle PCL reconstruction. However, for patients wishing to avoid allograft tissue, quadriceps tendon autograft has been described as a useful graft for double-bundle reconstruction of the PCL in both isolated PCL injuries and multiple ligament injured knees.²⁷

Newer double-bundle and tibial inlay techniques should theoretically offer greater stabilization but the available clinical data is only preliminary. In 1995, Berg³ described the tibial inlay technique. The advantages of this method include avoiding the technical difficulties associated with the tibial tunnel and graft passage as well as avoiding neurovascular structures.²³ Additionally, Berg³ reported improvement in all four of his study patients at minimum 2-year follow-up. Postoperative KT-1000 arthrometer measurements demonstrated a 4-mm decrease in posterior translation preoperatively to within 2 mm of the contralateral normal side.³ Patient positioning and exposure remain challenges with this technique.

Enhanced tibial fixation may be traded for a potentially less stable femoral fixation.¹⁶ Approximately 15% of those surveyed perform the tibial inlay technique. As the tibial inlay technique had not yet been described at the time of our original study,² positioning and access to the posterior knee is challenging. In this survey, 38% of respondents preferred “flip-flopping” the patient (ie, supine/prone/supine position), 28% preferred a lateral decubitus position with the contralateral extremity dependent, and 24% preferred a supine approach. The latter approach necessitates rotating (“airplaning”) the operating room table and flexing and externally rotating the hip to access the posterior knee.

Patellofemoral pain, extensor mechanism morbidity, residual thigh girth atrophy, and isokinetic evidence of residual quadriceps weakness are acknowledged problems associated with ACL surgery in general and the use of patella tendon autograft, specifically. Due to the fact that patients with PCL-deficient knees have posterior “sag” and “drop back,” physical examination signs that can result in increased patellofemoral contact pressures and patellofemoral symptoms, this factor must be considered when considering an autogenous patella tendon graft. The use of bone-patella tendon-bone autograft was popularized 20 years ago. Clancy et al^{6,7} reported the efficacy of this graft technique in an animal model and in a series of patients. In contrast to ACL reconstruction, graft passage using patellar tendon can be difficult. The graft

must be passed through longer bone tunnels, and the path traversed is in a “zig-zag” direction. Inadequate tissue debridement on the posterior tibia may contribute to the difficulty of graft passage.

The use of hamstrings or allograft tissue is appealing in patients with pre-existing patellofemoral symptoms.⁹ However, graft fixation is an important issue to consider because a screw and post, staple, or ligament button is generally required.

Allograft patellar tendon is an alternative graft source. It is advantageous in that it avoids donor-site morbidity and allows use of a larger width graft. Additionally, graft preparation by an assistant may reduce surgical time. Issues of graft passage and fixation are identical to that of autograft patella tendon. One major disadvantage of allograft tissue is the potential transmission of bacterial or viral illness. The likelihood of contracting the human immunodeficiency virus from an allograft is <1 in 1.8 million when donor selection, viral screening, and histopathologic studies are conducted.⁴

Several major advantages of Achilles tendon allograft exist. It has a large cross-sectional area of collagen, abundant length, ease of graft passage, and the ability to obtain rigid bone fixation at one end of the graft.^{9,16} On the tibial side, the Achilles tendon allograft requires soft-tissue fixation. Similar to patella tendon allograft, lack of donor-site morbidity and shortened preparation time are advantages. Additionally, it has the same potential for disease transmission and healing as patellar tendon allograft. In contrast to a previous survey of the Herodicus Society membership² in which autogenous middle third patella tendon was the most commonly preferred graft in acute and chronic knees, the graft of choice in the present study was an Achilles tendon allograft. However, similar to the previous survey the respondents primarily favored graft strength followed by graft fixation as the most important considerations for graft selection.

Burns et al⁵ reported that fixation at 90° of knee flexion under an applied anterior draw of the knee was superior to fixation at full extension. In the present study, 55% of surgeons tension their grafts in 71°-90° of knee flexion. Of these, tensioning in 81°-90° of knee flexion was favored 2:1. Some surgeons prefer to tension the graft in extension so that the bony contours of the joint are matched.

Harner and Hoher¹⁶ support the use of interference screw fixation on the femoral side, however, caution against the use of interference screw fixation on the tibial side due to its decreased purchase in soft cancellous bone. Interference screw fixation was used by 67% of the respondents on the femoral side and by 27% on the tibial side (Figures 6 and 7). Of note is that 35% of the surgeons used supplemental fixation on the tibia.

Femoral fixation of soft-tissue hamstring grafts with an Endobutton (Smith & Nephew, Andover, Mass) results in

greater plastic deformation after 500 cycles, when compared to rigid bone fixation with interference screw on the femur and either tunnel interference screw or inlay technique on the tibia.¹⁹ Tibial bone block fixation ability to withstand cyclic loading depends on the depth and orientation of the bone block, with best results when the bone block is positioned flush with the surface of the posterior tibia, and rotated to face anteriorly within the tunnel.²⁰

Techniques have been developed to reduce the difficulty of graft passage at the posterior tibia “killer turn.” A lower approach angle in the tibia via an entry on the lateral aspect of the tibia in the posterior third of the tibia allows for less graft angulation in the posterior tibia and permits inside-out femoral drilling. This technique eliminates the need for a second incision, which has allowed for easier postoperative recovery in one series.²⁵ Biomechanical studies demonstrate that using a lower approach angle in the tibia does not cause a loss of graft compression or result in increased joint translation.¹⁸ The importance of avoiding a medial displacement of the PCL on the tibia has been demonstrated. In a cadaver study, 5-mm errors in medial-lateral placement of the tibial tunnel did not have significant effects on the biomechanical characteristics of the reconstructed knee in most positions, but higher graft forces >65° of flexion were associated with a tibia tunnel that was 5 mm medial to the center of the PCL footprint.²¹

Treatment of the PCL injured knee remains challenging. The timing of patient presentation impacts the injury interpretation. For example, because of the potential healing capacity of interstitial injuries, what may be interpreted as a high grade II or low grade III posterior translation may be interpreted as a high grade I injury 6-12 weeks later as the PCL “tightens up.” Coexistent injuries may also impact the treatment as an associated posterolateral corner dictates more aggressive earlier surgical treatment. The chronic PCL-deficient patient who presents late with pain and instability complaints frequently has significant chondral pathology and surgical reconstruction may be too late. The role of biplanar osteotomies are being explored for these situations.

During the past decade this infrequently injured ligament has received attention at sports medicine conferences and academic meetings. Ideal treatment continues to remain unanswered, but many of the puzzle pieces are starting to fit into place. It will be fascinating to repeat this survey in a decade to evaluate evolving trends.

REFERENCES

1. Ahmad CS, Cohen ZA, Levine WN, Gardner TR, Ateshian GA, Mow VC. Codominance of the individual posterior cruciate ligament bundles. An analysis of bundle lengths and orientation. *Am J Sports Med.* 2003;31:221-225.
2. Bach BR. Graft selection for posterior cruciate ligament

- surgery. *Operative Techniques in Sports Medicine*. 1993;1:104-109.
3. Berg EE. Posterior cruciate ligament tibial inlay reconstruction. *Arthroscopy*. 1995;11:69-76.
 4. Buck BE, Malinin TI, Brown MD. Bone transplantation and human immunodeficiency virus. An estimate of risk of acquired immunodeficiency syndrome (AIDS). *Clin Orthop*. 1989;240:129-136.
 5. Burns WC II, Draganich LF, Pyevich M, Reider B. The effect of femoral tunnel position and graft tensioning technique on posterior laxity of the posterior cruciate ligament-reconstructed knee. *Am J Sports Med*. 1995;23:424-430.
 6. Clancy WG Jr, Narechania RG, Rosenberg TD, Gmeiner JG, Wisnefske DD, Lange TA. Anterior and posterior cruciate ligament reconstruction in rhesus monkeys. *J Bone Joint Surg Am*. 1981;63:1270-1284.
 7. Clancy WG Jr, Shelbourne KD, Zoellner GB, Keene JS, Reider B, Rosenberg TD. Treatment of knee joint instability secondary to rupture of the posterior cruciate ligament. Report of a new procedure. *J Bone Joint Surg Am*. 1983;65:310-322.
 8. Cosgarea AJ, Jay PR. Posterior cruciate ligament injuries: evaluation and management. *J Am Acad Orthop Surg*. 2001;9:297-307.
 9. Covey CD, Sapega AA. Injuries of the posterior cruciate ligament. *J Bone Joint Surg Am*. 1993;75:1376-1386.
 10. Fanelli GC. Posterior cruciate ligament injuries in trauma patients. *Arthroscopy*. 1993;9:291-294.
 11. Fanelli GC, Edson CJ. Posterior cruciate ligament injuries in trauma patients: part II. *Arthroscopy*. 1995;11:526-529.
 12. Fowler PJ, Messieh SS. Isolated posterior cruciate ligament injuries in athletes. *Am J Sports Med*. 1987;15: 553-557.
 13. Giffin JR, Haemmerle MJ, Vogrin TM, Harner CD. Single- versus double-bundle PCL reconstruction: a biomechanical analysis. *J Knee Surg*. 2002;15:114-120.
 14. Gill TJ, DeFrate LE, Wang C, et al. The biomechanical effect of posterior cruciate ligament reconstruction on knee joint function. Kinematic response to simulated muscle loads. *Am J Sports Med*. 2003;31:530-536.
 15. Gross ML, Grover JS, Bassett LW, Seeger LL, Finerman GA. Magnetic resonance imaging of the posterior cruciate ligament. Clinical use to improve diagnostic accuracy. *Am J Sports Med*. 1992;20:732-737.
 16. Harner CD, Hoher J. Evaluation and treatment of posterior cruciate ligament injuries. *Am J Sports Med*. 1998;26:471-482.
 17. Harner CD, Janaushek MA, Kanamori A, Yagi M, Vogrin TM, Woo SL. Biomechanical analysis of a double-bundle posterior cruciate ligament reconstruction. *Am J Sports Med*. 2000;28:144-151.
 18. Huang TW, Wang CJ, Weng LH, Chan YS. Reducing the "killer turn" in posterior cruciate ligament reconstruction. *Arthroscopy*. 2003;19: 712-716.
 19. Kitamura N, Yasuda K, Yamanaka M, Tohyama H. Biomechanical comparisons of three posterior cruciate ligament reconstruction procedures with load-controlled and displacement-controlled cyclic tests. *Am J Sports Med*. 2003;31:907-914.
 20. Markolf K, Davies M, Zoric B, McAllister D. Effects of bone block position and orientation within the tibial tunnel for posterior cruciate ligament graft reconstructions: a cyclic loading study of bone-patellar tendon-bone allografts. *Am J Sports Med*. 2003;31:673-679.
 21. Markolf KL, McAllister DR, Young CR, McWilliams J, Oakes DA. Biomechanical effects of medial-lateral tibial tunnel placement in posterior cruciate ligament reconstruction. *J Orthop Res*. 2003;21:177-182.
 22. Noyes FR. Anatomic reconstruction of the posterior cruciate ligament after multiligament knee injuries. A combination of the tibial-inlay and two-femoral-tunnel techniques. *Am J Sports Med*. 2003;31:812-813.
 23. Oakes DA, Markolf KL, McWilliams J, Young CR, McAllister DR. Biomechanical comparison of tibial inlay and tibial tunnel techniques for reconstruction of the posterior cruciate ligament. Analysis of graft forces. *J Bone Joint Surg Am*. 2002;84:938-944.
 24. Oakes DA, Markolf KL, McWilliams J, Young CR, McAllister DR. The effect of femoral tunnel position on graft forces during inlay posterior cruciate ligament reconstruction. *Am J Sports Med*. 2003;31:667-672.
 25. Ohkoshi Y, Nagasaki S, Yamamoto K, et al. Description of a new endoscopic posterior cruciate ligament reconstruction and comparison with a 2-incision technique. *Arthroscopy*. 2003;19:825-832.
 26. Parolie JM, Bergfeld JA. Long-term results of nonoperative treatment of isolated posterior cruciate ligament injuries in the athlete. *Am J Sports Med*. 1986;14:35-38.
 27. Richards RS II, Moorman CT III. Use of autograft quadriceps tendon for double-bundle posterior cruciate ligament reconstruction. *Arthroscopy*. 2003;19:906-915.
 28. Shelbourne KD, Davis TJ, Patel DV. The natural history of acute, isolated nonoperatively treated posterior cruciate ligament injuries. A prospective study. *Am J Sports Med*. 1999;27:276-283.
 29. Shelbourne KD, Jennings RW, Vahey TN. Magnetic resonance imaging of posterior cruciate ligament injuries: assessment of healing. *Am J Knee Surg*. 1999;12:209-213.
 30. Stannard JP, Riley RS, Sheils TM, McGwin G Jr, Volgas DA. Anatomic reconstruction of the posterior cruciate ligament after multiligament knee injuries. A combination of the tibial-inlay and two-femoral-tunnel techniques. *Am J Sports Med*. 2003;31:196-202.
 31. Torg JS, Barton TM, Pavlov H, Stine R. Natural history of the posterior cruciate ligament-deficient knee. *Clin Orthop*. 1989;246:208-216.
 32. Veltri DM, Warren RF. Isolated and combined posterior cruciate ligament injuries. *J Am Acad Orthop Surg*. 1993;1:67-75.