

# Femoral Tunnel Placement in Single-Bundle Anterior Cruciate Ligament Reconstruction

## A Cadaveric Study Relating Transtibial Lateralized Femoral Tunnel Position to the Anteromedial and Posterolateral Bundle Femoral Origins of the Anterior Cruciate Ligament

John-Paul H. Rue, MD, Neil Ghodadra, MD, and Bernard R. Bach, Jr,\* MD

*From the Division of Sports Medicine, Department of Orthopaedic Surgery, Rush University Medical Center, Chicago, Illinois*

---

**Background:** There is controversy regarding the necessity of reconstructing both the posterolateral and anteromedial bundles of the anterior cruciate ligament.

**Hypothesis:** A laterally oriented transtibial drilled femoral tunnel replaces portions of the femoral footprints of the anteromedial and posterolateral bundles of the anterior cruciate ligament.

**Study Design:** Descriptive laboratory study.

**Methods:** Footprints of the anteromedial and posterolateral bundles of the anterior cruciate ligament were preserved on 7 matched pairs (5 female, 2 male) of fresh-frozen human cadaveric femurs (14 femurs total). Each femur was anatomically oriented and secured in a custom size-appropriate, side-matched replica tibia model to simulate transtibial retrograde drilling of a 10-mm femoral tunnel in each specimen. The relationship of the tunnel relative to footprints of both bundles of the anterior cruciate ligament was recorded using a Microscribe MX digitizer. The angle of the femoral tunnel relative to the vertical 12-o'clock position was recorded for all 14 specimens; only 10 specimens were used for footprint measurements.

**Results:** On average, the 10-mm femoral tunnel overlapped 50% of the anteromedial bundle (range, 2%-83%) and 51% of the posterolateral bundle (range, 16%-97%). The footprint of the anteromedial bundle occupied 32% (range, 3%-49%) of the area of the tunnel; the footprint of the posterolateral bundle contributed 26% (range, 7%-41%). The remainder of the area of the 10-mm tunnel did not overlap with the anterior cruciate ligament footprint. The mean absolute angle of the femoral tunnel as measured directly on the specimen was 48° (range, 42°-53°) from vertical, corresponding to approximately a 10:30 clock face position on a right knee.

**Conclusion:** Anterior cruciate ligament reconstruction using a laterally oriented transtibial drilled femoral tunnel incorporates portions of the anteromedial and posterolateral bundle origins of the native anterior cruciate ligament.

**Clinical Relevance:** A laterally oriented transtibial drilled femoral tunnel placed at the 10:30 position (1:30 for left knees) reconstructs portions of the anteromedial and posterolateral bundles of the anterior cruciate ligament.

**Keywords:** anterior cruciate ligament (ACL); single bundle; reconstruction; femoral tunnel

---

Current techniques to reconstruct the ACL focus on replacing the native 2-bundle ACL with a single-bundle graft.

\*Address correspondence to Bernard R. Bach, Jr, MD, Department of Orthopaedic Surgery, Rush University Medical Center, 1653 West Congress Parkway, 1471 Jelke, Chicago, IL 60612 (e-mail: brbachmd@comcast.net).

No potential conflict of interest declared.

The American Journal of Sports Medicine, Vol. X, No. X  
DOI: 10.1177/0363546507311093  
© 2007 American Orthopaedic Society for Sports Medicine

There is debate regarding the need to reconstruct both the posterolateral (PL) and anteromedial (AM) bundles of the ACL. The controversy has evolved out of the recognition that many surgeons inadvertently create a vertically oriented graft that may not adequately restore either the translational or rotational kinematic properties of an intact knee. A vertical femoral tunnel has been cited as 1 of the most common causes for failure of ACL reconstruction.<sup>12,21,22</sup> Such failures often have symptomatic instability and a positive pivot-shift result on physical examination yet demonstrate a normal

Lachman test result. Since the initial description of double-bundle reconstruction by Mott in 1983,<sup>27</sup> several authors have described techniques to successfully reconstruct both bundles.<sup>6,7,36,39</sup> Two-bundle ACL reconstruction necessitates the creation of 2 separate bone tunnels on the femur and tibia.

The controversial issue is whether a single-bundle ACL reconstruction with an appropriately placed femoral tunnel within the anatomical footprint of the native ACL provides the same stability as does a double-bundle reconstruction. There are few studies that have compared the results of both techniques. Jarvela<sup>19</sup> reported his results from 65 patients randomized to either a double-bundle ( $n = 35$ ) or single-bundle ( $n = 30$ ) ACL reconstruction technique using hamstring grafts and bioabsorbable interference screws. At a mean follow-up of 14 months, the double-bundle group had significantly better rotational stability, as evaluated by the pivot-shift test, than did the single-bundle group, but there was no difference in anterior stability.

Other studies have compared single- versus double-bundle reconstructions without finding significant differences in measured stability. Adachi et al<sup>1</sup> prospectively compared single- versus double-bundle ACL reconstruction and found no difference in stability or proprioception. In another prospective comparison, Hamada et al<sup>15</sup> also found no difference between single- and double-bundle reconstructions in terms of measured stability or subjective results. Asagumo et al<sup>3</sup> retrospectively reviewed 123 consecutive patients reconstructed with either a double-bundle ( $n = 71$ ) or single-bundle ( $n = 52$ ) ACL reconstruction technique with a mean follow-up of 33 months. Eighty-seven percent of the patients in the double-bundle group had a negative pivot-shift result versus 81% in the single-bundle group. They found no significant difference in measured stability; however, there was a significant difference in range of motion between the groups ( $P < .05$ ), with 19 patients (26%) in the double-bundle group and 6 (10%) in the single-bundle group having an extension deficit of greater than 5°. They went on to conclude that their results did not support the routine use of a double-bundle ACL reconstruction technique. A recent cadaveric study further highlighted several of the potential technical difficulties associated with double-bundle ACL reconstruction techniques. Giron et al<sup>14</sup> demonstrated that anatomical femoral tunnel guide wire positioning in the AM and PL bundles was possible through a transtibial approach, but even in a controlled cadaveric setting, this was not reproducible, and many guide wires were outside of the anatomical femoral origins of the AM and PL bundles.

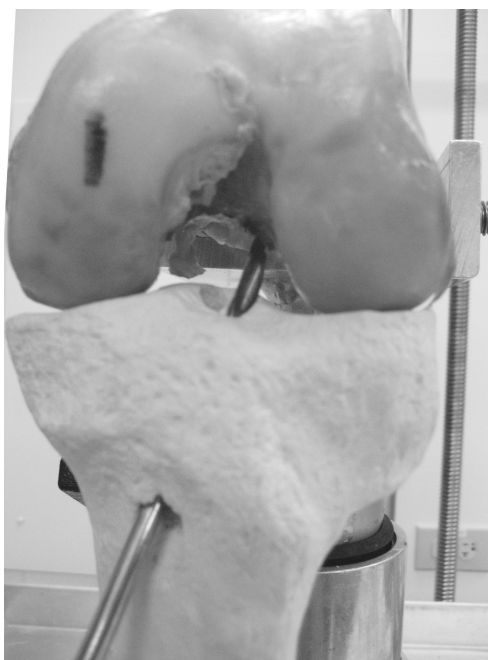
The objective of this study was to quantitatively assess the overlap of a lateralized 10-mm femoral tunnel on the AM and PL bundle footprints using a lateralized, transtibial, drilled femoral tunnel and to compare the relationship of the centroids of the 10-mm femoral tunnel to the AM and PL bundle footprints. Our hypothesis was that a laterally oriented, transtibial, drilled femoral tunnel replaces portions of the femoral footprints of both the AM and PL bundles of the ACL.

## MATERIALS AND METHODS

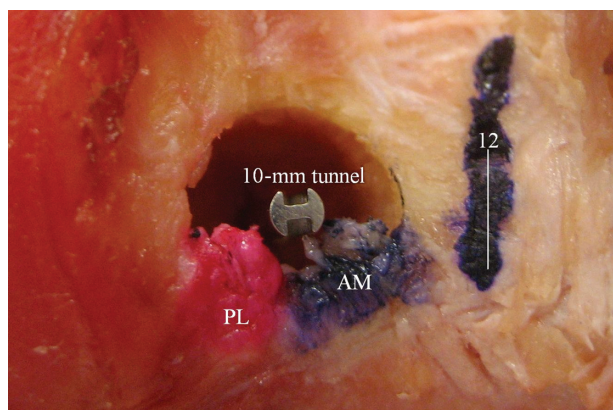
The footprints of the AM and PL bundles of the ACL were preserved on 14 fresh-frozen human cadaveric femurs. The mean age of the specimens was 55.3 years (range, 51-59 years). A foam cortical shell replica tibia model (Sawbones, Vanshon, Wash) jig was chosen to minimize the variability of the tibial tunnel position in the experimental design. Two tibia models (medium and large) for each side were used to minimize size mismatch with the cadaveric femurs. For each replica tibia, the tibial tunnel was drilled at an approximate angle of 60° to the joint surface in the coronal plane, with the starting point between the tibial tubercle and the medial aspect of the tibia, using a standard ACL guide (Acufex, Smith and Nephew Endoscopy, Andover, Mass) set at 55°. The intra-articular exit point of the tibial guide pin was approximately 5 mm lateral to the medial tibial spine and 3 to 4 mm posterior to where the posterior edge of the anterior horn of the lateral meniscus would lie. The guide pin was then overreamed with a 10-mm cannulated acorn reamer.

Each femur was secured in the custom jig simulating approximately 85° to 90° of flexion, with the anterior aspect of the size-appropriate, side-matched tibia approximately 1 cm anterior to the femur in neutral rotation and centered medial-to-lateral to replicate transtibial retrograde drilling of a 10-mm femoral tunnel as would be done for a standard bone-patellar tendon-bone graft. A commercially available 7-mm femoral offset aimer (Conmed Linvatec, Largo, Fla) was passed retrograde via the tibial tunnel of the model and placed in the over-the-top position on the posterior cortex of the femur and then rotated laterally to further lateralize the position of the femoral guide pin according to a standard endoscopic technique<sup>16</sup> (Figure 1). A 3/32-in smooth Steinman pin was drilled through the aiming device, and the aiming device was removed. The Steinman pin was overreamed with a 10-mm cannulated acorn reamer, replicating what is performed intraoperatively. Careful reaming was performed to allow for the preservation of the soft tissue (Figure 2). The relationship of the 10-mm femoral tunnel relative to the preserved footprints of the AM and PL bundles of the ACL was recorded relative to the 12-o'clock position on the intercondylar notch at the posterior cortex using a Microscribe MX digitizer (Immersion, San Jose, Calif). These measurements were performed twice for each of the specimens, and the results were averaged.

The 3-dimensional position of the centroids of the AM and PL bundles and femoral tunnel was calculated by dividing the polygons representing the AM and PL bundles into triangles. The area and centroid of each triangle were calculated, and then each bundle's centroid was computed as the sum of the weighted averages of the centroids of the triangles composing each polygon. A weighted proximity value, representing the relative proximity of the centroid of the femoral tunnel to the centroids of the AM and PL bundles, was calculated using the ratio of the distance from the 10-mm femoral tunnel centroid to the AM bundle centroid compared with the distance from the 10-mm femoral tunnel centroid to the PL bundle centroid.

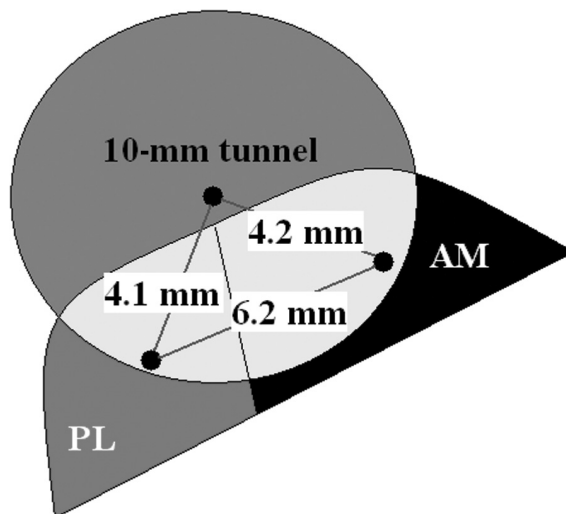


**Figure 1.** Transtibial femoral tunnel drilling jig using saw bone tibia and 7-mm femoral offset aimer.



**Figure 2.** Cadaveric specimen showing preserved anteromedial (AM) and posterolateral (PL) bundle origins overlapping 10-mm femoral tunnel.

The angle of the femoral guide pin relative to the vertical 12-o'clock position was measured in degrees for each specimen, representing the angle of the femoral tunnel relative to the vertical 12-o'clock position. Absolute measurement angles from vertical for both right and left knees were averaged and then translated to the corresponding "time" position on a clock face using a formula whereby each 30° equals 1 hour on a clock face. For example, an absolute femoral tunnel angle of 60° from vertical translates to a right knee clock face position of 10 o'clock; an angle of 45° from vertical corresponds to a right knee clock face position of 10:30, or halfway between the 10- and 11-o'clock positions. All clock face values are given as viewed for a right knee. All angle or area measurements are rounded to the nearest percentage or degree and distance measurements to 1 decimal point.



**Figure 3.** Graphic representation of the centroids of the femoral tunnel and anteromedial (AM) and posterolateral (PL) bundles.

The angle of the femoral tunnel relative to the vertical 12-o'clock position was recorded for all 14 specimens; however, only 10 specimens were used for footprint measurements. Four specimens were excluded because of technical difficulties involving the femoral tunnel and the preserved footprints. In these specimens, the AM and PL bundle footprints were not adequately preserved to accurately measure the overlap of the femoral tunnel, leaving 10 specimens available for analysis.

### RESULTS

The mean distance from the centroid of the 10-mm femoral tunnel to the centroids of the AM and PL bundles was 4.2 mm (range, 2.3-6.0 mm; SD, 1.5 mm) and 4.1 mm (range, 2.7-6.0 mm; SD, 1.2 mm), respectively. The mean distance between the centroids of the AM and PL bundle origins was 6.2 mm (range, 4.1-8.2 mm; SD, 1.2 mm). The weighted proximity of the centroid of the femoral tunnel to the centroid of the AM bundle and PL bundle was 1.1 mm (range, 0.7-2.2 mm; SD, 0.5 mm), demonstrating that the centroid of the 10-mm femoral tunnel was slightly closer to the PL centroid than to the AM centroid (Figure 3).

On average, the 10-mm femoral tunnel overlapped 50% of the AM bundle (range, 2%-83%; SD, 23%) and 51% of the PL bundle (range, 16%-97%; SD, 24%) (Table 1). The 10-mm femoral tunnel was composed of 32% AM bundle (range, 3%-49%; SD, 14%) and 26% PL bundle (range, 7%-41%; SD, 11%). Overall, the 10-mm femoral tunnel was 58% (range, 38%-84%; SD, 17%) covered by the ACL origin (Table 2).

The mean absolute angle of the femoral tunnel as measured directly on the specimen was 48° (range, 42°-53°; SD, 4°) from vertical, corresponding to approximately the 10:30 clock face position on a right knee. There was no significant side-to-side difference ( $P = .23$ ) in the mean femoral tunnel angle from vertical (right, 49°; left, 47°) for the femoral specimens.

TABLE 1  
Femoral Tunnel Overlap

	Percentage <sup>a</sup>	
	Anteromedial	Posterolateral
Mean	50	51
Range	2-83	16-97
SD	23	24

<sup>a</sup>Percentage of anteromedial bundle origin area overlapped by 10-mm femoral tunnel and percentage of posterolateral bundle origin area overlapped by 10-mm femoral tunnel.

TABLE 2  
Femoral Tunnel Composition

	Percentage <sup>a</sup>		
	AM	PL	Combined AM/PL
Mean	32	26	58
Range	3-49	7-41	38-84
SD	14	11	17

<sup>a</sup>Percentage of 10-mm femoral tunnel area composed of anteromedial (AM) bundle origin and percentage of 10-mm femoral tunnel area composed of posterolateral (PL) bundle origin.

## DISCUSSION

To our knowledge, this is the first study relating a lateralized 10-mm femoral tunnel to the origins of the AM and PL bundles during single-bundle ACL reconstruction using a transtibial drilled femoral tunnel. This study confirms the clinical observations that a laterally oriented femoral tunnel placed at approximately the 10:30 position for a right knee (1:30 for a left knee) reconstructs portions of both the AM and PL bundles of the ACL.

Yasuda et al<sup>38</sup> described the anatomy of the AM and PL bundles, demonstrating that the center of their femoral attachments corresponded to a 10:30 position on the intercondylar wall (1:30 for left knees). The findings of our present study reinforce this description and further illustrate the anatomical relationship by graphically portraying the overlap of a laterally oriented femoral tunnel on the origins of portions of both the AM and PL bundles.

Anterior cruciate ligament reconstruction techniques have traditionally focused on reconstruction of the ACL with a single-bundle graft. The work by Jomha et al<sup>23</sup> demonstrated that acute ACL reconstruction with a single-bundle technique and meniscal preservation provided the lowest incidence of osteoarthritis among a group of 72 patients who had undergone ACL reconstruction at various time intervals after injury. They concluded that reconstruction of ACL-deficient knees should be done before episodes of giving way to minimize the potential for future development of osteoarthritis. Recently, several authors have shown increasing functional instability and degenerative radiographic changes after single-bundle ACL reconstruction.<sup>20,30,35</sup> The current trend in ACL reconstruction

techniques is to more closely restore the anatomical footprint and kinematics of the ACL through a more laterally positioned femoral tunnel, which replaces portions of both the PL and AM bundles.<sup>10,25</sup>

Clinical outcome studies in patients using lateralized single-bundle femoral tunnel ACL reconstruction techniques have yielded good results.<sup>4,5</sup> In a cadaveric study, a more lateral placement of the femoral tunnel has been shown to better reproduce the normal ACL's U-shaped tension curve during passive extension and flexion.<sup>2</sup> In addition, some surgeons have advocated a more lateral femoral tunnel placement to increase the moment arm in ACL reconstruction.<sup>9,17,33</sup> Using a clock face description, this represents placing the aperture of the femoral tunnel more toward the 10-o'clock position for a right knee (2-o'clock position for a left knee). In a cadaveric anatomical study, Mochizuki et al<sup>26</sup> described the centers of the AM and PL bundles at 10:20 and 8:50, respectively, for a right knee (1:40 and 3:10 positions, respectively, for a left knee). To our knowledge, no prior studies to date have correlated the placement of a lateralized femoral tunnel to the anatomical centroids of both the AM and PL bundle origins on the lateral intercondylar wall.

A recent biomechanical study has shown that the AM and PL bundles have independent functions in providing stability to the knee.<sup>11</sup> The in situ force in the PL bundle was highest at full extension and decreased with increasing flexion in response to an anterior tibial load. The in situ force of the AM bundle was lower than that of the PL bundle in response to anterior tibial loading at full extension but increased with increased flexion. Under a combined rotatory load simulating the pivot shift, the PL bundle was shown to be a greater restraint than was the AM bundle near full extension. Yagi et al<sup>36</sup> attempted to demonstrate this concept clinically by comparing patients reconstructed with a double-bundle, AM single-bundle, or PL single-bundle technique. The authors found no difference in anterior-posterior stability but better pivot-shift control in the double-bundle reconstructions at 1-year follow-up. These studies suggest the increased importance of the PL bundle and support incorporation of the PL bundle in reconstruction techniques such as double-bundle reconstruction and single-bundle techniques with a lateralized femoral tunnel to more closely approximate normal knee kinematics. A recent report by Jordan et al<sup>24</sup> demonstrated that the AM and PL bundles may not function in the reciprocal manner as suggested in previous cadaveric studies; however, further study is needed to confirm their findings.

Scopp et al<sup>31</sup> demonstrated that rotational stability in cadaveric knees is restored to normal with oblique femoral tunnel placement. Yamamoto et al<sup>37</sup> demonstrated that lateral placement of a femoral tunnel restores rotatory and anterior translation knee stability in extension but does not compare as favorably as an anatomical double-bundle ACL reconstruction at high flexion angles. Musahl et al<sup>28</sup> used a surgical robot system to position tunnels in 2 locations on the femoral notch, either inside the anatomical footprint of the ACL or at a position chosen for the best graft isometry. They found that neither position completely restored the normal kinematic properties of an intact knee

but that the femoral tunnel position inside the anatomical footprint more closely approximated normal knee kinematics than did a femoral tunnel chosen for graft isometry. Feller et al<sup>8</sup> developed a radiographic model to evaluate the effect of tibial and femoral tunnel placement on simulated graft isometry. They found the lowest simulated changes in attachment point distance with a more proximal tibial starting point and a femoral tunnel position within the anatomical footprint of the ACL.

Loh et al<sup>25</sup> compared anterior tibial translation between cadaveric knees in which the ACL was reconstructed with either a 10-o'clock or an 11-o'clock femoral position. The authors found no differences in anterior tibial translation with a straight anterior force, but they demonstrated smaller amounts of anterior tibial translation with a combined rotatory load. They concluded that ACL reconstruction using a lateralized femoral tunnel position more effectively resisted rotational forces.

Two recent studies<sup>29,34</sup> elegantly demonstrated the anatomical origins of the AM and PL bundles of the ACL and highlighted the variability among techniques used by previous investigators<sup>13,40</sup> to determine the insertion size, shape, and position. To minimize the effects of subjective and specimen variability in determining the precise location of the AM and PL bundle origins with respect to their broad attachments, we attempted to focus on depicting the mechanical centroids of these bundles. By using the calculated centroids of the AM and PL bundles and femoral tunnel, we were able to depict each as a single point of reference on the lateral intercondylar wall, thus minimizing the inconsistencies noted in the literature.

The work by Howell et al<sup>18</sup> emphasized the importance of the orientation of the tibial tunnel clinically and was confirmed *in vitro* by Simmons et al.<sup>32</sup> Clinically, this is achieved by orienting the tibial tunnel so that the femoral offset aimer can be placed at an orientation of approximately 60° from the proximal tibia joint surface in the coronal plane to achieve the desired resultant femoral tunnel position. Ideal placement of the tibial tunnel can be achieved by observing 3 references for intra-articular position of the tibial guide pin. The pin should exit intra-articularly at the posterior aspect of the tibial ACL footprint, approximately 5 mm lateral to the medial tibial spine and 7 mm anterior to the PCL. Another general reference point for the position of the pin is 3 to 4 mm posterior to the posterior edge of the anterior horn of the lateral meniscus. By adhering to the above reference points and orienting the tunnel approximately 60° to the proximal tibia joint surface, a consistently lateralized femoral tunnel is possible using a transtibial drilled technique.

Clinically, the problem of inadvertent vertical femoral tunnel creation can occur using a transtibial approach when the tibial aimer is placed through a standard inferomedial arthroscopic portal. Soft tissue and the medial edge of the patellar tendon can affect the ability of the surgeon to rotate the tibial aiming device. To achieve a lateralized, transtibial drilled femoral tunnel along the intercondylar wall, creation of an accessory transpatellar tendon portal may improve the ability to rotate the tibial aimer, thus allowing oblique orientation of the tibial tunnel and a lateralized orientation of

the femoral tunnel encompassing portions of both the AM and PL bundles.

There are 2 primary limitations to this study. First, our use of a replica tibia model may not perfectly represent an intact knee. By using a size-appropriate, side-matched, standardized tibial tunnel, and positioning the tibial model anatomically with respect to the femur at a standardized flexion angle, we attempted to minimize the interspecimen tibial tunnel variability. The mean femoral tunnel angles from vertical for our right and left femurs were not significantly different (right, 49°; left, 47°;  $P = .23$ ), confirming the reproducibility of our experimental model. In addition, Rue et al (J Knee Surg, in press **PLEASE PROVIDE A COMPLETE REFERENCE**) recorded the angle from the apex of the intercondylar notch to the center of the femoral tunnel for the postoperative radiographs from 50 consecutive primary single-bundle ACL reconstructions using a transtibial drilled, lateralized femoral tunnel. They reported a mean absolute femoral tunnel angle of 49° from the vertical 12-o'clock position, corresponding to approximately a 10:30 clock face position for a right knee. Our mean femoral tunnel angle from vertical was nearly identical to their results, suggesting that the methods used in this study are a true representation of what is achieved clinically and validating our model.

Second, the technique used to preserve and digitally measure the femoral origins of the AM and PL bundles during the reaming process was technically challenging. The cadaveric bone quality was poor and allowed for reaming with a push-reaming type of technique, preferentially reaming the soft bone without destroying the soft tissue attachments of the AM and PL bundles. Although the process did result in preservation of the majority of the soft tissue attachments, there were portions of the bundles that were destroyed during the reaming process. If a sufficient amount of the bundles overlapping the femoral tunnel was preserved to allow for a best-fit curve depiction of the intact bundles, the digitization measurements were performed following this curve. If, however, insufficient soft tissue remained to accurately depict the intact bundle overlapping the femoral tunnel, the specimen was not included in the analysis. Using this technique, 10 of the 14 specimens provided adequate soft tissue preservation for digitization measurements to be performed.

These results show that a lateralized femoral tunnel, such as that used by the senior author, places the graft in a location to effectively replace approximately half of the PL bundle footprint and half of the AM bundle footprint. Although the methods used in this study focus on the overlap of a 10-mm femoral tunnel such as that used for a bone-patellar tendon-bone graft, it is possible to extrapolate that the actual location of a graft within that tunnel could potentially result in an increase in the composition from each of the respective bundles. For example, for a standard 10 × 25-mm femoral bone block placed in the 10-mm femoral tunnel so that the soft tissue attachment of the graft is rotated posteriorly and laterally, it is possible that the calculated centroid of the graft would be weighted more toward the PL bundle centroid. Similarly, for an autogenous hamstring tendon ACL graft of smaller size (7 or 8

mm), the composition percentage and weighted proximity values of the centroids may be slightly different as well. Further study in this area may be warranted to evaluate the effects of different-sized femoral tunnels and graft types in relation to the AM and PL bundle origins.

## CONCLUSION

This study confirms other anatomical studies<sup>29,34,38</sup> and demonstrates that a 10:30 (1:30 for left knees) femoral tunnel can be achieved using a laterally oriented transtibial femoral offset guide and that this technique reconstructs portions of both the AM and PL bundles.

This study gives surgeons a better understanding of the location of the AM and PL bundle origins of the ACL relative to a lateralized, 10-mm femoral tunnel and should encourage surgeons to critically review where their femoral tunnel location falls with respect to the anatomical femoral footprint of the ACL.

## ACKNOWLEDGMENT

The authors thank Anish Ghodadra for his contribution of data analysis and Elizabeth Shewman, MS, for her expert assistance in performing the digitizer measurements.

## REFERENCES

- Adachi N, Ochi M, Uchio Y, Iwasa J, Kuriwaka M, Ito Y. Reconstruction of the anterior cruciate ligament: single-versus double-bundle multistranded hamstring tendons. *J Bone Joint Surg Br*. 2004;86(4):515-520.
- Arnold MP, Verdonschot N, Van Kampen A. ACL graft can replicate the normal ligament's tension curve. *Knee Surg Sports Traumatol Arthrosc*. 2005;13:625-631.
- Asagumo H, Kimura M, Kobayashi Y, Taki M, Takagishi K. Anatomic reconstruction of the anterior cruciate ligament using double-bundle hamstring tendons: surgical techniques, clinical outcomes, and complications. *Arthroscopy*. 2007;23(6):602-609.
- Bach B, Levy M, Bojchuk J, Tradonsky S, Bush-Joseph C, Khan N. Single-incision endoscopic anterior cruciate ligament reconstruction using patellar tendon autograft: minimum two-year follow-up evaluation. *Am J Sports Med*. 1998;26(1):30-40.
- Bach BRJ, Aadalén KJ, Dennis MG. Primary anterior cruciate ligament reconstruction using fresh-frozen, nonirradiated patellar tendon allograft: minimum 2-year follow-up. *Am J Sports Med*. 2005;33:284-292.
- Buonocristiani AM, Tjoumakaris FP, Starman JS, Ferretti F, Fu FH. Anatomic double-bundle anterior cruciate ligament reconstruction. *Arthroscopy*. 2006;22(9):1000-1006.
- Caborn DN, Chang HC. Single femoral socket double-bundle anterior cruciate ligament reconstruction using tibialis anterior tendon: description of a new technique. *Arthroscopy*. 2005;21(10):1273.e1-1273.e8.
- Feller JA, Glisson RR, Seaber AV, Feagin JA, Garrett WE Jr. Graft isometricity in unitunnel anterior cruciate ligament reconstruction: analysis of influential factors using a radiographic model. *Knee Surg Sports Traumatol Arthrosc*. 1993;1(3-4):136-142.
- Fu FH, Bennett CH, Lattermann C, Ma CB. Current trends in anterior cruciate ligament reconstruction, part I: biology and biomechanics of reconstruction. *Am J Sports Med*. 1999;27(6):821-830.
- Fu FH, Bennett CH, Ma CB, Menetrey J, Lattermann C. Current trends in anterior cruciate ligament reconstruction, part II: operative procedures and clinical correlations. *Am J Sports Med*. 2000;28(1):124-130.
- Gabriel MT, Wong EK, Woo SL, Debski RE. Distribution of in-situ forces in the anterior cruciate ligament in response to rotatory loads. *J Orthop Res*. 2004;22:85-89.
- George MS, Dunn WR, Spindler KP. Current concepts review: revision anterior cruciate ligament reconstruction. *Am J Sports Med*. 2006;34(12):2026-2037.
- Girgis FG, Marshall JL, Monajem A. The cruciate ligaments of the knee joint: anatomical, functional and experimental analysis. *Clin Orthop Relat Res*. 1975;106:216-231.
- Giron F, Cuomo P, Edwards A, Bull A, Amis A, Aglietti P. Double-bundle "anatomic" anterior cruciate ligament reconstruction: a cadaveric study of tunnel positioning with a transtibial technique. *Arthroscopy*. 2007;23(1):7-13.
- Hamada M, Shino K, Horibe S, et al. Single- versus bi-socket anterior cruciate ligament reconstruction using autogenous multiple-stranded hamstring tendons with EndoButton femoral fixation: a prospective study. *Arthroscopy*. 2001;17(8):801-807.
- Hardin GT, Bach BRJ, Bush-Joseph CA, Farr J. Endoscopic single-incision anterior cruciate ligament reconstruction using patellar tendon autograft: surgical technique. *J Knee Surg*. 2003;16(3):135-144.
- Harner CD, Griffin JR, Duntzman RC, Annunziata CC, Friedman MJ. Evaluation and treatment of recurrent instability after anterior cruciate ligament reconstruction. *Instr Course Lect*. 2001;50:463-474.
- Howell SM, Gittins ME, Gottlieb JE, Traina SM, Zoellner TM. The relationship between the angle of the tibial tunnel in the coronal plane and loss of flexion and anterior laxity after anterior cruciate ligament reconstruction. *Am J Sports Med*. 2001;29(5):567-574.
- Jarvela T. Double-bundle versus single-bundle anterior cruciate ligament reconstruction: a prospective, randomized clinical study. *Knee Surg Sports Traumatol Arthrosc*. 2007;15(5):500-507.
- Jarvela T, Paakkala T, Kannus P, Jarvinen M. The incidence of patellofemoral osteoarthritis and associated findings seven years after anterior cruciate ligament reconstruction with a bone-patellar tendon-bone autograft. *Am J Sports Med*. 2001;29:18-24.
- Jaureguito JW, Paulos LE. Why grafts fail. *Clin Orthop Relat Res*. 1996;325:25-41.
- Johnson DL, Fu FH. Anterior cruciate ligament reconstruction: why do failures occur? *Instr Course Lect*. 1995;44:391-406.
- Jomha NM, Borton DC, Clingeleffer AJ, Pinczewski LA. Long term osteoarthritic changes in anterior cruciate ligament reconstructed knees. *Clin Orthop Relat Res*. 1999;358:188-193.
- Jordan SS, DeFrate LE, Nha KW, Papannagari R, Gill TJ, Li G. The in vivo kinematics of the anteromedial and posterolateral bundles of the anterior cruciate ligament during weightbearing knee flexion. *Am J Sports Med*. 2007;35(4):547-554.
- Loh JC, Fukuda Y, Tsuda E, Steadman RJ, Fu FH, Woo SLY. Knee stability and graft function following anterior cruciate ligament reconstruction: comparison between 11 o'clock and 10 o'clock femoral tunnel placement. *Arthroscopy*. 2003;19(3):297-304.
- Mochizuki T, Muneta T, Nagase T, Shirasawa S, Akita K, Sekiya I. Cadaveric knee observation study for describing anatomic femoral tunnel placement for two-bundle anterior cruciate ligament reconstruction. *Arthroscopy*. 2006;22(4):356-361.
- Mott H. Semitendinosus anatomic reconstruction for cruciate ligament insufficiency. *Clin Orthop Relat Res*. 1983;172:90-92.
- Musahl V, Plakseychuk A, VanScyoc A, et al. Varying femoral tunnels between the anatomical footprint and isometric positions: effect on kinematics of the anterior cruciate ligament-reconstructed knee. *Am J Sports Med*. 2005;33(5):712-718.
- Petersen W, Zantop T. Anatomy of the anterior cruciate ligament with regard to its two bundles. *Clin Orthop Relat Res*. 2007;454:35-47.
- Ristanis S, Stergiou N, Patras K, Vasiliadis H, Giakis G, Georgoulis A. Excessive tibial rotation during high-demand activities is not restored by anterior cruciate ligament reconstruction. *Arthroscopy*. 2005;21:1323-1329.
- Scopp JM, Jasper LE, Belkoff SM, Moorman CT. The effect of oblique femoral tunnel placement on rotational constraint of the knee reconstructed using patellar tendon autografts. *Arthroscopy*. 2004;20(3):294-299.

32. Simmons R, Howell SM, Hull ML. Effect of the angle of the femoral and tibial tunnels in the coronal plane and incremental excision of the posterior cruciate ligament on tension of an anterior cruciate ligament graft: an in vitro study. *J Bone Joint Surg Am.* 2003;85(6):1018-1029.
33. Sommer C, Friederich N, Muller W. Improperly placed anterior cruciate ligament grafts: correlation between radiologic parameters and clinical results. *Knee Surg Sports Traumatol Arthrosc.* 2000;8:207-213.
34. Takahashi M, Doi M, Abe M, Suzuki D, Nagano A. Anatomical study of the femoral and tibial insertions of the anteromedial and posterolateral bundles of human anterior cruciate ligament. *Am J Sports Med.* 2006;34(5):787-792.
35. Tashman S, Collon D, Anderson K, Kolowich P, Anderst W. Abnormal rotational knee motion during running after anterior cruciate ligament reconstruction. *Am J Sports Med.* 2004;32:975-983.
36. Yagi M, Kuroda R, Nagamune K, Yoshiya S, Kurosaka M. Double-bundle ACL reconstruction can improve rotational stability. *Clin Orthop Relat Res.* 2007;454:100-107.
37. Yamamoto Y, Hsu W-H, Woo SLY, Van Scyoc AH, Takakura Y, Debski RE. Knee stability and graft function after anterior cruciate ligament reconstruction: a comparison of a lateral and an anatomical femoral tunnel placement. *Am J Sports Med.* 2004;32(8):1825-1832.
38. Yasuda K, Kondo E, Ichihama H, et al. Anatomic reconstruction of the anteromedial and posterolateral bundles of the anterior cruciate ligament using hamstring tendon grafts. *Arthroscopy.* 2004;20(10):1015-1025.
39. Yasuda K, Kondo E, Ichihama H, Tanabe Y, Tohyama H. Clinical evaluation of anatomic double-bundle anterior cruciate ligament reconstruction procedure using hamstring tendon grafts: comparisons among 3 different procedures. *Arthroscopy.* 2006;22(3):240-251.
40. Zantop T, Peterson W, Fu F. Anatomy of the anterior cruciate ligament. *Oper Tech Orthop.* 2005;15:20-28.