

Multi-Suture Technique for Open Rotator Cuff Reconstruction

BERNARD R. BACH, JR., M.D.

Sports Medicine Section

Department of Orthopedic Surgery

Rush Medical College

Rush-Presbyterian-St. Luke's Medical Center

Chicago, Illinois, U.S.A.

Summary: Rotator cuff reconstruction associated with inferior acromioplasty is an effective treatment for the patient with a full-thickness rotator cuff tear. This article describes the author's technique of using multiple sutures to reconstruct the torn rotator cuff tendon. Intuitively, it is felt that this multi-suture technique will distribute forces across the tendon better than will fewer, larger sutures. The author has published a comprehensive review of 72 patients treated with this technique and evaluated at a minimum follow-up of 2 years (range, 24–102 months). The mean age was 58 years (range, 24–87 years). At follow-up 82% of the patients rated their pain as <2 on a 0–10 visual analog scale, with "0" representing no pain. Ninety-six percent of the patients had no pain or slight pain without restriction of their activities of daily living. Ninety-four percent of the patients were subjectively satisfied with their surgical result. The mean UCLA scoring scale was 32 (range, 7–35). The mean Hospital for Special Surgery Scale was 94 and the mean raw Constant–Murley Score was 78 points (range, 12–95). This modification of the "classic" rotator cuff reconstruction yields predictable results and can be adapted to mini-open rotator cuff reconstruction. Although marked technologic changes have enhanced our ability to address rotator cuff disease arthroscopically, open rotator cuff reconstruction should remain a choice of the shoulder surgeon.

■ HISTORICAL PERSPECTIVE

E. A. Codman is credited with the initial reports of successful rotator cuff reconstruction in 1908 and 1910 (1). Codman expanded our knowledge of tears of the rotator cuff tendons and their repair in his classic treatise *The Shoulder*, published in 1934 (2). Marked advances in our understanding of disorders of the shoulder have occurred

in the past 50 years and particularly within the past 15 years, as magnetic resonance imaging (MRI) and arthroscopy have further enhanced our understanding of shoulder conditions. Neer (3) is credited with popularizing the concept of impingement syndrome and its classification of three phases: (a) acute, (b) chronic, and (c) chronic with associated rotator cuff tear. Morrison and Bigliani (4) popularized the concept of acromion profiles and their potential contribution to rotator cuff tears. Classic rotator cuff repair principles include inferior acromioplasty, coracoacromial ligament release, bursal debridement, identification and mobilization of the rotator cuff tendon, and secure fixation of the rotator cuff tendon edges into a bone trough. Advances including arthroscopic subacromial decompression and "mini-open" rotator cuff repairs, which obviate detachment of the anterior deltoid from the acromion, evolved during the 1990s. Improved fluid pressure delivery systems and refined electrocautery devices have facilitated this evolution. Technologic advances with arthroscopic suture anchor devices and arthroscopy knot-tying techniques have resulted in transitions by some surgeons to an "all arthroscopic" rotator cuff reconstruction. The purpose of this manuscript is to describe the author's multi-suture technique used for open rotator cuff reconstruction. This technique has been used predominantly with deltoid detachment but can be utilized with a mini-open technique. The author has used this technique since 1986 and clinical results have been published documenting the efficacy of this modified open technique (5). Open rotator cuff repair remains the practice standard to which those less invasive emerging technologies should be compared.

■ INDICATIONS AND CONTRAINDICATIONS

Most patients presenting to our office for elective rotator cuff repair have significant sleep disturbances secondary to shoulder pain. This is the major reason why most patients elect to have rotator cuff reconstructive surgery. The patient with a small or medium tear generally may

Address correspondence and reprint requests to Dr. Bernard R. Bach, Jr., 1725 W. Harrison Street, Suite 1063, Chicago, IL 60612, USA.
E-mail: brbachmd@ix.netcom.com

have normal or near-normal active motion with minimal scapular substitution. As the tear enlarges, scapular substitution is appreciated and “hiking” of the shoulder may be noted. Weakness to external rotation at the side is generally an indicator of a large to massive tear. Proximal biceps tendon ruptures associated with rotator cuff tears generally indicate a large tear and the results in our series indicated that patients with an associated biceps tendon rupture had poorer outcomes than did patients without ruptures (5). An abnormal “lift-off” sign is indicative of an associated subscapularis tear, which may necessitate a modified surgical exposure (6). The acromioclavicular joint should be critically assessed. Acromioclavicular joint arthrosis is common in patients older than 40 years of age. Most patients are, however, asymptomatic. Our decision to perform an associated distal clavicle resection is made based on localized acromioclavicular joint tenderness, superior oriented pain, positive adduction crossover test referred to the acromioclavicular joint region, or pain referred to the acromioclavicular joint region with internal rotation along the spine. Concomitant distal clavicle resection is performed in approximately 15% of our patients (5).

Generally the younger the patient’s age, the more aggressively we recommend rotator cuff surgery. Rotator cuff reconstruction is recommended in patients in their 40s and 50s. The average age of patients in our recently published clinical series was 58 years old (5). It is important to stress this to patients, because many patients have the misconception that rotator cuff tears are a “disease” of athletes in their 20s and early 30s. As patients enter their 60s, our recommendations are individualized based on the magnitude of pain, functional deficits, the size of the tear, patients’ associated comorbidities, and the quality of the muscle on MRI imaging. We are increasingly conservative as patients enter their 70s. It is extremely unusual to recommend rotator cuff surgery in individuals in their 80s. In older patients, osteopenia of the proximal humerus can be a major factor in the inability to obtain secure fixation of the rotator cuff tendon. In patients who have a concurrent adhesive capsulitis, we prefer to rehabilitate the shoulder initially and then, once most passive motion is regained, proceed with rotator cuff reconstruction. In patients older than 40 years of age who sustain a traumatic shoulder dislocation, associated rotator cuff tear is suspected in individuals with persistent pain, weakness, or loss of active motion. If patients have significant glenohumeral arthritis, attention is directed toward shoulder arthroplasty with rotator cuff repair.

■ PREOPERATIVE IMAGING

Radiographs are obtained in all patients during the work-up of the painful shoulder. These radiographs include a

true anteroposterior view of the glenohumeral joint, a “Y” lateral view, and an axillary view. The true anteroposterior view and axillary view provide important information regarding any coexisting glenohumeral arthritis. The Y lateral view provides critical information regarding the acromion profile, which is helpful in preoperative planning with regard to the extent of subacromial decompression. Although historically a double contrast arthrogram was used for imaging of rotator cuff tears, MRI is our current choice for rotator cuff imaging. The quality of scanning and the experience of interpreters (both radiologists and orthopedists) have improved, making MRI the preferred imaging technique. MRI provides the advantages of being able to ascertain the relative size and location of the tear and the quality of the muscle, and to exclude spinoglenoid notch cysts that may

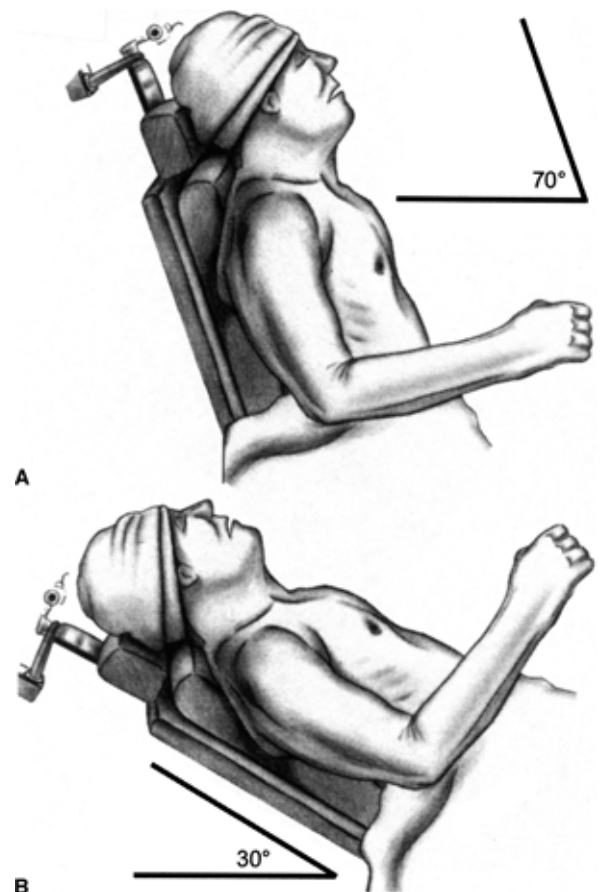


FIG. 1. **A.** Patients are positioned in the beach chair position. The waist and foot of the table are flexed. The torso is brought to the edge of the operating table. An arthroscopic lateral post is used to stabilize the thorax. The back is elevated to 70° to 80° if arthroscopy is planned, and dropped to 30° during the open approach (**B**). The head is supported on a foam “donut” and stabilized with a towel and tape. The torso may be “airplaned” or rotated slightly to the contralateral direction.

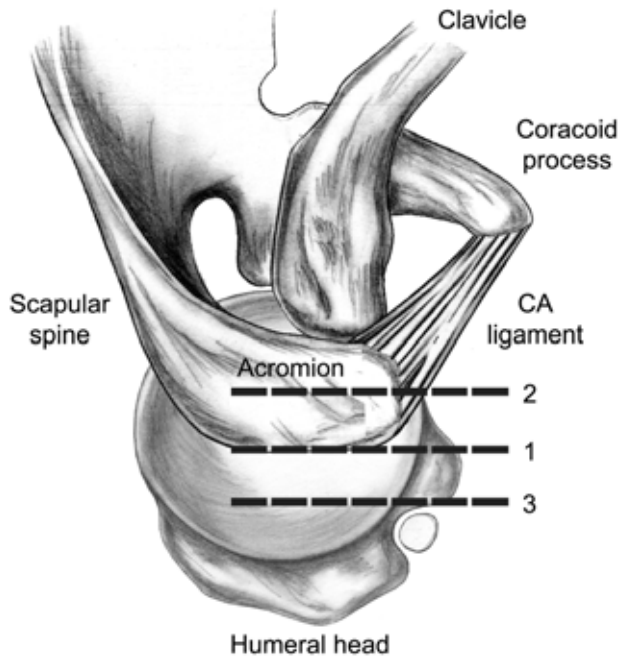


FIG. 2. The surgical incisions used for standard rotator cuff reconstruction are depicted. 1 = Standard open rotator cuff approach using the lateral border of the acromion. 2 = Slightly medialized incision when open distal clavicle resection is incorporated into the rotator cuff tear reconstruction technique. 3 = Slightly lateralized incision when a mini-open technique is employed.

compress the suprascapular nerve, resulting in rotator cuff weakness.

■ TECHNIQUE

Patient Positioning

Rotator cuff surgery is performed with the patient under general endotracheal anesthesia or scalene block with or without supplemental general anesthesia. If a scalene block is used along with a general anesthetic, it should be administered before the anesthetic to reduce potential complications associated with interscalene blocks. The patient is positioned in the beachchair position (Fig. 1A and B). This is done after the patient's shoulder has been examined under anesthesia to assess for occult shoulder instability and to document any concurrent shoulder stiffness. The patient is then moved to the edge of the operating room table. The thorax is stabilized with an adjustable arthroscopic lateral post. The waist and foot of the table are flexed. The back of the table is elevated. The amount of elevation depends on whether the procedure is an exclusively open procedure or whether it is an arthroscopy-assisted procedure. The advantage of a purely open procedure is that the patient can be maintained at a lesser degree of elevation in the beachchair position and, in this situation, the head of the table is raised approximately 35° to 40°. If arthroscopy is performed, the back needs to

be elevated to approximately 70° to 80°. In patients who have cardiovascular diseases, this may place the patient at risk for postural hypotension. When we proceed from the arthroscopic component of the procedure to the open portion, the back of the table is reduced to 35° to 40°. The patient's head is stabilized on a foam "donut" and the forehead is stabilized with a towel and tape.

Surgical Approach

Preoperative prophylactic antibiotics are used. One gram of a first-generation cephalosporin is administered before surgery. Transverse incisions are not recommended because they are cosmetically unacceptable. A 2- to 2.5-inch incision is made using the lateral border of the acromion as a reference point. The posterior edge of the incision effectively starts at the middle of the lateral edge of the acromion and extends anterior toward the coracoid process (Fig. 2). The length of this incision can be altered depending on the size of the tear and the amount of subcutaneous tissue. In most patients, a large to massive tear can be repaired through this length incision. If an associated open distal clavicle resection is performed, the incision is medialized, splitting the difference between the acromioclavicular joint and the lateral border of the acromion (Fig. 2). If the procedure involves a mini-open technique, I localize the extent of the tear arthroscopic-

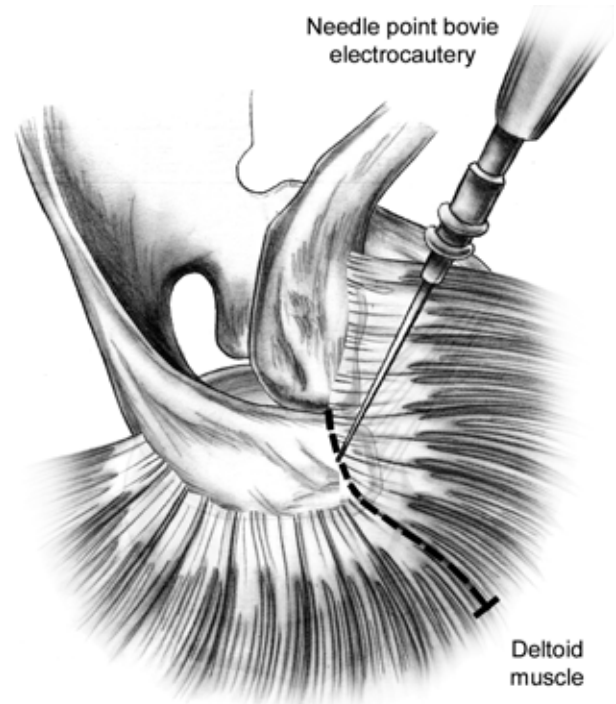


FIG. 3. Needle-point Bovie electrocautery is used to incise and release deltoid fascia. Note that this is initiated $\frac{3}{8}$ inch posterior to the anterior edge of the acromion and gently curved toward the anterolateral acromion corner. This is extended into the deltoid raphe for 2 to 4 cm.

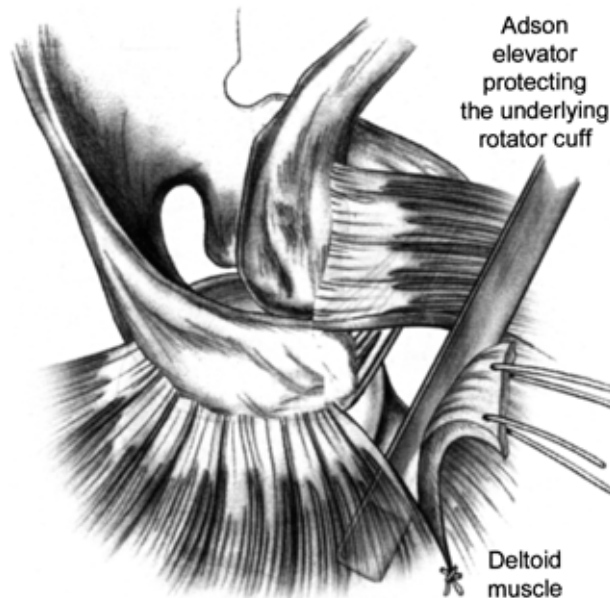


FIG. 4. An Adson elevator is placed deep to the deltoid fascia as the deltoid is split to protect the underlying rotator cuff tendon, which may be adherent to the deltoid fascia.

ally with a spinal needle and use this to orient the incision; usually the incision is similar in length but slightly lateralized off the acromion edge. In these circumstances, the incision is slightly enlarged, usually to 2.5 inches in length. This incision is a modified superior incision that has excellent cosmesis and with mobilization of subcutaneous tissues, provides excellent access to rotator cuff tears. A deltopectoral approach is recommended for subscapularis tears.

After the skin is incised, the subcutaneous tissues are mobilized. The likelihood of inadvertently violating the superficial deltoid fascia can be reduced by performing this deeper subcutaneous dissection near or over the acromion. By elevating the skin edges with small rake retractors, the interval is defined between the fascia and the deep subcutaneous tissue and is mobilized in four directions. This mobilization allows improved visibility and surgical exposure. Once the subcutaneous tissues have been mobilized, the anterior edge and anterolateral corner of the acromion are visualized and palpated. Using needle-point Bovie tip electrocautery, a periosteal incision beginning $\frac{3}{8}$ of an inch posterior to the anterior edge of the acromion is made and directed laterally toward the anterolateral corner of the acromion (Fig. 3). This is then directed 1 to 1.5 inches laterally through the anterolateral deltoid raphe. The periosteum and fascia are elevated until the anterior edge of the acromion is well defined (Fig. 3). At the anterolateral corner, an incision is made through the fascia. This will cause joint fluid to extrude from the subacromial space into the surgical

field. At this point a small Adson elevator (V. Mueller, Allegiance Healthcare, Deerfield, IL, U.S.A.) is placed deep to the deep deltoid fascia so that this can be incised without potentially violating adherent rotator cuff tissue (Fig. 4). The distal extent of the deltoid split is secured with a nonabsorbable suture to prevent inadvertent extension of the deltoid split, with the potential complication of an axillary nerve injury.

This modified technique of elevating the periosteum and fascia from the superomedial aspect of the acromion results in excellent tissue quality that can subsequently be reattached to the acromion at the conclusion of the procedure. This modified “deltoid-off” technique is preferable to directly releasing the deltoid from the anterior edge of the acromion. In some patients, there may be a large acromion spur or excrescence that, when resected, may make it more difficult to reattach the deltoid fascia if the deltoid has been directly released from the anterior acromion edge.

The next step is to proceed with coracoacromial ligament release (Fig. 5). A segment of the coracoacromial ligament is not formally resected. Instead, it is released with electrocautery under direct visualization with hemostasis being achieved concurrently. There is debate as to whether the coracoacromial ligament should be preserved, resected, or reattached. In large and massive tears, consideration is given to reattaching the coracoacromial ligament at the conclusion of the procedure. The next step involves inferior acromioplasty (Fig. 6A and B). Lateral acromionectomy is contraindicated. The goal of acromioplasty is to create a flat undersurface or

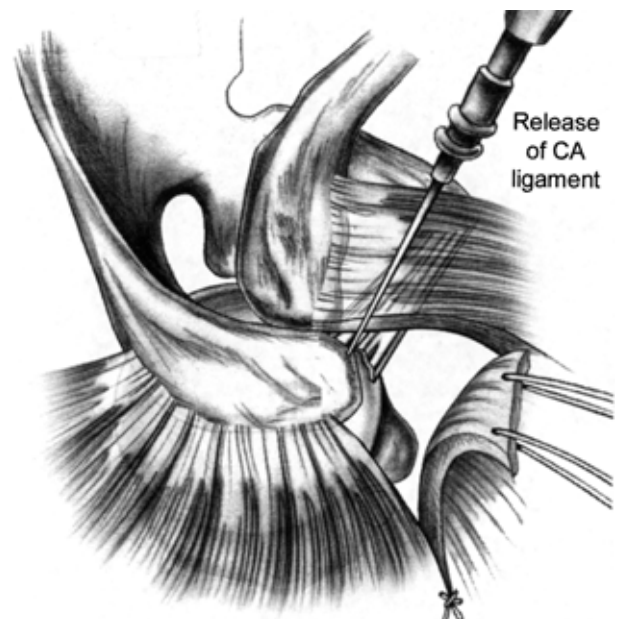


FIG. 5. During open rotator cuff reconstruction, the coracoacromial (CA) ligament is released but not formally resected.

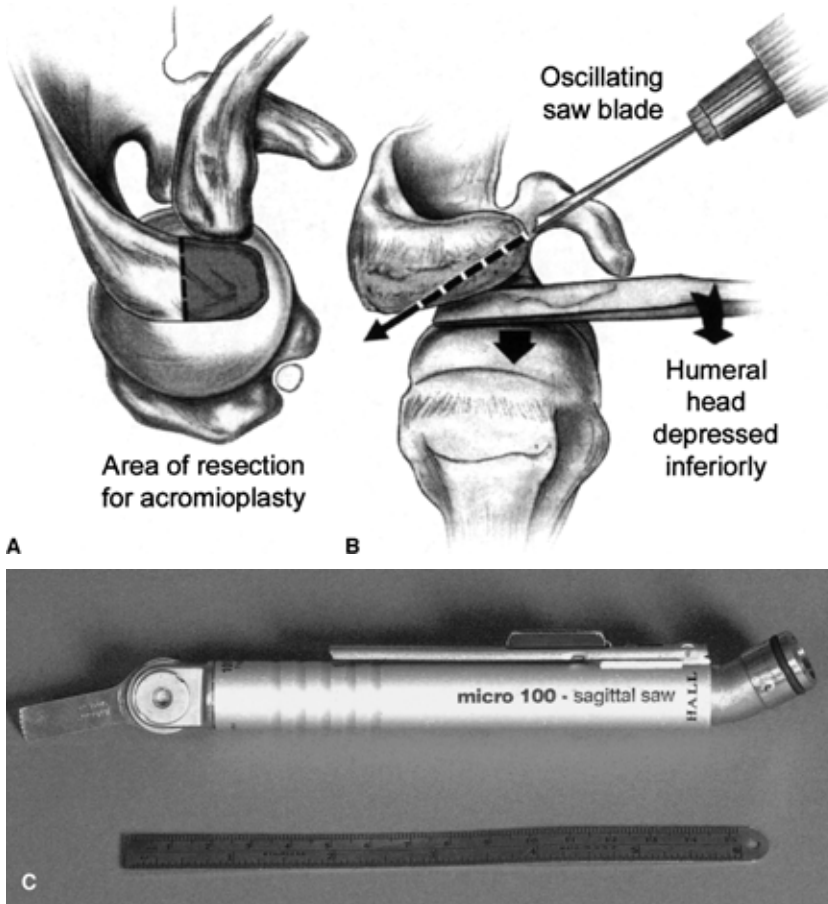


FIG. 6. A–C In large and massive tears, open acromioplasty is appropriate. **A.** A Chandler retractor is placed inferiorly to protect and retract the rotator cuff tissues and humeral head. **B.** A No. 238 oscillating saw blade (**C**) is used to perform a precise decompression with the goal of creating a type I acromion profile. Before performing the acromioplasty, palpating the undersurface of the acromion can be helpful in orienting the plane of the saw cut.

effectively create a type I acromion. Because the thickness of the acromion varies among individuals, an absolute amount of acromion resection is not advocated (Fig. 7). If there is a large anterior excrescence, a two-stage acromioplasty is performed in which the excrescence is

resected in the coronal plane; then I proceed with the inferior acromioplasty (Fig. 8). A large Chandler retractor (V. Mueller, Allegiance Healthcare) or Darrach elevator (V. Mueller, Allegiance Healthcare) is placed underneath the acromion to inferiorly retract the humeral

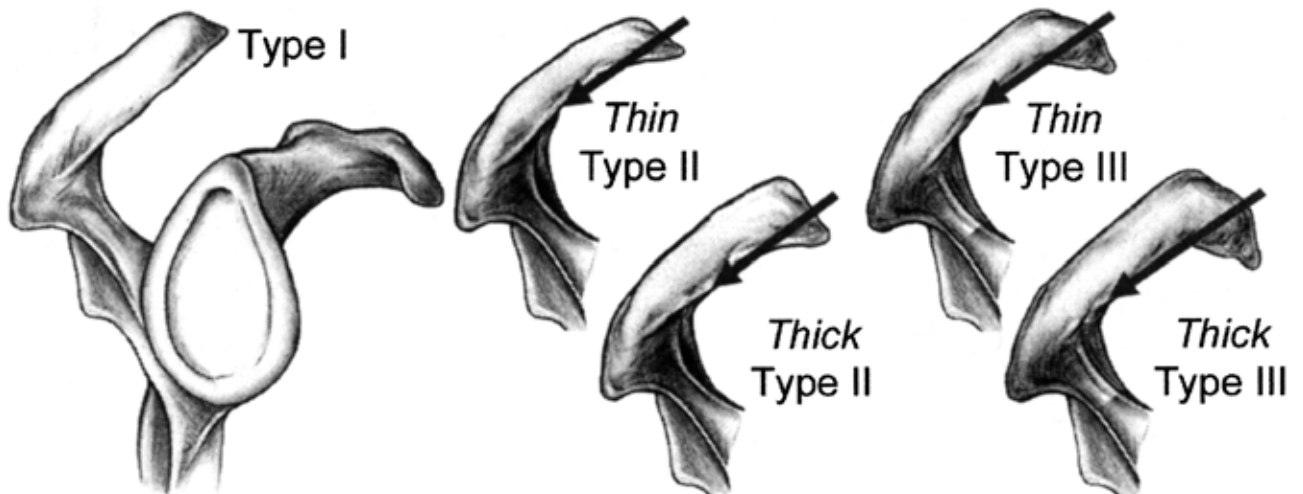


FIG. 7. The acromion profile and morphology vary, thus dictating the amount of bone resected during an acromioplasty. In a type I acromion profile, acromioplasty may not be required. Less bone is resected in a woman with a type II acromion than in a large man with a type III acromion profile.

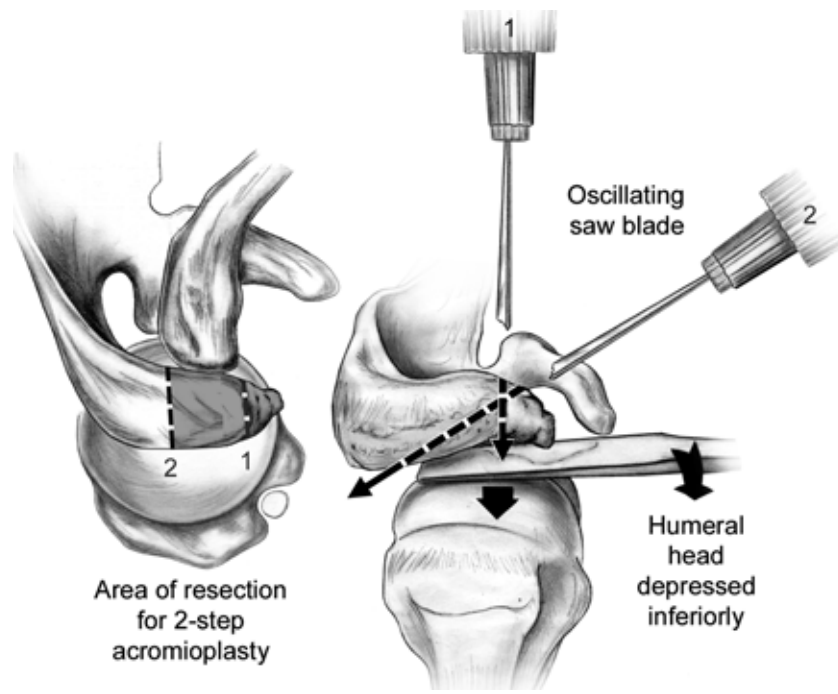


FIG. 8. One must conceptualize the acromioplasty component of the procedure in two planes including the sagittal and axial plane. From a superior or axial view, one may note anterior spikes or excrescences that extend anterior to the anterior edge of the acromioclavicular joint. One may consider a “two-step” acromioplasty whereby this spike is resected initially, followed by the sagittal plane connection.

head. A No. 238 oscillating saw blade is used to perform the acromioplasty (Fig. 6B). For open acromioplasty, an oscillating saw is preferred to a burr or osteotome. After this bone is removed, the undersurface of the acromion is visualized and directly palpated for additional spurs or roughened edges that might require smoothing with a small rasp. One must be certain not to create a transfer lesion, which is a surgically created ridge on the undersurface of the acromion related to improper caudal orientation of the saw blade (Fig. 9). Conversely, if improperly oriented in a cephalad direction, the saw blade could be directed through the dorsal surface of the acromion, effectively creating an iatrogenic acromion fracture.

After acromioplasty, the Chandler retractor is removed and Richards retractors (V. Mueller, Allegiance Healthcare) are positioned for retraction purposes. Care must be taken to protect the deltoid musculature during the retraction. The rotator cuff tear is identified and visualized. Rotation of the arm with forward flexion or extension help visualizes the extent and size of the tear. The amount of bursal thickening varies among patients. A subtotal bursectomy is performed as needed. Bursal adhesions are mobilized digitally as well as with an elevator, and are resected with Metzenbaum scissor dissection.

Once the tear is visualized and its size assessed, the multiple suture technique is initiated. In general, I prefer to proceed from one edge of the tear in a systematic fashion. Zero Polydec on a KHT-3 needle (30-inch length, Deknatel, Fall River, MA, U.S.A.) are the preferred sutures, although I have used No. 1 Ethibond (30-

inch length, Ethicon, Sommerville, NJ, U.S.A.). The KHT-3 needle is a small cardiovascular needle that enhances maneuverability in confined spaces. Sutures are placed 3 to 4 mm apart after minimal debridement is performed to the rotator cuff edges. Sutures are placed in a simple fashion rather than as a Mason–Allen or Kessler configuration.

Multiple sutures are placed 3 to 4 mm apart; the number used obviously varies, depending on the size of the tear. In a small tear, I may place 4 to 5 sutures, whereas in a large to massive tear, 20 to 25 sutures may be used (Fig. 10A and B).

One of the key principles of multi-suture technique is suture management. For this reason, after placement of every four to six sutures, this group of sutures is then clamped together. Specially ordered tri-color sutures (Ethicon) are helpful in suture management. The majority of cuff tears that I see result in a tendon-to-bone fixation. If tears have a tendon-to-tendon tear component, the sutures can be used for direct tendon-to-tendon repair. In certain circumstances, depending on the tear configuration, a “marginal convergence” approach may be used in which the most medial aspects of the tear apices are sewn together and progressed laterally in an attempt to diminish the overall tear size, which is then secured to a greater tuberosity trough. Ideal tears for the multi-suture technique are the crescentic or triangular types.

Once the sutures have been placed and grouped, a trough is created with a ¼-inch spherical burr. Although there is some controversy about whether a bone trough

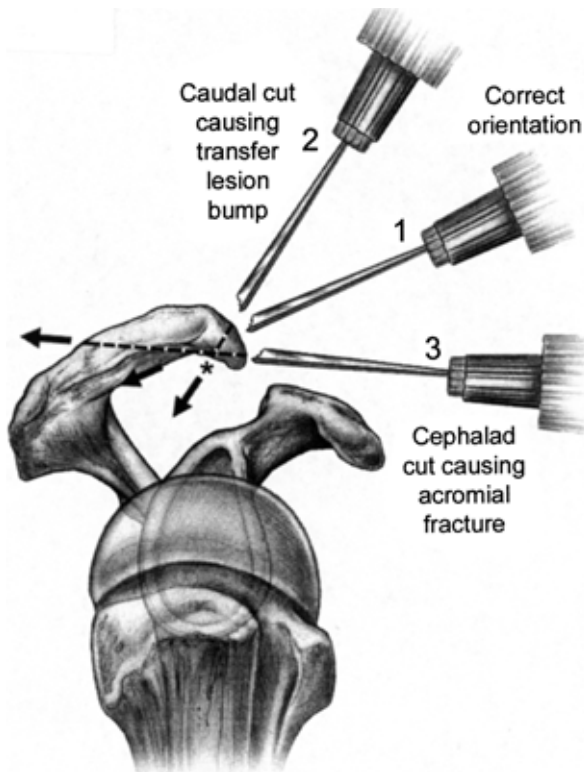


FIG. 9. If the saw blade is improperly oriented, a “transfer lesion” may be created on the undersurface of the acromion. If the saw blade is directed in a cephalad direction, the superior or dorsal surface may be violated, resulting in an acromion fracture.

should be created, I believe that bleeding bone can assist in the healing process. Additionally, transosseous tunnels are made with small towel clips; the creation of a trough allows the easy placement of the tine of the towel clip into the trough, thus reducing the likelihood of a bone bridge fracture (Fig. 11A and B). The numbers of sutures and the size of the tear dictate how many transosseous tunnels are created. In general, no more than five are created and, in most cases for large to massive tears, three to four transosseous tunnels are made. As each transosseous tunnel is created, a suture passer is passed, either from the cancellous side through the cortical edge or vice-versa. A No. 8 Mayo ½-inch tapered needle with an attached free suture is passed. It is important to follow the transosseous path created by the towel clip so that the sutures can easily be passed.

Once the suture is passed, a loop is created in the suture to create a suture passer (Fig. 11B). A suture is passed through each transosseous tunnel, effectively creating either three or four suture passers. As previously noted, the sutures placed in the tendon edge are placed in a simple fashion. Therefore, the inner limbs of each respective suture group are passed through the transosseous tunnel with each respective suture passer (Fig. 12).

In general, up to five to six sutures can be passed through the transosseous tunnel with the use of a suture passer. Each group of sutures is then passed.

The next step in the multi-suture technique involves suture identification (Fig. 13). Each suture is individually identified and tied. To facilitate this, the outer sutures are spread and then individually pulled to identify each suture’s corresponding limb that has passed through the transosseous tunnel. Each of these sutures is individually clamped in an orderly sequence. Once all sutures from this group have been identified, manual tension is placed on the other suture groups to reduce tension on the rotator cuff tendon and these sutures are individually tied (Fig. 14). For example, if three groups of sutures have been placed, the middle group of sutures is initially individually tied to restore tension to the middle portion of the tendon reapposition (Fig. 14). The remaining groups of sutures are then secured in a similar fashion involving suture identification and the individual tying of these sutures. The goal is to reattach the tendon with the arm at the side with minimal tension.

The rationale for this multi-suture technique is to distribute tension along the course of the rotator cuff tendon. Intuitively, it seems that if one were to use fewer sutures of a larger suture, there would be increased stress at that specific point of fixation. This technique has allowed me to confidently approach large and massive tears. Numerous patients whose prior rotator cuff surgery has been unsuccessful have come to me for a second opinion on the use of suture anchor devices. In most cases suture anchors have been used. Review of their operative reports indicated that individual anchors with single or double sutures had been used, implying that this fixation construct was being asked to “do too much work.”

Once the rotator cuff tendon is repaired, the range of motion is assessed, including internal and external rotation at the side and in the horizontal plane, as well as forward elevation. The wound is irrigated and attention is directed toward a careful deltoid reapposition. Three towel clip holes are made in the acromion. A No. 2 Ethibond suture (Ethicon) is passed from “outside-in” on the acromion and ultimately “inside-out” on the deltoid. Before these sutures are completely passed through the deltoid, sutures are placed through the deltoid split (Fig. 15). These sutures are also placed in position but not tied until the sutures have been placed through the deltoid. Care is taken to ensure that the deep deltoid fascia is incorporated into the deltoid reattachment. Once all sutures have been placed into the deltoid repair, the arm is forward elevated and the deltoid is reapproximated and secured. This results in excellent fixation of the deltoid.

In my clinical follow-up series, no deltoid detachments were observed, despite initiating early active mo-

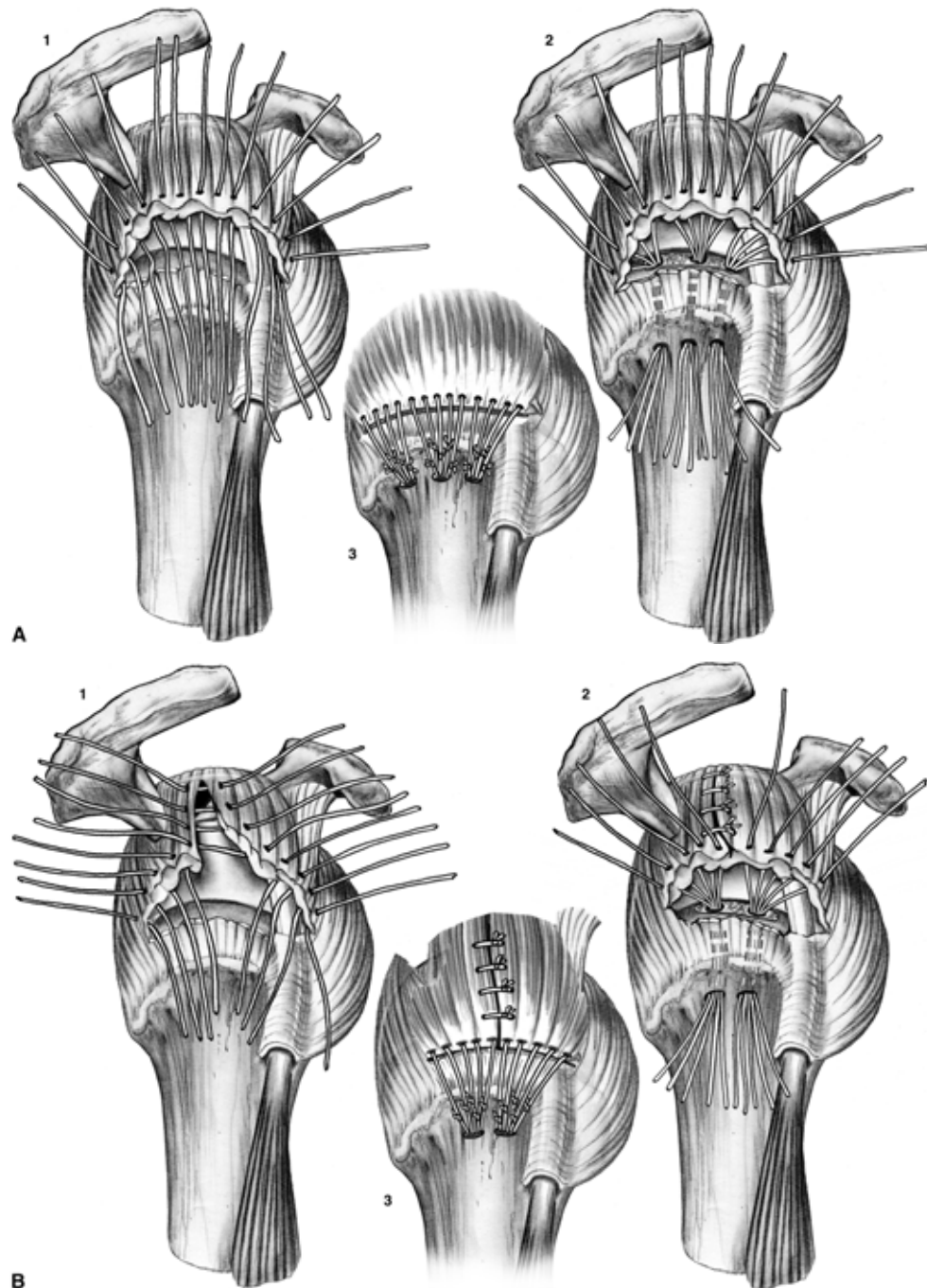


FIG. 10. **A.** 1) Two tear configurations and the concept of multi-suture repair, 2) suture grouping through a transosseous tunnel, and 3) completion of the repair for a crescentic tear. **B.** Repair of a T-shaped repair is depicted. A combination tendon-to-tendon and tendon-to-bone repair is achieved. In this example, two groups of four sutures are placed through two transosseous tunnels (2), before final repair (1). A side-to-end repair is depicted (2). Inner suture limbs are passed through the two transosseous tunnels, individually identified, and tied.

tion at 3 weeks after surgery (5). It should be noted that a permanent suture is used for both rotator cuff repair and deltoid reapposition. The subcutaneous tissue is closed with an absorbable suture. The skin is closed with a nylon suture running subcuticularly. Bupivacaine is injected into the subacromial space and into the periosteal

region. Within the past year, I have been using a post-operative analgesic pain catheter (DonJoy Pain Blaster, DonJoy, Carlsbad, CA, U.S.A.). Sterile strips are applied, followed by the application of Owen's gauze, sterile dressings, cryotherapy (DonJoy Iceman, DonJoy), and sling. The goal at the time of surgery is to mobilize

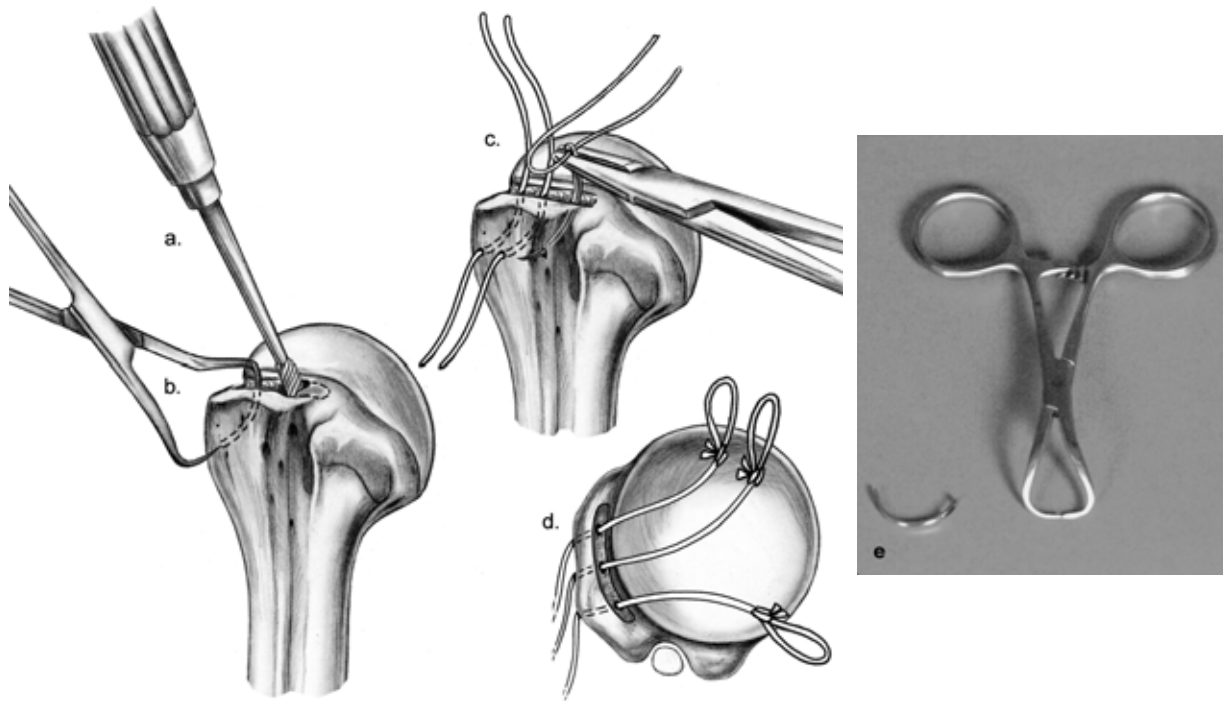


FIG. 11. A bone trough is created with a special burr to provide a bleeding bed for tendon repositioning (a). The trough should be made deep enough to encounter cancellous bone. The trough is generally made near the articular edge and medial to the greater tuberosity. The creation of the trough allows appropriate placement of the small towel clip for a transosseous tunnel (b). A free suture placed on a Mayo $\frac{1}{2}$ tapered needle is used to follow the arc created by the towel clip (c). A loop is tied on the inner limb of the sutures placed through the transosseous tunnels (d). They are used as suture passers. Note that the arc of a small towel clip is identical to the No. 8 Mayo needle (e).

tissues so that no abduction orthosis is used. I have not used an abduction orthosis in more than 5 years. A modified sling (Ultrasling, DonJoy) is used for patient comfort.

■ POSTOPERATIVE MANAGEMENT

Eighty percent of my patients' surgeries are performed on an outpatient basis. The decision to keep patients in hospital overnight is based on several factors including the distance that they are traveling to the hospital, the support system that they have at home, their ability to understand instructions, and their general medical status. If an analgesic postoperative pain catheter is used, the patient is instructed on catheter removal, which is performed on the second morning after surgery. Patients are instructed with regard to pendulums and assisted supine elevation exercises, which begin the day after surgery, and the amount of external rotation at the side and elevation is customized depending on the size of the tear and the quality of the repair. In general, 45° of external rotation is allowed at the side and up to 140° elevation in the supine position. The importance of assisted supine elevation exercises is explained to the patients, who are instructed not to perform any independent active elevation exercises for the first 3 weeks. Sutures are removed

approximately 10 to 12 days after surgery. A Y lateral postoperative radiograph is obtained to assess the postoperative acromion profile. When patients make a transition to active elevation at 3 weeks, they are instructed to begin this in a supine position and initially with the elbow flexed to reduce the "lever arm." As strength is gained, the elbow is extended. When this goal is achieved, patients progress to a seated or standing position and repeat this process. Patients are directed to supervised physical therapy 3 to 4 weeks after surgery and can anticipate supervised physical therapy for up to 4 months.

■ RESULTS

My colleagues and I have recently reported results in 72 patients who underwent rotator cuff surgery using this technique between 1986 and 1993 (5). The patients were independently evaluated at a minimum 2 years after surgery (range, 24–102 months; mean follow-up, 54 months). In this study group there were 28 women and 44 men. The mean age was 58 years (range, 24–87 years; standard deviation, 11 years). In 56 patients the right shoulder was involved and in 16 patients the left shoulder was involved. In most patients (79%) the dominant arm was affected ($n = 57$). Seven of these patients

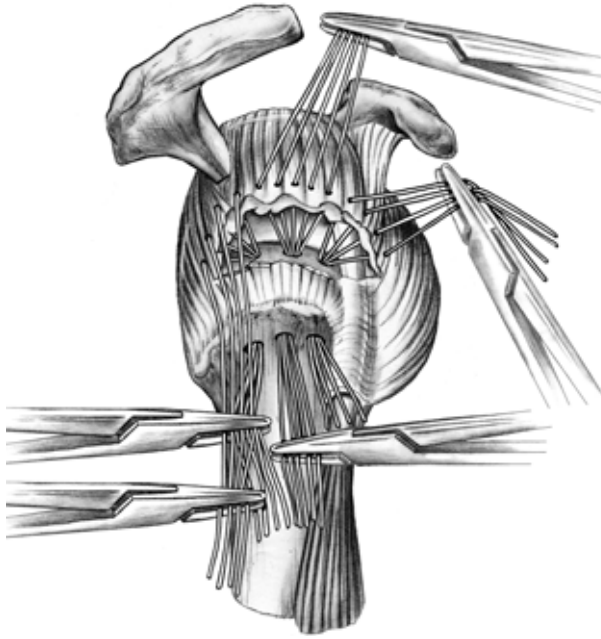


FIG. 12. Suture management is critical. Depending on the tear size, groups of four to six sutures are placed in a simple fashion. The “outer” limb is clamped. Another hemostat is used to clamp both groups of sutures (outer and inner limbs). When this hemostat is removed, one has the inner group, which may be passed through a suture passer.

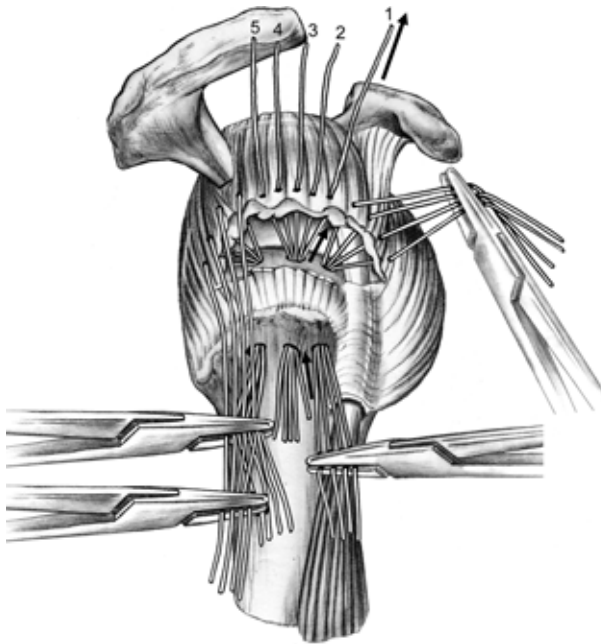


FIG. 13. After sutures are passed through the transosseous tunnel, the outer group is spread in order. Their sequence is readily visualized. Pulling on the “outer” suture limb allows for proper identification of the inner limb suture. Each suture is clamped in order until all sutures are identified for that respective group.

(10%) had worker’s compensation claims. The median interval from symptom onset to surgical intervention was 7 months (range, 1–141 months; standard deviation, 38 months). Preoperative imaging was performed on all patients and rotator cuff tear was confirmed by double contrast arthrography in 85% of patients.

The patients were evaluated using the UCLA Shoulder Scale, the Constant Murley Shoulder Scale, and the Simple Shoulder Tests (3,7–10). Additionally, the University of Connecticut Visual Analog Scale, Hospital for Special Surgery Shoulder Rating Scoring Scale, pre-1994 American Shoulder and Elbow Surgeons Shoulder Evaluation Form, Modified Rating Scale of the American Shoulder, and Elbow Surgeons Shoulder Evaluation Form by Gartsman, Neer Rating Scale, Hawkins Rating Scale, and the Rowe Shoulder Evaluation Scale were used (11–16). An extensive questionnaire was developed to incorporate these multiple surveys. Statistical analysis was employed and $p < 0.05$ was considered significant for all statistical tests employed (5).

Using this technique, shoulder pain was predictably significantly reduced. At follow-up, using a visual analog scale, 82% ($n = 59$) of the patients rated their pain at 2 or less on a scale of 10 (0 = no pain; 10 = severe pain). When pain was stratified into categories including complete resolution, slight pain without restriction of activities, and moderate pain with activity compromised, 54 (74%) of the patients had no pain, 16 patients (22%)

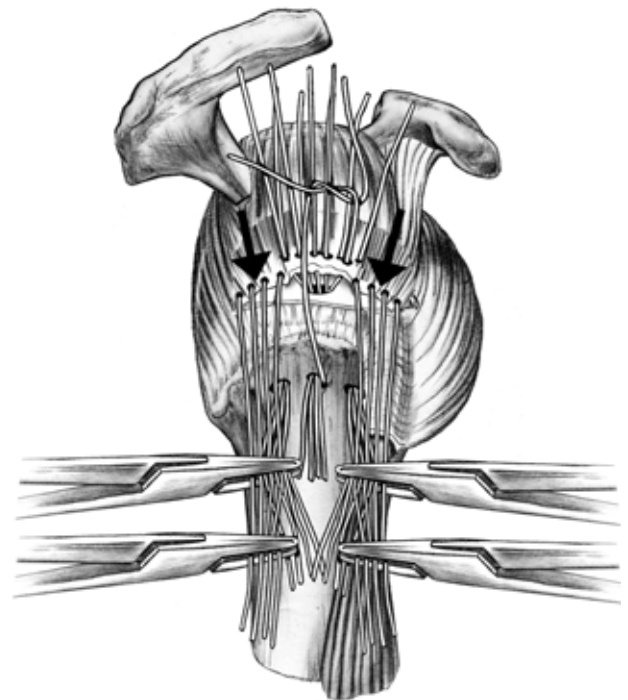


FIG. 14. Sequence of individually tying the middle group of sutures while tension is placed on the anterior and posterior groups of sutures.

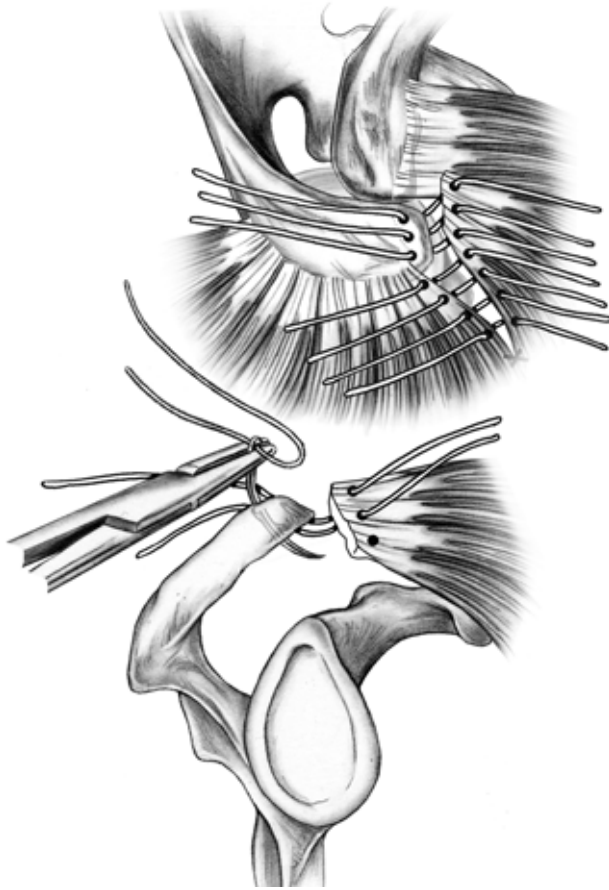


FIG. 15. Deltoid repair is critical. Three towel clips or drill holes are placed through the acromion. No. 2 Ethibond suture is placed from “outside-in” on the acromion, and subsequently “inside-out” on the deltoid to assure that the deep deltoid fascia is incorporated into the repair. Sutures are also placed into the deltoid split. Once all sutures are placed, the arm is forward and elevated and the sutures are secured. Visualization is enhanced using this approach. If the deltoid is reattached before deltoid split closure or vice versa, exposure is poorer and it may not be possible to confirm that the deep deltoid fascia has been included in the repair.

had slight pain, and 3 patients (4%) had moderate pain with activity compromise. The Simple Shoulder Test developed at the University of Washington revealed that 97% of the patients responded that their shoulder was comfortable with their arm at their side and 88% of the patients at follow-up sleep comfortably on their shoulder (5). Using the University of Washington Simple Shoulder Test, 99% of the patients indicated that they were able to wash the back of their opposite shoulder with the effected extremity. Ninety-three percent of the patients indicated that they could reach the small of their back to tuck their shirt in, and 90% of the patients indicated that they could place their hand behind their head with their elbows straight out to the side. We observed that motion

was predictably good after rotator cuff surgery. On average, forward flexion was 165°. Nearly 90% of the patients could actively elevate their arm greater than 160°. The average active external rotation was 63° at the patient’s side. The average active internal rotation was to the T12 vertebra.

With regard to strength recovery using a modification of the Constant Murley technique, on average the abduction strength ratio for the affected shoulder approached 88% of the contralateral shoulder. Using specific questions from the Simple Shoulder Test, 85% of the patients indicated that they could carry 20 pounds at their side with the affected extremity, but only 68% of the patients felt that they could lift 8 pounds to the level of their shoulders without bending at their elbow. Of note was that women who had an associated biceps tendon rupture had a lower abduction ratio than women without an associated biceps tendon rupture ($p < 0.029$). Furthermore, patients who had massive rotator cuff tears (greater than 5 cm²) had lower abduction ratios ($p < 0.0028$) than those with smaller tears. Using the multiple scoring scales that were employed in this analysis, our patient population had an average score of 32 points on the UCLA Scoring Scale (range, 7–35). The mean score on the Hospital for Special Surgery Scale and the Rowe Scoring Scale was 94 points (maximum, 100 points). The mean raw Constant-Murley Score was 78 points (range, 12–95).

In this study there was no difference in results between dominant versus nondominant side involvement. There was no difference in patients who had concomitant distal clavicle resection. Surprisingly, there was no difference in the small subgroup of patients who had worker’s compensation claims, although the small number ($n = 7$) of these claims may have impacted this observation.

Using the modified Neer Satisfaction Rating, we calculated that 76% of the patients had satisfactory results with nearly identical results to those reported by Neer (5). Using a different satisfaction rating scaled employed through UCLA, we determined that 94% of our patients indicated that they were satisfied with their results (5). In this study population, six patients had complications (8%). There were four retears. One rotator cuff re-tear occurred after a fall at postoperative 6 weeks and was re-repaired successfully. The other three patients deferred additional surgery. One patient required removal of the nonabsorbable sutures used for the deltoid reposition because of local subcutaneous tenderness. One patient had an immediate postoperative ulnar neuropathy that resolved spontaneously. In this study, there was no evidence of infection, deltoid detachment, or cardiopulmonary complications (13–19).

■ CONCLUSION

Various techniques have been popularized for repair of rotator cuff tears. The multi-suture technique is effectively a modification of the classic open rotator cuff reconstruction technique. Using multiple sutures of 0-Polydec on a KHT-3 needle, I believe that we can distribute tension across the tear interface without using bulky sutures. Although this technique has been historically used with a modified deltoid detachment, it can be employed in a “mini-open” technique situation as well. With this technique, a very predictable pain relief, motion recovery, low re-operation rate, and high patient subjective satisfaction can be achieved.

■ REFERENCES

- 1) Mallon WJ. *Ernest Amory Codman. The end result of a life in medicine*. Philadelphia: WB Saunders, 2000.
- 2) Codman EA. *The shoulder: rupture of the supraspinatus tendon and other lesions in or about the subacromial bursa*. Boston: Thomas Todd Co., 1934.
- 3) Matsen FA, Lippitt SB, Sidles JA, et al. Strength. In: Matsen FA III, Lippitt SB, Sidles JA, Harryman DT II, eds. *Practical evaluation and management of the shoulder*. Philadelphia: WB Saunders, 1994:111–50.
- 4) Bigliani LU, Morrison DS, April EW. The morphology of the acromion and rotator cuff impingement. *Orthop Trans* 1986;10:288.
- 5) Romeo AA, Hang DW, Bach BR, Jr, et al. Repair of full thickness rotator cuff tears: gender, age and other factors affecting outcome. *Clin Orthop* 1999;367:243–55.
- 6) Gerber C. Integrated scoring systems for the functional assessment of the shoulder. In: Matsen FA, ed. *The shoulder: a balance of mobility and stability*. Rosemont, IL: American Academy of Orthopaedic Surgeons, 1992:545–59.
- 7) Amstutz HC, Sew Hoy AL, Clarke IC. UCLA anatomic total shoulder arthroplasty. *Clin Orthop* 1981;155:7–24.
- 8) Ellman H. Arthroscopic subacromial decompression. *Arthroscopy* 1987;3:173–81.
- 9) Lippitt SB, Harryman DT, Matsen FA. A practical tool for evaluating function: the simple shoulder test. In: Matsen III FA, Fu FH, Hawkins RJ, eds. *The shoulder: a balance of mobility and stability*. Rosemont, IL: American Academy of Orthopaedic Surgeons, 1993:501–18.
- 10) Matsen FA, Ziegler DW, DeBartolo SE. Patient self-assessment of health status and function in glenohumeral degenerative joint disease. *J Shoulder Elbow Surg* 1995; 4:345–51.
- 11) Gartsman GM. Arthroscopic acromioplasty for lesions of the rotator cuff. *J Bone Joint Surg [Am]* 1990;72:169–80.
- 12) Hawkins R, Misamore G, Hobeika P. Surgery for full-thickness rotator-cuff tears. *J Bone Joint Surg [Am]* 1985; 67:1349–55.
- 13) Barrett WP, Franklin JL, Jackins SE, et al. Total shoulder arthroplasty. *J Bone Joint Surg [Am]* 1987;69:865–72.
- 14) Neer CS. Anterior acromioplasty for the chronic impingement syndrome in the shoulders: a preliminary report. *J Bone Joint Surg [Am]* 1972;54:41–50.
- 15) Neer CS. Impingement lesions. *Clin Orthop* 1983;173: 70–7.
- 16) Rowe C, Patel D, Southmayd W. The Bankart procedure. A long-term end-result study. *J Bone Joint Surg [Am]* 1978;60:1–16.
- 17) Ellman H, Hanker G, Bayer M. Repair of the rotator cuff: end-result study of factors influencing reconstruction. *J Bone Joint Surg [Am]* 1986;68:1136–44.
- 18) Iannotti JP. Full-thickness rotator cuff tears: factors affecting surgical outcome. *J Am Acad Orthop Surg* 1994;2: 87–95.
- 19) Wolfgang GL. Surgical repair of tears of the rotator cuff of the shoulder: factors influencing the result. *J Bone Joint Surg [Am]* 1974;56:14–26.