

Case Report

An Unusual Intrinsic Complication of a Patellar Tendon Allograft and Recommendations for Tissue Banking

Dana I. Tarandy, B.S., James S. Williams, Jr., M.D., and Bernard R. Bach, Jr., M.D.

Summary: Complications of patellar-tendon allograft for anterior cruciate ligament (ACL) reconstruction in ACL-deficient patients have focused on disease transmission, strength, survivorship, technique, and processing to decrease antigenicity. Little has been described in regard to intrinsic complications of patellar-tendon allograft. This article discusses our experience with a damaged patellar-tendon allograft that was abnormally long and had a large osseous intratendinous mass. Based on this experience, we make recommendations on evaluating and procuring patellar-tendon allografts that will help orthopaedic surgeons avoid intrinsic patellar-tendon allograft complications. **Key Words:** Allograft—Anterior cruciate ligament—Patellar tendon.

Although the vast majority of the literature on anterior cruciate ligament (ACL) reconstruction using patellar-tendon allografts describes disease transmission,¹⁻⁴ strength,⁵⁻¹⁰ survivorship,^{6,9,11} technique,^{6,11-14} and processing to decrease antigenicity,^{6,9,15-17} few intrinsic complications of the allograft have been described. This article presents the case of a 25-year-old man whose patellar-tendon allograft was suboptimal. Based on the intrinsic graft problems encountered in this case, recommendations are included in regard to evaluation and procurement of patellar tendon allografts.

CASE REPORT

In 1989, a 20-year-old white man sustained a twisting injury of his left knee while playing basketball. The patient noted immediate onset of knee swelling.

From the Department of Orthopaedic Surgery, Rush-Presbyterian-St. Luke's Medical Center, Chicago, Illinois, U.S.A.

Address correspondence and reprint requests to Bernard R. Bach, Jr., M.D., Department of Orthopedic Surgery, Rush-Presbyterian-St. Luke's Medical Center, 1725 W. Harrison St., Suite 1063, Chicago, IL 60612, U.S.A.

© 1995 by the Arthroscopy Association of North America
0749-8063/95/1104-1292\$3.00/0

He subsequently underwent arthroscopic surgery at another institution where a partial medial meniscectomy was performed for a bucket handle tear and his torn ACL was debrided. Initially, the patient was content with activity modification; however, a job opportunity requiring a stable knee resulted in his approaching us for ACL reconstruction.

Pertinent positive physical examination findings included a grade III Lachman with soft endpoint and grade III pivot shift. A KT-1000 examination was performed that revealed anterior translational measurements on the right knee of 2, 3, and 4 mm, while the left knee revealed 5, 6, and 15 mm at 15 lb, 20 lb, and maximum manual testing. Roentgenograms were normal.

After extensive discussion regarding the advantages and disadvantages of autograft versus allograft patellar-tendon ACL reconstruction, the patient chose an allograft.

The procedure performed was an arthroscopic ACL reconstruction using a single incision technique described by Hardin et al.¹³ The patellar-tendon allograft was received from ROBI (Regional Organ Bank of Illinois). Information regarding the donor states that the graft was obtained from a 43-year-old white man who was 5'8" tall and weighed 183 lb with no signifi-

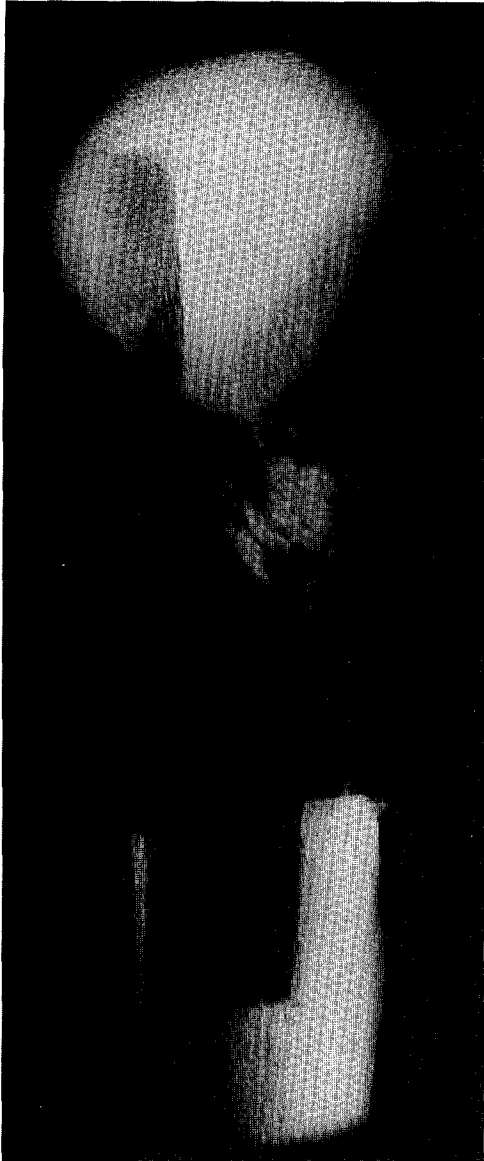


FIG 1. Radiograph of heterotopic bone within allograft.

cant past medical history. The fresh bone-tendon-bone allograft was frozen to alter the immunogenicity of the graft.^{6,15} On removing and thawing the graft from the sterile pack, simple visual inspection and palpation determined the graft to be unusual (Fig 1). Several fibers from the tendo-osseous junction of the tibial tubercle of the graft were noted to have been violated during procurement. With palpation of the graft, a 1.5 × 2 cm, hard, well-circumscribed mass was felt within the tendon itself, just distal to the inferior pole of the patella. Because the construct was to be a middle-third bone-patellar-tendon-bone construct, for the reasons mentioned above, it was deemed suboptimal and a lat-

eral-third bone-patellar-tendon-bone allograft construct was procured. This construct was unusually long, measuring 110 mm and the tendon was especially long at 60 mm (normal tendon length is 45 ± 3 mm). Fortunately, we were able to use it secondary to the large size of the patient (6'7" and 245 lb). The remainder of the procedure was unremarkable. A specimen radiograph of the remaining allograft was taken (Fig 2).

Postoperatively, the patient did well and was discharged on an outpatient basis. At 3 months postoperatively, the patient has a stable knee with normal motion.

DISCUSSION

The majority of the literature regarding patellar-tendon allografts has been directed towards disease trans-

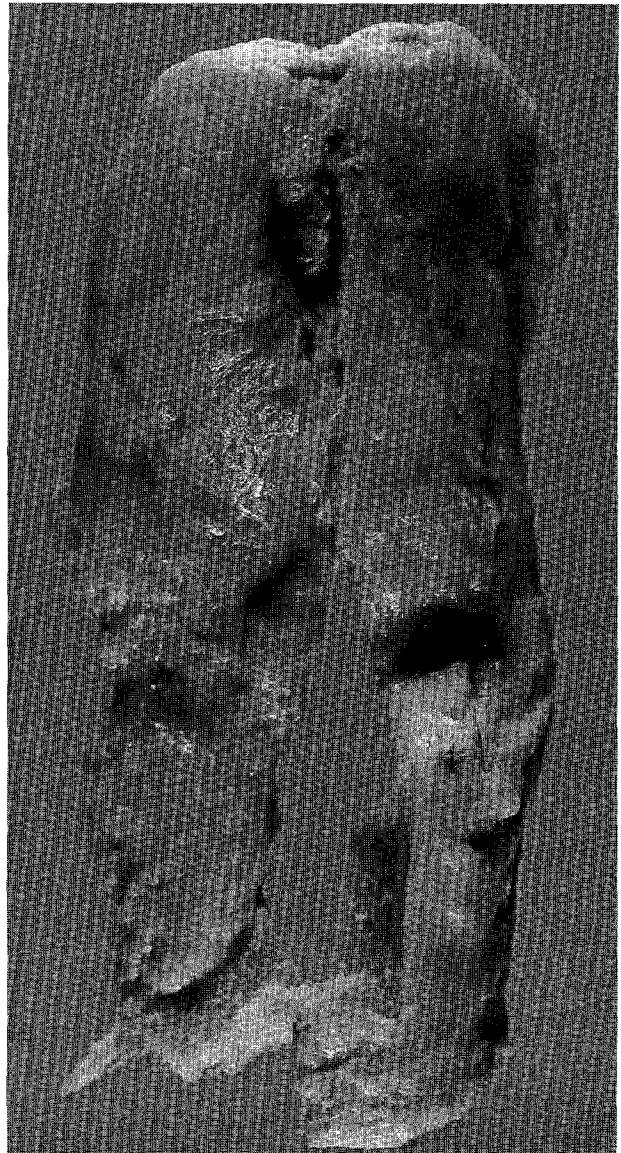

FIG 2. Gross appearance of allograft.

mission, strength, survivorship, techniques, and processing to decrease the antigenicity. The purpose of this article is to point out potential intrinsic allograft complications and to make recommendations on procuring and evaluating patellar-tendon allografts that will help tissue banks guarantee surgeons and patients quality product.

The allograft in this case had numerous intrinsic problems. First, despite having to procure a lateral-third bone-patellar-tendon-bone construct because of the previously mentioned irregularities, the overall length of the construct continued to be greater than usual. (We theorize the donor patient had unrecognized patella alta.) The entire construct was 110 mm in length (normal, 95 ± 5 mm) and the tendon itself was unusually long at 60 mm (normal, 45 ± 3 mm). Fortunately, the unusually large size of the patient undergoing reconstruction allowed accommodation of the graft. Had this been a smaller patient, a graft-host construct mismatch may have precluded reconstruction.

Second, it was noted that several fibers from the tendo-osseous junction of the tibial tubercle of the graft had been violated. This undoubtedly occurred at the time of procurement and rendered the middle-third graft more susceptible to failure; fortunately, the lateral third insertion was uninvolved.

Finally, with respect to the heterotopic mass distal to the inferior pole of the patella and within the middle third of the patellar-tendon allograft itself, pathology reports it to be a 1.5×2.0 cm well-circumscribed area of calcification. Hypotheses regarding the origin of this mass include Sinding-Larsen-Johansson syndrome, steroid injection-induced calcification, or partial tendon rupture that organized.

As a result of this case, we recommend that organ banks institute the following standards: (1) Meticulous procurement of the graft to avoid any violations of the fibers of the tendon. (2) A tibial tubercle bone plug to measure a minimum of 3.75 cm in length. (3) All grafts should be palpated and examined closely for any abnormalities. (4) Radiographic examination of each graft to look for intratendinous calcification. (5) Measurement of graft length (distal patellar pole to tendo-osseous insertion site). (6) Measurement of tendon width at its narrowest portion distally. (7) The radiographs and measurements accompany the graft to aid the surgeon in preoperative planning.

Allograft and tissue banks continue to have an ever

increasing role in orthopaedic surgery. As new uses for allografts evolve, standards in regard to procuring and evaluating these tissues must also evolve. We believe the above recommendations will help optimize biological potential and predictable biomechanical properties for the intended clinical application.

REFERENCES

1. Aaron AD, Wiedel JD. Allograft use in orthopedic surgery—A review. *Orthopedics* 1994;17:41-48.
2. Buck BE, Malinin TI, Brown MD. Bone transplantation and human immunodeficiency virus. An estimate of risk of acquired immunodeficiency syndrome. *Clin Orthop* 1989;240:129-136.
3. Simon TM, Jackson DW. Anterior cruciate ligament allografts. In: Jackson DW, Drez D Jr, eds. *The anterior cruciate deficient knee*. St. Louis: Mosby, 1987;211-225.
4. Tomford WW, Thongphasuk J, Mankin HJ, Ferraro MJ. Frozen musculoskeletal allografts. *J Bone Joint Surg Am* 1990;72:1137-1143.
5. Jackson DW, Grood ES, Arnoczky SP, Butler DL, Simon TM. Cruciate reconstruction using freeze dried ACL allograft and a ligament augmentation device (LAD): An experimental study in a goat model. *Am J Sports Med* 1987;15:528-538.
6. Nikolaou PK, Seaber AV, Glisson RR, Ribbeck BM, Bassett FH. ACL allograft transplantation: Long term function, histology, revascularization, and operative technique. *Am J Sports Med* 1986;14:348-360.
7. Noyes F, Barber SD, Mangine RE. Bone-patellar ligament-bone and fascia lata allografts for reconstruction of the ACL. *J Bone Joint Surg Am* 1990;72:1125-1136.
8. Noyes F, Butler DL, Paulos LE, Grood ES. Intraarticular cruciate reconstruction. I. Perspective on graft strength, vascularization, and immediate motion after replacement. *Clin Orthop Rel Res* 1993;172:71-77.
9. Shino K. Allografts in knee ligament reconstruction. In: Feagin JA Jr, ed. *The cruciate ligaments*. New York: Churchill Livingstone, 1994;623-628.
10. Shino K, Kawasaki T, Hirose H, Ippai G, Inoue M, Onu K. Replacement of the ACL by an allogenic tendon graft. *J Bone Joint Surg Br* 1984;66:672-681.
11. Shino K, Inoue M, Horibe S, Nagano J, Ono K. Reconstruction of the ACL using allogenic tendon: Long term follow-up. *Am J Sports Med* 1990;15:457-465.
12. Bach BR Jr. Arthroscopy-assisted patellar tendon substitution for ACL insufficiency. *Am J Knee Surg* 1989;2:3-20.
13. Hardin GT, Bach BR Jr, Bush-Joseph CA, Farr J. Endoscopic single-incision ACL reconstruction using patellar tendon autograft: Surgical technique. *Am J Knee Surg* 1992;5:144-155.
14. Wainer RA, Clark TJ, Poehlen GG. Arthroscopic reconstruction of the ACL using allograft tendon. *Arthroscopy* 1988;4:199-205.
15. Arnoczky SP, Warren RF, Ashlock MA. Replacement of the ACL using patellar tendon allograft: An experimental study. *J Bone Joint Surg Am* 1986;68:376-385.
16. Indelicato PA, Bittar ES, Prevot TJ, et al. Clinical examination of freeze-dried and fresh-frozen patellar tendon allografts for ACL reconstruction of the knee. *Am J Sports Med* 1990;18:335-342.
17. Pinkowski JL, Reiman PR, Chen SL. Human lymphocyte reaction to freeze-dried allograft and xenograft ligamentous tissue. *Am J Sports Med* 1989;17:595-600.